BACTERIOLOGY OF THE EYE

AXENFELD—MACNAB

00013734

THE
ASIATIC SOCIETY OF BOMBAY
Town Hall, Bombay.

Digitized with financial assistance from

on 10 July, 2018

RATNA PRABHA VIJAY.
AHMEDABAD.

RATNA PRABHA VIJAY.

THE BACTERIOLOGY OF THE EYE

THE BACTERIOLOGY OF THE EYE

BY

DR. THEODOR AXENFELD

PROFESSOR OF OPHTHALMOLOGY IN THE UNIVERSITY OF FREIBURG

TRANSLATED BY

ANGUS MACNAB, B.A., B.Sc., M.B., CH.B., F.R.C.S.

CHIEF CLINICAL ASSISTANT, ROYAL LONDON OPHTHALMIC HOSPITAL

WITH 87 ILLUSTRATIONS, SOME OF WHICH ARE COLOURED AND 3 COLOURED PLATES



LONDON

BAILLIÈRE, TINDALL AND COX

8, HENRIETTA STREET, COVENT GARDEN

1908

[*All rights reserved*]

THE ASIATIC SOCIETY OF BOMBAY
LIBRARY

616·07581:617·7
Axe/Bae
13734

24 JUN. 1962

00013734

MUNI RATNA PRABHA VIJAY.
No.....
AHMEDABAD.

SEINEM LIEBEN KOLLEGEN

HERRN DR. V. MORAX,

OPHTHALMOLOGISTE DES HÔPITAUX IN PARIS

FREUNDSCHAFTLICHST GEWIDMET

VOM VERFASSER.

TRANSLATOR'S PREFACE

SINCE this work appeared in German in 1907 certain parts of the text have been extended by Professor Axenfeld, and the references to a number of later publications included. Although the whole of the literature for 1907 has not been analyzed and included in the lists, all the recent work of importance, or which modifies in any way views previously held, has been incorporated in the text. The aim of the translator has been to keep as close to the original as possible; the carrying out of this aim has been facilitated by the kindness of the author in looking over the proofs.

The nomenclature used throughout is that authorized by the College of Physicians of London, and where that standard failed—for example, in the name of an organism—the name used by the first writer on the subject has been used in all cases where that could be determined.

The greatest care has been exercised to have the references exact. Regarding many foreign names of persons, it will be noted that the German spelling of Russian and other words has been followed. This is done because most of their work has been published or reviewed in that language.

The importance of the subject, and the difficulty encountered by students in being driven to the original literature for every reference, together with the intrinsic merit of the work, are the reasons why it has been translated into English.

ANGUS MACNAB.

31, NEW CAVENDISH STREET,
August, 1908.

CHAPTER IX

LEPROSY, TUBERCULOSIS, AND SYPHILIS OF THE EYES - - PAGE 341

CHAPTER X

ENDOGENOUS INFECTIONS - - - - - - 360

CHAPTER XI

THE ORBIT - - - - - - - - - 385

INDEX - - - - - - - - - - 393

INTRODUCTION

When the large 'Handbook of the Pathogenic Micro-organisms' was issued in 1903 by Kolle and Wassermann, it was my intention to enlarge and bring out in book form the material which I contributed to it. Other work has been given precedence, but in view of the oft-repeated request that I should carry out my intention, I cannot put it off any longer.

In that Handbook, which was especially written for bacteriologists, the pathogenic organisms in ophthalmology were only discussed in so far as they showed special peculiarities. In this work, which is not only written for the bacteriologist, but also for the ophthalmic surgeon, a wider view is taken of the subject.

For the common organisms also the necessary biological descriptions are given shortly, and a table at the end, in the style of Lehmann and Neumann, makes the comparison and diagnosis by culture easy.

Several new chapters appear: 'The Normal Conjunctiva'; 'The Bacteriological Basis of our Asepsis, and of Wound Infection'; 'Diseases of the Lids'; 'The Orbit'; 'Endogenous Infection of the Eye.' Syphilis, leprosy, and tubercle are also discussed. The other chapters are an extended revision of what appeared in the Handbook. For convenience, especially in teaching, I have added special instructions in the technique of the examination and diagnosis of cases coming within scope of this work.

Naturally no complete statement of general bacteriological principles will be undertaken. Every modern medical man has had the opportunity of becoming acquainted with the elementary facts regarding the bacteria, and the means by which their study is carried out, and the textbooks of hygiene and bacteriology can be consulted for any special points. Nor does a complete statement of the question of immunity come into the range of this volume, though it has been taken into consideration in the study of the infectious eye diseases, their diagnosis and treatment.

A distinction must be drawn between those who are students of scientific bacteriological problems, and who must be expert bacteriologists, and the larger number who, without having acquired such bacteriological skill, still wish to become familiar with this important subject of etiology, and also to make use of the ascertained facts to decide clinical, statistical, and therapeutical questions, as well as those who desire to examine clinically the exudations in their cases. Here a wide and profitable field is open.

In the last-mentioned class the best results are got by those who examine the most cases; these people often obtain useful information. The busy practitioner who considers that he has not time for such examinations in his consulting-rooms will still require bacteriological assistance in cases of severe epidemics, inflammations, and corneal suppurations, and as a preliminary to many operations. While those who wish to make use of serum and other allied forms of treatment cannot do without examinations of the body fluids; and even though the methods are in their infancy, in some instances valuable results have been obtained.

Although the laboratories throughout the country for the diagnosis of diphtheria can be used by the ophthalmic surgeon for many other diagnoses, much will remain to be done by the surgeon who is in even these favoured circumstances.

Even in the absence of trained assistance one can be greatly assisted in the examination of pathological secretions and exudates if the fixation, Gram staining and mounting, be done by a nurse or other person; they rapidly learn the manipulation necessary, and then the surgeon need only undertake the collection of the material and its microscopical examination, and this certainly does not take much time. Those who do not even have this amount of assistance can at any rate rub the material on to a slide and examine the specimen later.

I am becoming more and more convinced that those surgeons who will themselves make use of the Gram method of staining in the examination of a smear preparation will soon give up their sceptical and doubting attitude. As bacteriological apparatus is to be found in every modern ophthalmic hospital, we can expect that in the future every young oculist will find opportunity during his time as assistant for the necessary work. Such men will never dispense with clinical bacteriology, for it is the aim and the pride of the modern surgeon to determine the origin of the disease with which he has to deal, and to use every possible care in his treatment. Even those whose

student days belong to the more distant past can at least learn to make a simple smear preparation and find it useful.

While for the scientific student it would be desirable to record every detail which the literature affords, for the practitioner a shorter textbook seems perhaps to be sufficient. I am of the opinion that these two points of view should not be separated. The practical points can be emphasized, and I hope that by the plates, the illustrations from secretions, and the introductory remarks to the sections, as well as by the special chapters on the secretion-findings, this book may serve to put a due value on clinical bacteriological differential diagnosis. If our diagnosis is not to be merely schematic, it must closely follow scientific thought. I hope also that the simple examination of the secretions may induce many to go more fully into the subject, and that in the future surgeons during their student days will pay more attention to these questions.

In the ophthalmological literature there has till now been no book through which the ophthalmic surgeon can post himself up in this subject.[1]

Bacteriological questions begin to be more or less thoroughly discussed in the ophthalmological textbooks. The subject of Conjunctival Diseases in the second edition of Saemisch's 'Handbuch der gesamten Augenheilkunde,' and also the article by Morax in the 'Encyclopédie française d'Ophthalmologie,' published some years ago, fully consider the bacteriology of conjunctival diseases. All these accounts, however, require to be collected and extended. On the other hand, the bacteriological textbooks treat these interesting questions either very shortly or not at all, particularly as the very comprehensive ophthalmological literature is only to a very small extent at their disposal.

I have laid especial importance on the illustrations, and in this I am gratefully indebted to the support of my assistants, Drs. Stock, Agricola, Brons, Rupprecht, and especially to the publishing house of Gustave Fisher. Mr. Johnsen, an artist of great experience in this kind of work, has produced the coloured plates, which are all of the same magnification, and stained exclusively by Gram's method, representing the important findings absolutely true to nature. For this purpose I have only used preparations made from ophthalmic cases; for it would not be advisable in the case of the *Pneumococcus*, for

[1] 'Ophthalmologie Microbienne,' Gabriélidès (Constantinople, 1906), appeared when this book was ready for the press. It contains the ophthalmo-bacteriological literature, mostly from French reviews, but it hardly contains any illustrations, and is arranged in quite another manner.

example, to have a drawing made from a pneumonic sputum, as in the latter the appearance can be different from that of the conjunctival secretion.

For diagnosis I consider that coloured plates are better than micro-photographs. Though the latter are very valuable—yet even with the best technique many fine details do not appear so distinct as to make the picture absolutely clear—I need merely refer to the fact, for example, that we hardly possess an absolutely good photograph of a secretion preparation containing Koch-Weeks bacilli.[1] Either from over-exposure, or from over-staining (to make them more obvious), the bacilli are too thick, and many of the finest rods are not represented. It is also a great advantage to represent the contrast of the Gram stain, and to emphasize from the first the reaction of the bacteria to this diagnostic method which is the most useful in everyday work. In other ways I do not undervalue micro-photography, as is seen from the text of this book.

I have attempted to describe the organisms which are exclusively or principally pathogenic for the eye as fully as the available material would allow; and with regard to the others, while I have emphasized all ophthalmic work in the general bacteriological literature, I have only done so with regard to the most important. Those who would study the latter fully must naturally make use of the bacteriological text and handbooks.

The subdivision of the material presented some difficulty. Anyone who inquires into ophthalmic bacteriology, or would like to determine the importance to be ascribed to any finding, will wish to ascertain not only where and with what results the bacterium is to be found in ophthalmology, but also to observe the clinical appearances, and decide what is the cause of infection in the particular case.

The easiest way would have been to have gone through the whole material twice, once according to the bacteria, and again according to the clinical appearaces. This would, however, make the field too wide, and cause numerous repetitions.

Under these circumstances I have chosen a clinical division, for I thought that a purely bacteriological one would have been more difficult, and would have been less likely to arouse the interest and co-operation of ophthalmic surgeons. I have not held rigidly to this principle, for just as the clinical picture sometimes is the most important, so sometimes the one point of view, and sometimes the

[1] The best which I know of are by Heim.

other, is to be preferred for the purposes of description. Many subdivisions are therefore made according to the organisms present, as, for example, that of the conjunctival infections.

The bacteriological view of the other sections is retained by Dr. Ruprecht's carefully-arranged index, showing the occurrence of the organisms in their various positions, and by the cross-references in the individual chapters to the other localities.

An account of the biology of the most important bacteria in this book is given where they first come under our notice, or in the place which is most important for the individual bacterium. The tables at the end also assist in the determination of the findings.

I hope that the order taken is valid; a purely bacteriological point of view is undesirable in clinical use; we must make the bacteriological amplify clinical experience.

In this I have been guided by my teaching experience. These principles have been used in the courses of ophthalmo-bacteriology which have been held from time to time in the Freiburg Hospital.

May this book spread in ever wider circles the view that bacteriological examination is not merely scientifically useful, but is necessary for our daily clinical use. *Those who do not freely examine for bacteria in their practice will not assist their patients in many of the ways which are possible.*

TH. AXENFELD.

FRIEBURG I. BR.,
January, 1908

ERRATA

Page 62, line 2, *for* ' sclerosis,' *read* ' B. xerosis.'
Pages 90 and 91, *for the word* ' stems,' *read* ' strains.'
Page 124, line 32, *for* ' improved,' *read* ' unproved.'
Page 126, line 12, *for* ' conjunctiva,' *read* ' cornea.'
Page 170, third line from foot, *delete* ' cannot.'

BACTERIOLOGY OF THE EYE

CHAPTER I

REMARKS ON TECHNIQUE

The Technique of Examining Cases.

It is possible to acquire all the important facts in ophthalmic bacteriology with the aid of but simple apparatus. The mere examination of a film gives a great deal of information, and for the preparation and examination of cultures all that is necessary is the well-known bacteriological apparatus as arranged by Lautenschläger, Rohrbeck, and others. This is quite sufficient if no special scientific research is to be made.

We must assume a fair amount of general knowledge, but there are several practical points which must also be emphasized.

The Collection and Preparation of Material.

It is absolutely necessary, in dealing with both external and internal diseases, that material should be collected at a suitable stage of the disease.

1. The Conjunctiva.

In many forms of conjunctivitis (*e.g.*, pneumococcal) the characteristic findings in the secretion can only be obtained during that period in which the disease is developing, or is at its height. When that point has passed, and the inflammation begins to subside, although the discharge may still be profuse, the actual causal agent can disappear rapidly, but the discharge lessens more slowly. In the stage of regression we find the common conjunctival inhabitants, especially *Staphylococci* and *Xerosis bacilli*, in much larger numbers. These previously were often completely—or, at least, to a considerable extent—choked out by some particular pathogenic organism. This is true

when dealing with a single case, and also when an epidemic is being considered. In the latter instance, therefore, those cases should always be examined which have not yet passed the height of the inflammation.

The discharge should be taken from the conjunctival surface, avoiding contamination as far as possible, and it should be collected before it has come in contact with the angles or margins of the lids. In many instances a pure culture will thus be obtained, and the causal organism alone will be seen in the smears. If, however, any contamination with the lids or skin should occur, the preparation will show a more or less free admixture of skin organisms, especially *Staphylococci* and *Xerosis*. When, as often happens, the discharge is so scanty that it cannot be thus obtained from the conjunctiva, we must use that which collects at the inner angle for our preparations. Such is often the case in slight cases of diplobacillary conjunctivitis. The preponderance of the true pathogenic organism over the others will still be quite marked. If we wish to make cultures in such cases, it is better not to use the secretion at the angles, but to pass the loop to and fro in the moist lower fornix; some organisms will thus be collected, generally in sufficient numbers for culture purposes.

To make a microscope slide a small flocculent mass of the secretion is obtained, as free as possible from tears; this is then rubbed with the platinum loop on a carefully cleaned slide, so as to form an even, thin layer. It is especially necessary that the layer should be thin and even, for with Gram's staining the same organism may show positive or negative, according to the thickness of the tissue and the varying protection thus afforded it against the decolorizer.

Under the heading 'Conjunctivitis' this subject is fully treated.

2. The Cornea.

To avoid injury to the tissues the *greatest care must be exercised* in obtaining material from corneal infiltrates or ulcers. The eye must be cocained and kept perfectly still, either by fixation through the lids with the fingers, or by forceps and speculum.

The secretion is carefully wiped away from the cornea with a sterile swab, and some of it kept for examination. We must not, however, put too much reliance on the examination of this secretion, for the true exciter of a corneal process is frequently not found on the surface, but lies deeply placed in the infiltrated corneal tissue; for example, in cases of diplobacillary conjunctivitis the cornea may be infected by *Pneumococci* (Hoffmann, Zur Nedden). This explains why

many earlier writers often failed to find the cause of hypopyon-keratitis and ulcus serpens.

It is important in deciding the diagnosis to obtain material from the actual infiltrated tissue. This must be done with the greatest of caution, as the scraping can loosen the tissues and result in a further spread of the infection. In deeply-placed infiltrates this examination should not be insisted upon, especially when the lesion is central. A movement of the patient's eye may cause the point of the instrument which is in contact with the infected focus to penetrate and infect the cornea more deeply. I can remember several cases which have thus been made worse; and it is a rule in my clinic that, immediately after the bacteriological examination has been made, the requisite treatment should at once be applied (*e.g.*, in diplobacillary cases zinc freely, in pneumococcal cases the cautery, etc.). This is naturally most important in purulent processes.

The point of a sterile Graefe knife or needle carefully used is very suitable for removing the material. The cocained eye must be absolutely steady. For this purpose the speculum and forceps are often necessary, and have the added advantage of preventing contamination by the lid margins. In the case of ulcus serpens we must go carefully along the progressive margin. For this purpose Römer uses a platinum needle. A small amount of material is obtained, and from it a culture should first be made, and then the rest rubbed out on a slide. If nothing can be found in the film, some more material must be taken. Cultures are often the more delicate test, especially when the organisms are experimentally increased, as, for instance, *Pneumococci* in glycerine and rabbit-serum bouillon (Römer). In every case well-tried and susceptible media must be used for all corneal work.

In many cases an examination of a Gram-stained preparation settles the question at once; this is especially the case in deciding between diplobacillary and pneumococcal infections of the cornea—a most important diagnosis and one which is almost always thus decided. Sometimes we find cases where the slide preparation gives a positive result, but cultures are negative; this is probably due to the scanty numbers of the organisms.

This bacteriological examination is especially desirous in purulent affections of the cornea; it is also valuable in many simple infiltrates, and can be recommended in every stubborn case. Peripherally situated infiltrations will be more readily tested thus, as the pupillary area of the cornea should not be interfered with unless absolutely necessary.

Amongst the peripheral catarrhal infiltrates and ulcers many diplobacillary cases will be found, for which the zinc treatment far surpasses all others.

Intra-ocular Diseases.

Fluids taken from the anterior chamber by puncture or with a fine syringe can be similarly examined on a slide. In the case of purulent processes the actual cause may be demonstrated at once; but it should be remembered that just as a sterile hypopyon can result from an infection of the cornea, so it can result from the influence of a distant focus deep in the eye. In many cases of perforating wounds I have found the hypopyon sterile and the vitreous infected. In this connexion it must be noted that the organism may have disappeared from the anterior chamber, and still remain in the more nutrient vitreous.

When the eye is available after an exenteration or enucleation, material can be taken from several places, naturally with as little damage as possible to the specimen. The surface of the globe at the point of perforation should first be cauterized, to prevent any contamination with germs which may be adhering to it.

In iritis a diagnostic puncture of the living eye has lately been recommended by Gourfein,[1] Morax and Chaillous,[2] and Zur Nedden.[3] For this purpose the cornea is punctured obliquely with a cannula attached to a syringe, and the fluid which runs into the syringe is examined. In the case of acute iritis a slide should be prepared and stained in the method introduced by Giemsa to demonstrate the *Spirochæta*. In dealing with chronic iritis the important question arises, Is the case one of tuberculosis? and it is better to make inoculations with the aqueous obtained. Gourfein and Morax have thus inoculated tuberculosis in rabbits. Of course a negative result in such a case is of little value, as the organisms can remain in the iris, and not pass out into the aqueous.

As in other exudations, the causal germs in an intra-ocular suppuration may die out after a varying time, which depends on the particular species of organism present (pathogenic *B. subtilis* dies rapidly; other pyogenic organisms resist longer), on their number and virulence, and also on the method and site of their implantation (direct vitreous infection, with a simultaneous wound of the lens, favours their spread and persistence, while a pure infection of the aqueous, and many hæmatogenous infections readily disappear). The resistance and

[1] *Recueil d'Ophth.*, 1904, p. 434. [2] *Ann. d'Ocul.*, 1901, cxxvi., p. 119.
[3] *Vers. der Deutschen. Ophth. Ges.*, Heidel., 1906.

immunity, both of the organism generally and the particular tissue affected, have also an influence. Each of these circumstances can modify the clinical progress of the disease, and also the inoculation results. We must therefore be very careful on obtaining a negative result not to commit the common error of rashly concluding that the case is not a septic process, but a pure case of 'toxic inflammation' or a 'toxic metastasis.'

Inoculations should not generally be made from the interior of the living eye, as the introduction of an instrument is too risky. In deep wound infections, therefore, an etiological diagnosis can only exceptionally be made *intra vitam oculi*. Opportunity for inoculation is most usually given when a foreign body is removed; the foreign body should then be rubbed on agar, or introduced into bouillon. Enucleated eyes or exenterated contents, on the other hand, are very often available for examination.

Tough or compact material (concrements from the canaliculi, or the contents of follicles, etc.) can be squeezed out with a sterile glass rod, or teased out in saline with sterile needles; this is absolutely necessary when such material is to be used for direct injection into any test animal. Morax uses a method of treating trachoma follicles by rubbing them down with sand before inoculating them on to the medium.

Staining Methods.

The material is spread out on a slide, dried in the air, and then passed three times through a flame to fix it. In the case of bouillon cultures the drying process must be carefully attended to, for when a damp preparation is drawn through the flame the bacteria in it may be very distorted. It is sometimes useful to fix by alcohol or sublimate, in which the air-dried film is laid for about ten minutes; in the case of sublimate the preparation must be passed through an alcoholic solution of iodine, and then ordinary alcohol before staining.

When stained the preparation can be examined in water under a cover-glass. Many details are thus shown more clearly than when it is in balsam; single individuals appear larger, and the features of very small organisms, such as Koch-Weeks and influenza, are more readily seen. Such preparations can again be dried and mounted in balsam.

For a simple aniline stain Löffler's methylene blue (Löffler's universal method), and dilute carbol fuchsin can be recommended.

Löffler's Methylene Blue.—To 100 c.cm. water containing 1 c.cm. of a 1 per cent. solution of caustic potash, add 30 c.cm. saturated solution of methylene blue. The solution and the stain are comparatively permanent, and have the advantage of not overstaining and usually showing up details in cells and bacteria. The granules in *B. diphtheriæ* and polar bodies are also well shown. Preparations should be stained for one-half to two minutes. (This stain is less suitable for microphotography than fuchsin.)

Fuchsin.—To 10 c.cm. distilled water add 10 to 20 drops of Ziehl's[1] carbol fuchsin; stain from a few seconds to one minute. If stained intensely differentiate by weak acetic acid, and then freely wash with water.

A method which can be thoroughly recommended is to make such a simple stained preparation along with a Gram-stained one; the former can then be examined in water (add 1 drop, and then cover; soak up the surplus so that the cover-glass does not float). Details, especially capsules, are thus made very evident; and if it is desired to mount the preparation permanently, add a little water to remove the cover, then dry and mount in balsam.

Many mixtures of dyes and double stains can be recommended for contrast staining of cell bodies and bacteria, especially when looking for *Gonococci*.

We can mention the Pick-Jacobsen method:

Methylene blue (sat. alcohol sol.)	...	...	8 drops
Carbol fuchsin	...	...	15 „
Aq. dist.	...	...	20 c.cm.

This stains bacteria *dark blue*, cell nuclei *light blue*, protoplasm and mucin *red*. C. Fränkel recommends 45 to 50 drops of carbol fuchsin instead of 15, and stains for five minutes, when the nuclei also stain *red*, and only the bacteria appear *dark blue*. This modification of Fränkel gives beautiful preparations.

Nicolle's thionin stain is rightly recommended by Morax for organisms which stain badly, especially the Koch-Weeks bacillus; it consists in staining for one-half to one minute in

Thionin, sat. sol. in 50 per cent. alcohol	...	...	10 parts
1 per cent. watery sol. of carbolic acid	...	...	100 „

The nuclei stain *blue*, the bacteria *reddish*. The contrast is good and permanent.

Besides these simple and mixed aniline stains there is **Gram's stain.** This is the most useful of all, and for clinical diagnosis is by far the most important, for it gives at once a large number of differential diagnoses. By using a suitable contrast stain the Gram-negative organisms and the other histological elements can be readily defined. I will therefore consider this method more fully.

The technique which I have used for years is that described by Jadassohn:

[1] Fuchsin, 1; absolute alcohol, 10; phenol, 5; distilled water, 100.

After fixation of the smear—

1. Stain for twenty-five seconds in the following solution:

5 per cent. watery sol. of gentian violet[1]	88 parts
Ol. anilin pur.	2 „
Abs. alcohol	10 „

Filter before using.

2. Wash with water.
3. Iodine in pot. iodide solution (1 : 2 : 300) fifteen seconds; the preparation must take on a dark brown tint. Then, without washing,
4. decolorize with absolute alcohol till no colour washes out.
5. Wash in water.
6. Counter-stain with 5 per cent. watery safranin or weak fuchsin for five seconds.
7. Thoroughly wash with water, dry, and examine in water, oil, or Canada-balsam.[2]

When this method is carried out exactly, films are obtained quite free from granular debris of the stain, and the modifications suggested by Unna and others to prevent such contamination, and to procure a clean decolorization, are quite unnecessary, and can be neglected.[3] Clear colour contrasts can always be obtained. The Gram-positive bacteria stain dark blue; the Gram-negative bacteria, the cells, exudate, and other tissues, take up the contrast stain and are red.

FIG. 1.—SECRETION CONTAINING INFLUENZA BACILLI (RED) AND XEROSIS BACILLUS (BLUE). GRAM STAIN. (× 1,000.)

[1] Löffler (*Deutsche Med. Woch.*, 1906, p. 1244) states that methyl violet 6B or BN, dissolved in 1 to 2½ per cent. carbolic in a proportion of 1 : 10, gives better results.

[2] Another commonly-used modification is the Gram stain according to Czaplewski:

1. One minute in carbol gentian (sat. alcoholic sol. of gentian violet, 50 c.cm.; 5 per cent. carbolic ac. watery sol., 50 c.cm.; aq. dist., 50 c.cm.).
2. Wash.
3. Thirty to sixty seconds in Lugol's solution (iod., 1; pot. iod., 2; aq., 300).
4. Wash; dry with filter-paper.
5. Differentiate in anilin xylol (2 : 1 + 1·5 per cent. acetone).
6. Wash in xylol; dry in air.
7. Counter-stain for one minute in carbol-glycerin-fuchsin (1 fuchsin triturated with 5 of ac. carbol. liq., 50 glycerin, and 100 c.cm. aq. dist.).
8. Wash and dry.

Should differentiation be difficult, carefully add 1 drop of alcohol to the anilin xylol. 'Fibrin and richly nucleated structures are more easily differentiated if the material be spread on the slide with water.'

[3] The original Gram prescription for the watery anilin-gentian-violet (add drops of sat. solution of gentian violet in alcohol to anilin water until a coloured scum occurs) does not stain deeply enough, and gives a slight deposit. Gram's original prescription can no longer be recommended.

There are a few details requiring attention if good Gram preparations are to be obtained:

(*a*) The discharge must be spread out on a perfectly clean slide in as thin and uniform a layer as possible. When the thickness of the film varies, those parts should be examined which are uniformly thin. At places where the material is heaped up on the slide the reagents do not penetrate, and organisms which really are Gram-positive (*e.g.*, *Xerosis*) may appear Gram-negative, being stained by the contrast dye. At such places positive and negative individuals of the same species may lie one over the other. At other times in a clump of discharge a Gram-negative organism may appear blue where the decolorizing alcohol has not been able to penetrate.

(*b*) The whole film should be rapidly covered with the stain.

(*c*) Do not overdo the iodine.

(*d*) Thoroughly wash away the alcohol with water.

(*e*) Avoid overstaining with the contrast dye, excess of which must be thoroughly washed away. Acid-safranin and fuchsin spoil the blue gentian colour; and we often notice after several weeks that the blue colour has disappeared, and has been replaced by red.[1]

(*f*) The anilin-gentian-violet must be often renewed—best every three to four weeks. Czaplewski's carbol gentian is more stable.

To be absolutely certain when examining a new organism we should place on the slide beside the film some well-known Gram-positive bacterium, such as a fresh culture of *Staphylococcus* or *B. xerosis*. When this standard remains deep blue after the staining, then the solutions are satisfactory, and the less well-marked or negative staining of the other organism is demonstrated.

When bacteria stain but slightly positive ('amphoter'), and the colour is partly reddish or red, a film should be stained without any contrast colour, for in the case of these microbes the violet is perhaps only loosely fixed by the iodine, and is easily overcome by the contract dye.

There are undoubted variations in the action of the Gram stain. Involution forms often do not take it up; *e.g.*, in exudations containing *Subtilis*, individuals are seen which are Gram-negative.

Amongst the negative bacteria the *Gonococcus* most rapidly loses its colour; it is completely decolorized (*i.e.*, shows the contrast stain) when the cell nuclei and the mucin in the film are still blue. None of the other negative organisms give up the colour so rapidly. Diplobacillus, *Bact. coli*, *Bac. Friedländer* are usually not completely decolorized so long as the blue remains in the tissues around. Koch-Weeks bacillus, influenza bacillus, *Meningococcus*, and *Micr. catarrhalis* decolorize rapidly, like the *Gonococcus*. Many authors consider this rapid loss of colour as of value in differential diagnosis,

[1] This occurs, as a rule, in old films, which therefore are unsuitable for demonstration. The balsam can be removed, and the film stained afresh.

and v. Lingelsheim advises that the alcohol should be only used for thirty seconds. It certainly should not be left on too long, for many positive organisms will in time lose their colour. With the original Gram solution, which stained slowly and less intensely, organisms were often called negative which we now know to be positive (see 'Gonococcus'). Only those organisms should be called negative which, after the technique recommended, completely lose their blue colour. The Jadassohn modification gives so intense a stain that the alcohol can be used as long as the colour is obviously being washed out. A good and diagnostic contrast is thus obtained.

The same technique should always be used, and in scientific work, in questions of this kind, it is best to state how the Gram stain was applied.

The organisms of interest in ophthalmology which stain positive are:

Most of the *Sarcinæ;*
Staphylococci, Streptococci, Pneumococci;
Bacilli of the *Diphtheria* and *Subtilis* groups;
Bac. perfringens (Chaillous);
Aspergillus fumigatus, Streptothrix, and *Actinomyces.*

Staining negative are:

Bacilli of Koch-Weeks and Pfeiffer (L. Müller, influenza);
Diplobacillus of Morax-Axenfeld and Petit;
The *Coli* group;
Gonococcus, Meningococcus, Micr. catarrhalis;
Bac. pyocyaneus;
Group of *Friedländer's pneumobacillus.*

Staining of Sections.

For the examination of bacteria in sections hardening in formol is best. Sublimate, too, can be used if it be thoroughly removed afterwards by iodine; Zenker's fluid also, if only used for a short time and then thoroughly washed away. Similarly, Müller's fluid, if for a still shorter time, and still more thoroughly washed away. These latter are not so good.

For sections of the whole eye celloidin embedding is better than paraffin; small pieces of a tissue, however, stain very well after paraffin.

For all Gram-positive organisms (*e.g., Pneumococci* in sections of an ulcus serpens) the most suitable stain is Weigert's modification of Gram, which stains fibrin also.

When the object is not very large, a preliminary staining with lithium carmine or alum carmine can be carried out in the block, and a whole eye can be so stained after cutting off a *calotte*. The stained object is then embedded in paraffin or celloidin. Paraffin sections must be fixed down to the slide (dilute alcohol usually is sufficient to effect this), and can be stained after the paraffin has been dissolved out and the section carried into alcohol. Celloidin sections must be pressed down on the slide. Under no circumstances should sections be placed loose in these solutions, as they will certainly curl up.

The previously mentioned anilin-gentian-violet solution can be used for staining, and the treatment with the iodine (Lugol) solution is the same. After drying up the iodine solution the decolorization must be done as follows: Plunge the slide into anilin xylol (2 : 1), or rapidly pour that fluid over it until no more blue clouds

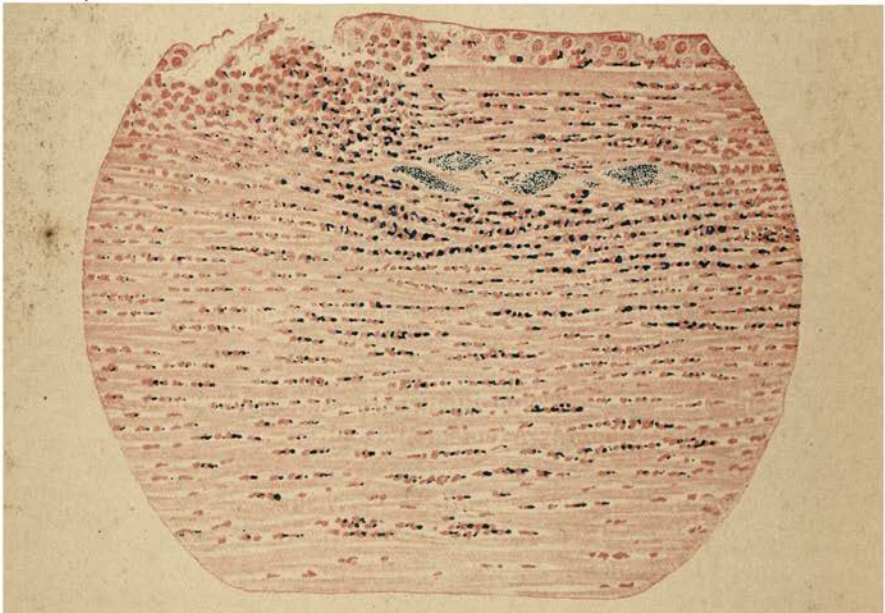

FIG. 2.—PNEUMOCOCCI IN HUMAN CORNEA, PROGRESSIVE BORDER OF ULCER. GRAM-WEIGERT STAIN, PNEUMOCOCCI BLUE.

can be washed out and the former colour returns to the section; dry, wash rapidly with fresh xylol till all the anilin oil is removed (otherwise the staining is only temporary), and mount in balsam.

It must be emphasized that staining in sections does not always succeed so readily as in films. The process must sometimes be varied. For many sections it is better to mix equal parts of anilin water with a saturated solution of gentian violet in alcohol, and to place the section for several seconds in this mixture.

The demonstration of Gram-negative microbes in sections is much more difficult, and sometimes quite impossible. The following methods are comparatively certain. On account of the frequency of Gram-negative organisms in ophthalmology I will give several of

them, so that in individual cases a variety of methods may be available.

1. **Nicolle's Thionin.**—Saturated solution of thionin in 50 per cent. alcohol, 10 parts; 1 per cent. carbolic acid in water, 100 parts. Stain for about one minute; wash with water, alcohol, xylol, balsam.

2. **Pappenheim's Stain.**[1]—Fix sections or films in alcohol or sublimate; embed in paraffin, etc.; stain in a solution of methylene green, 2 pinches (amount on the point of a knife); pyronin, 1 pinch; aq. dist., 5 c.cm. Mix and leave for fourteen days, then filter, and stain for five minutes; differentiate in a dish of absolute alcohol containing 3 pinches of resorcin, then pass through absolute alcohol and xylol.

3. **Polychrome Methylene Blue** (Unna,[2] after E. Fränkel).—After staining the sections for several hours in the polychrome methylene blue, they are differentiated in Unna's tannin-orange mixture, washed in water, and then taken through alcohol and oil into balsam. If the staining has been successful, the nuclei and bacteria are blue, the red blood-corpuscles orange, and the collagen tissues unstained.

4. **Zieler's Stain.**—Fix in Müller's formol; embed in paraffin, or remove celloidin before staining.[3] Stain over-night (eight to twenty-four hours) in Pranter's weak orcein solution (orcein D [Grübler], 1 part; official nitric acid, 2 parts; 70 per cent. alcohol, 100 parts); rapidly wash in 70 per cent. alcohol, then in water. Stain in polychrome methylene blue for ten minutes to two hours; wash in water. Thoroughly differentiate in Grübler's glycerine-ether mixture; wash in distilled water. Take through 70 per cent. alcohol into abs. alcohol, then xylol to balsam. The bacteria are dark blue or blue-black.

5. **E. S. Thomson's**[4] **Carbol Toluidin.**—Equal parts of 1 per cent. toluidin and 1 to 2 per cent. formol in water; stain for fifteen to thirty minutes; decolorize in 95 per cent. alcohol; if this be difficult, add a drop or two of glacial acetic acid, and again pass through 95 per cent. alcohol.

Clear in carbol xylol, origanum oil, and balsam. Good results were often obtained by this method by the introducer.

Both paraffin and celloidin sections often stain well with warm Löffler's methylene blue.[5] The dye is carefully filtered and placed with the section in a closed watch-glass for one to twenty-four hours in the brood oven; it is then poured out into a larger dish with water, and then taken through alcohol. The degree of decolorization, and also the intensity of staining, can only be decided in any particular case by trial. In many cases the sections may be placed in water acidulated with acetic acid, or some of the acid can be added to the alcohol. In other cases this will cause too much loss of colour. A little methylene blue can be sometimes added to the alcohol to prevent too thorough a decolorization. Then carbol xylol and balsam (oil must be avoided, as the sections bleach in it, or if used, some methylene blue should be added to the oil).

The following sources of error must be avoided in all cases where Bacteria are stained in sections, or in fluids from the interior of the eye:

[1] According to Mayon, better than polychrome methylene blue.

[2] Prepared by Grübler (Leipzig).

[3] Spread section carefully on the slide, dry with filter-paper; drop on a few drops of absolute alcohol and then alcohol and ether, and when section begins to dry wash quickly with 80 per cent. alcohol. Some celloidin must remain, or the section will fall to pieces.

[4] 'The Staining and Examination of the Bacteria of the Eye by Simple Practical Methods' (Jour. Amer. Med. Assn., 1906).

[5] A few drops of hæmatoxylin can be added (Wagenmann). Hæmatoxylin alone often shows organisms when overstained, especially *Staphylococci* and *Streptococci* in masses.

1. **Mast Cells** are often found in large numbers, especially in chronic inflammations. Their shape conforms to that of the connective tissue around; in the sclera, for instance, they are often elongated, so that sometimes it is only their processes which appear in a section. The stained protoplasmic granules, especially when derived from a breaking-down mast cell, at first glance are very like cocci, and take on Gram's stain. On closer examination the variable size of the granules and their connexion with a cell can be noted.

2. **Pigment.**—Retinal pigment, in the form of crystalline granules or rods, can be found in various parts of the diseased eye. The beginner may sometimes mistake this, as it often takes up a little aniline dye. Careful observation will prevent such an error. The granules are yellowish, transparent, and strongly refractive. This is much better appreciated in daylight than in lamplight, when everything looks yellowish.

3. **All Solutions must be Quite Free from Organisms.**—When staining sections of the eyeball, especially by the Gram-Weigert method, and on the slide, the sclera and optic nerve-sheath may fray out, and in the cracks incidental organisms may collect. In old lithium-carmine solutions cocci often occur. Filter every solution carefully.

Capsule-Staining.

(*a*) *Klett's method:*

1. In alcoholic watery methylene blue (methylene blue, 1; alcohol, 10; water, 100) sections are warmed until the solution boils.
2. Wash with water.
3. Five seconds in solution of fuchsin, 1; alcohol, 10; water, 100.
4. Wash in water and mount.

Bacilli, blue; capsules, red. Usually a good stain.

(*b*) *Friedländer's method:*

1. Two minutes in 1 per cent. acetic acid.
2. Wash and dry.
3. Few seconds in anilin-water-gentian-violet.
4. Wash dry, etc.

Bacteria, dark violet; capsules, light violet.

(*c*) *Johne's method:*

1. One to two minutes in a warm watery solution of methyl or gentian violet.
2. Wash with water.
3. Decolorize for ten seconds in 1 to 2 per cent. acetic acid.
4. Wash with water; examine in water.

Result same as (*b*).

(*d*) *Kaufmann's method:*

1. Stain for several hours with cold Löffler's methylene blue, or for two hours in the oven.
2. Wash with alkaline water (1 or 2 drops normal potash or soda in a large watch-glass of water).
3. Dry. Stain with $AgNO_3$ $\frac{1}{2}$ per cent. for two minutes.
4. Wash again with alkaline water.
5. Stain for thirty seconds in fuchsin (1 part of saturated alcohol solution to 20 parts of water).
6. Wash for a few seconds in alkaline water.
7. Dry and mount.

The organisms are blue, the capsules red.

We use the term *capsule* when a clear space is seen around every one, or around the majority, of the organisms in question. Several conditions may produce the same appearance: retraction of the surrounding medium, or of the coagulated substance of the secretion. Bacteria appear to be encapsuled when they lie in spaces produced by drying or heating. We should always note whether, in those parts of the preparation which are free from bacteria, similar clear spaces occur; naturally here and there Bacteria may have fallen out, but generally there will be no hesitation about the nature of these retraction spaces.

The capsules (mucous envelopes) are formed by the swelling of the ectoplasm, the outer layer of the bacterium. The majority of organisms which are generally considered to be capsule-free have a slight ectoplasm, which under special circumstances may become more obvious and quite visible. This is so with *Staphylococcus*, *Streptococcus*, *Coli communis*, and others. This fine differentiation is, however, not very apparent in the ordinary preparation, where we only see the envelope when it is well developed. The bacteria with a swollen ectoplasm appear to have a clear space around, which space, according to the amount of mucus it contains and the method of staining, will appear quite clear or coloured to a varying degree. We only use the expression 'well-marked capsule' when such an appearance is found.

The development of an ectoplasm is much less marked in *Pneumococci* from a conjunctival secretion than from a pneumonic sputum. Preparations stained with a simple aniline dye show the capsules most clearly when examined in water. Gram-stained preparations in balsam show them less clearly or not at all (see Plate II.). In *Pneumococci* from an ulcus serpens or mucocele, capsules are better seen. The clear spaces around stain very badly (in the allied *Streptococcus mucosus* the capsule stains readily). On account of this slight tendency to the formation of capsules Heim placed the conjunctival Fränkel-Weichselbaum *Diplococcus* intermediate between the *Pneumococcus* and the *Streptococcus*. The capsules, however, in pneumonic sputum are less well marked in the acute stage than in that of resolution, and the conjunctival *Pneumococci* agree completely with the same organism from other sources.

Capsules are always very clearly seen in Friedländer's *Pneumobacillus*, but vary somewhat in appearance. In this group they are quite easily stained, not only with the special capsule stains, but also with simple aniline dyes. The *Pneumobacilli* in Plate I. and in Fig. 3

show this. Where the safranin is of medium intensity the bacilli are dark red and the capsules light red. In overstained preparations the capsule is so dark that the bacillus appears to be very thick. At places where the film has been too much heated the capsule is shrunk, with a clear space around it, but the red membrane can still be seen closely surrounding the bacillus. In many cultures clear spaces will be noticed where the film has been overheated, and still the bacilli are kept discrete by a faintly-stained membrane.

The Diplobacillus possesses not nearly so definite a capsule. Using special stains, as did Bietti and Agricola (and Macnab for Diplobacillus of Petit) in my laboratory, an ectoplasm is readily seen,

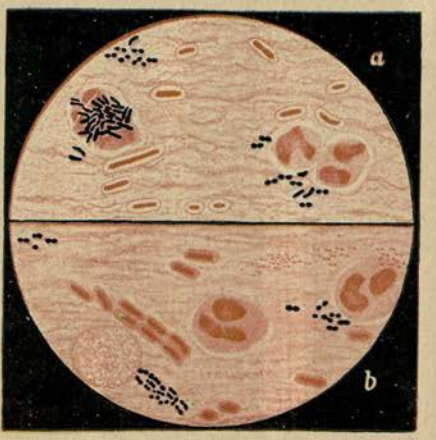

FIG. 3.—PUS FROM LACRYMAL SAC CONTAINING FRIEDLÄNDER'S PNEUMOBACILLI; ALSO IN *a*, B. XEROSIS; IN *b*, B. INFLUENZÆ.

The capsules of the *Pneumobacilli* appear clear in *a* and red in *b* (safranin overstain), a few *Pneumococci* blue.

but it generally does not show any considerable width. In Gram (balsam) preparations the appearance of the capsule is very inconstant, and in many cases entirely fails, so that here we have a ready means of differentiating the *Pneumobacillus*.

In preparations stained with simple aniline dyes and examined in water, the clear envelopes are more numerous and more visible, as is the case in photographs.

It is quite correct, as Gifford stated, that the Diplobacillus has a capsule. In the differential diagnosis it must be emphasized that in Gram preparations especially *the capsule is not marked*. I have never seen stained capsules in a preparation made by this method and

counter-stained with safranin or fuchsin, as is the case with the *Pneumobacillus*. In cultures the capsules are not so frequent; they may, however, be still quite distinct—*e.g.*, in the case of *Pneumobacilli*; in a smear made from a culture they appear to fuse together, and form a mass which separates the individual organisms from each other. At over-heated spots clear spaces are shown. Capsules are often seen in *Pneumococci* from the condensed water, and occasionally, too, from the surface, of an agar or blood-serum tube (*cf.* p. 184, Fig. 32).

In sections of hardened tissues—*e.g.*, cornea infected with *Pneumococci*—the capsules are not clearly seen; where large masses of the organism occur, it is obvious, from the looseness of their packing together, that some separating medium lies between the individuals.

Staining of Cilia.

1. *Löffler's method* gives good results. A surface agar culture, not more than twenty-four hours old, is taken, and its motility proved in a hanging-drop. A cover-glass is prepared by cleaning with ether and alcohol, and heating on an iron plate, so that it is absolutely fat-free. The merest trace of the culture is rubbed on the glass in a drop of water; after drying, fix by carefully passing three times through a flame. Too much heating damages the specimen. Mordant in the following solution: Tannin, 2; aqua, 8; sat. sol. ferri sulph., 5; alcohol, 1.

(*a*) Enough of this is run through a filter on to the cover-glass to entirely cover it. The whole is then carefully warmed until steaming (greater heat damages), and the mordant is allowed to act for one minute (longer is harmless).

(*b*) Wash with water under a tap.

(*c*) Rapidly wash in 96 per cent. alcohol.

(*d*) Dry rapidly in a draught.

(*e*) Stain with Ziehl's solution: Fuchsin, 1; abs. alcohol, 10; formol, 5; aq. dist., 100.

(Czaplewski recommends warm anilin-water-fuchsin solution, which, by the addition of caustic soda, is in a condition of suspension.)

Enough of this Ziehl's solution is filtered on to the cover-glass, which is then warmed till steaming; the fluid is allowed to act for about five minutes.

(*f*) Thoroughly wash, dry, and then mount in balsam.

2. *Van Ermengem's Method.*—Mordant for five minutes with warm osmium mixture (60 c.cm. of a 26 per cent. solution of tannin, 30 c.cm. of a 2 per cent. osmic acid, 4 to 5 drops of glacial acetic ac.). Wash first with water, then with alcohol, Moisten for several seconds with 0·5 to 2·5 per cent. sol. of silver nit.; then place for several seconds, without washing, in a mixture of ac. tannic., 3; ac. gallic., 5; sod. acet., 10; aq. dist., 350; and back again into the silver till the preparation begins to blacken. Wash with water, dry, and mount.

3. *Luca Valenti's Method.*—Drop a few drops of 20 per cent. ac. tannic. on the preparation; wash, warm for a short time with Ziehl's solution; wash; dry; and mount. According to Lehmann and Neumann, this simple method gives reliable results.

I have often been able to confirm the general experience that motility (in a hanging-drop) and the presence of cilia are very irregular,

especially in many members of the *Coli* group. I had a strain from a blennorrhœa neonatorum, in which Bietti was only able to show movement in agar or bouillon cultures less than ten to twelve hours old. In twenty-four-hour-old cultures only cast-off cilia could be found. Another strain of *Coli* from a case of keratomalacia, which had been sent to me for control as non-motile, showed typical cilia and movement in a twelve-hour-old culture. In deciding a diagnosis this must be carefully watched, and it must be remembered that longer cultivation can influence motility.

Staining Spores.

Möller's Method.—Combination of tubercle-staining with a previous mordanting with chromic acid.

(*a*) The cover-glass film (fixed in a flame or absolute alcohol) is dipped for two minutes in chloroform, and washed with water.

(*b*) Chromic acid 5 per cent. for one-half to two minutes.

(*c*) Wash with water.

(*d*) Carbol fuchsin heated to steaming for one minute.

(*e*) Differentiate with 5 per cent. sulphuric acid till the red colour is almost gone.

(*f*) Thoroughly wash with water.

(*g*) Aqueous methylene blue, or malachite green, one-half to one minute; wash, dry, etc.

(The organisms of the *Subtilis* group are the only spore-forming ones which we frequently meet with in ophthalmology. *Tetanus* is rarely seen; other spore-formers very rarely.)

Staining Methods for the Tubercle Bacillus.

A. In Smear Preparations.

Ziehl-Neelsen's Method:

(*a*) Stain with carbol fuchsin (ac. carbol. cryst., 5; alcohol, 10; fuchsin, 1; aq. dist., 100), warming till steaming for two minutes.

(*b*) Decolorize in 20 per cent. nitric acid, or 25 per cent. sulphuric acid, for five seconds.

(*c*) Decolorize in 60 per cent. alcohol till film is quite colourless.

(*d*) Contrast stain with aqueous methylene blue; wash with water, and mount.

Fränkel-Gabbet combines the decolorizing and the contrast stain. From the carbol fuchsin the film is put into the following mixture:—Alcohol, 50; sulphuric acid, 25; aq. dist., 100; and sufficient solid methylene blue to produce a deep blue colour; stained, then washed, etc.

To distinguish between the tubercle and smegma bacillus, Bunge and Trantenroth recommend that the preparation be placed for fifteen minutes in absolute alcohol to remove all fat. The smegma bacillus will then have lost its acid-fast property; the tubercle bacillus will not. Or (Weichselbaum) the stained preparation is put into a saturated solution of methylene blue in absolute alcohol for five to ten minutes, when the smegma bacillus will lose its red colour; the tubercle bacillus will retain it

B. Tubercle Bacilli in Sections (which must be very thin).

(*a*) Place the sections in Ziehl-Neelsen's carbol fuchsin for from twenty minutes to several hours in the oven (celloidin sections longer); then in 25$\frac{1}{2}$ per cent. nitric

acid, ten to thirty seconds (or in a 3 per cent. solution of hydrochloric acid in 70 per cent. alcohol, till the section is quite pale). If the section is still red, repeat the decolorization. Wash carefully in water then aqueous methylene blue, five minutes; better (Cornet-Meyer), also in hæmatoxylin. Wash, clear, and mount.

(*b*) *Borrel's Method.*—Embed in celloidin or paraffin. First stain sections in hæmatoxylin (complete differentiation); then stain in Ziehl-Neelsen's solution cold for twenty-four hours (10 c.cm. sat. alc. fuchsin sol. + 100 c.cm. 5 per cent. carbolic ac. in distilled water); wash with water; put in 20 per cent. aqueous aniline hydrochloride for twenty to thirty seconds. Differentiate in 96 per cent. alcohol, carbol xylol, balsam.

Sublimate is best for fixation, especially if (Borrel) 5 per cent. ac. acet. glac. be added. Zenker's solution is also very good. Formol is objectionable, as after its use the tissues are strongly fuchsinophile. Alcohol fixation, too, is less suitable.

Lepra Bacillus—Staining in Sections (Baumgarten).

Dilute alcoholic solution of fuchsin (1 : 4) six to seven minutes; differentiate with 10 per cent. nitric acid in alcohol; wash with water; counter-stain with methylene blue twenty to thirty seconds.

Lepra bacilli, in contrast to tubercle bacilli, stain very rapidly, even with this dilute solution.

Neisser's Granule Staining (Babes-Ernst Bodies in Bacilli of the Diphtheria Group).

(*a*) Acetic methylene blue (conc. alc. methylene blue, 20; aq. dist., 950; ac. acet. glac., 50); stain for one to three seconds.

(*b*) Wash with water.

(*c*) Contrast stain with Bismarck brown (Bismarck brown, 2; boiling distilled water, 1,000; filter) for three to five seconds.[1] Bacilli appear light brown, and the granules dark blue (*cf.* Fig. 4).

Neisser, in his latest paper, recommends:

Solution a.	Parts.	*Solution b.*	Parts.
Methylene blue powder ...	1	Crystal violet (Höchst) ...	1
Alcohol	20	Alcohol	10
Aq. dist.	1,000	Aq. dist.	300
Ac. acet. glac.	50		

Mix 2 parts of *Solution b* with 1 part of *Solution a*, stain for one second, immediately wash with water, and stain with chrysoidin (1 : 300 hot water and filter) for three seconds, wash, and dry.

Scheller (*Zentralblatt f. Bakt.*, 1905, xxxviii., Ref., p. 6) recommends ten to fifteen seconds for each dye.

For the diagnostic value of this stain, see chapter on 'Diphtheria,' p. 193.

Roux's Stain for the Diphtheria Group.—(1) Dahlia violet, 1; alcohol 90 per cent., 10; aq. dist. to 100. (2) Methyl green, 1; alcohol 90 per cent., 10; aq. dist. to 100. Mix 1 part of (1) with 3 parts of (2), and stain in the mixture for two minutes without heat. Bacilli are red, granules violet.

Stains for Spirochæta pallida (Schaudinn).

The thinnest possible films of the tissue are made on slides or cover-glasses, and fixed in alcohol for fifteen minutes, or exposed to osmium vapour for a few seconds (Schaudinn).

[1] Czaplewski recommends eight to ten seconds.

Giemsa's Method of Staining.—Giemsa solution for Romanowsky stain, 1 to 1½ drops; water containing 1 to 10 drops of $\frac{1}{1000}$ pot. carb., 1 c.cm. Mix fresh every time, and stain from fifteen minutes to one hour or more; wash rapidly, dry, and mount.

In a successful film the nuclei of the leucocytes are dark red, the *Spirochæta pallida* is light red, other *Spirochætæ* bluish. [Grübler of Leipzig prepares and sends out under the name 'Giemsalösung für die Romanowskyfärbung' the eosin-azur dye, the exact constituents of which can therefore be omitted.]

Improved Giemsa Staining (*Loffler*).—(1) 1 drop of a 0·5 per cent. solution of malachite green crystal double chloride of zinc, +3 drops of 0·5 per cent. solution of natrium arsenicosum, are put on to the thinly-spread preparation, which has been fixed in alcohol and ether; (2) heat to steaming for one minute; (3) wash with water; (4) mix 5 drops of 0·5 per cent. glycerine solution with 5 to 10 drops of Giemsa's solution, heat the mixture, and pour it hot on to the preparation. In five minutes wash with water. Staining is very sharp.

Preiss's Rapid Method.—Mix 20 drops of Giemsa solution with 10 c.cm. of distilled water; divide into three parts; pour one-third over the preparation, and heat it high above the flame until steam forms; pour away the stain, and repeat with each of the other thirds of the solution; wash with water. Good preparations can thus be obtained in four to five minutes.

Schmorl (*Deutsch. Med. Woch.*, 1907, p. 876) has lately given a method for demonstrating *Spirochætæ* in sections by differentiation with potash alum: (1) The sections are fixed in a 4 per cent. solution of formalin for fourteen days, frozen, cut without washing, soaked in distilled water or formalin, then stained with Giemsa's solution for twelve to fourteen hours in very carefully cleaned dishes. (2) Transfer sections to concentrated watery solution of potash alum; after a short time remove to distilled water for a few minutes; then mount in glycerine gelatine. Or lay the sections in water on the slide; dry with filter-paper; allow the sections to be almost absolutely dry in the air; then add xylol, and mount in cedar-wood oil. The tissues shrink, and the *Spirochætæ* are made more obvious. Alcohol must be avoided throughout.

Silver Method of Levaditi for Sections (*Ann. de l'Inst. Pasteur*, 1906, xx. 1).—The tissue is cut into small pieces (the anterior part of the eye can be treated as a whole), which are taken either direct into 96 per cent. alcohol, or first into 10 per cent. formalin for a few days, and then, after washing with distilled water, placed in alcohol for twenty-four hours. From alcohol they are placed in distilled water till they sink, and then in a dark vessel in the oven in 2 per cent. arg. nit. for three days (according to Gierke, better 1·5 per cent. for eight days). Wash with distilled water, and put into the following developing solution for forty-eight hours: Ac. pyrogall., 4; formol, 5; aq. dist., 100; embed in paraffin, and cut in series. The *Spirochætæ* appear black, with short and variable spirals and pointed ends; occasionally one end divides.[1]

Heim recommends Hoffmann's modification. The pieces of tissue, after fixation in alcohol and formol, are suspended by linen threads in a freshly-prepared mixture of 90 c.cm. 1·5 per cent. arg. nit., and 10 c.cm. purest pyridin. In this they remain for three hours cold, and then three hours in the paraffin oven at 45° C. in a dark glass-stoppered bottle.

The developing solution must be freshly prepared thus: Mix 90 c.cm. 4 per cent. pyrogallol with 10 c.cm. pure acetone, and add 15 c.cm. pyridin to 85 c.cm. of the mixture. In this the pieces remain cold overnight. Rapid paraffin embedding.

Contrast-staining with polychrome methylene blue is possible. All glass dishes must be thoroughly cleaned with ether and alcohol, and the solutions must be fresh.

[1] Regarding the diagnostic value of this method, compare later chapter, 'Syphilis.'

Culture Media.

Besides the usual media (agar, gelatine, bouillon, potato) whose preparation can be found in any bacteriological text-book, the more delicate media containing serum, are especially useful in ophthalmic work; in fact, many of the organisms with which we have to deal will only grow on these latter.

Löffler's blood-serum occupies the first place. This is obtained by collecting the fresh blood of sheep, cattle, or horses in clean sterile dishes, and letting it stand till the serum separates off. The serum is then decanted into a clean glass dish, shaken up with chloroform to sterilize it, and again decanted. It is then mixed with one-third its bulk of grape-sugar bouillon, poured into test-tubes (each 5 c.cm.), and on a sloping stage fractionally sterilized at 60° C. half an hour every day for a week.

Simple coagulation by moist heat at 100° C., as is carried out at many diphtheria research laboratories, cannot be recommended. Many organisms, *Staphylococci*, and especially those of the diphtheria group, grow very well on this 'cooked' serum, but others—*e.g.*, *Pneumococci*—grow very badly.

It is important that the serum—and this is true for all media in ophthalmic practice—should not be too alkaline, especially when we are dealing with the *Pneumococcus*. The bouillon should therefore be quite neutral, for the serum itself always has a marked alkaline reaction.

This last particular must be carefully attended to in the preparation of serum agar by the Wertheim formula. This medium is very valuable for growing the 'difficult' organisms (*Bac. Koch-Weeks*, *Bac. duplex*, *Pneumococcus*, *Gonococcus*, etc.), and when properly prepared in the following manner is by far the most useful: 1 per cent. neutral agar is liquefied, and cooled down to 45° to 50° C. in a water-bath; to this is added one-third to one-fourth its bulk of human serum (ascites, hydrocele, pleuritic, or ovarian cyst fluid), previously sterilized fractionally at 60° C. Immediately after mixing the tubes are sloped; they must not be further heated, or the serum would coagulate. It is just this addition of uncoagulated human serum which makes the medium so susceptible. These body fluids vary in alkalinity to no small degree, and when they are very alkaline the agar should be slightly acidified.

The suitability of sera varies, and is not even constant for one and the same organism. In making important determinations of growth, a trial culture should always be made with *Pneumococci* or *Gonococci*.

The *media containing hæmoglobin* have, in ophthalmic work, a very special importance with regard to the influenza group (*Hæmophile polebacteria*). On account of its richness in hæmoglobin, pigeon's blood is very useful; it can be rubbed over the surface of the blood-serum with a platinum loop, or added to the bouillon. Human blood can be obtained at operations, or else from one's own purified finger or ear; the first drop is not used, as it may contain skin organisms.

All blood media so prepared should have their sterility proved by

twenty-four hours in the incubator, for they are often contaminated by Bacteria, especially if a finger has been squeezed to assist in getting a drop of blood. In many cases it is better to mix the blood with the agar at 40° C. before the tubes solidify, and thus obtain an equal diffusion throughout the medium. The changes in the blood pigments and the hæmolysis, which have been emphasized by Neisser, Schottmüller, and others, can thus be better observed, especially on plates, than when the blood is spread on the surface.

Cultures.

In proceeding to carry out by cultures an examination of the Bacteria on the surface of a healthy or diseased eye, the material obtained should be rubbed, first on a good peptone or glycerine agar, then on Löffler's serum, then on serum agar, and finally on a hæmoglobin medium. Thus we have various possibilities in growth before us. And as the cultures become scantier as we pass on to the more susceptible media, we hope to find on them isolated colonies, from which pure cultures can readily be made.

In many cases, naturally, a good result is obtained with the simple media; but it is always advisable to take a few serum-tubes as well as the simple agar one, and from the very first to use various media.

The variety of culture-tubes used, and the number on which the material is stroked out, should be governed, whenever possible, by what is seen in the smear preparation. When the smear shows numerous organisms, several tubes or plates (Petri's) should be made originally, and only a small amount of secretion should be carried over from one tube to the next. When bacilli of the diphtheria group occur in the smear preparation alongside of ordinary cocci, the primary tube used should be agar, and the secondary one or two blood-serum, on which the bacilli in question may be isolated. The same is the case in dealing with the diplobacillary group: several questions will be decided at once by the particular medium used—*e.g.*, if *Diplobacilli* grow on agar they are Petit's type, if not Morax-Axenfeld's. The preference of different organisms for different media greatly facilitates their isolation—for example, a coccus may grow well on the agar-tubes, while a bacillus admixed may grow better on blood-serum. This is especially evident in the case of the delicate organisms and the media already mentioned.

In many cases it is advisable to try anaerobic cultivation, especially when determining some uncertain etiological relationship, or in deal-

ing with organisms whose determination is doubtful when examined microscopically. When separating by culture, organisms which are very difficult to differentiate, such a proceeding may assist greatly. It was by such means that *Streptothriciæ* from the canaliculi were first cultivated, and this result was first obtained in my own cases. In aerobic culture the cocci present overgrew everything, before the slowly growing *Streptothriciæ* could make any headway. Many facultative aerobic organisms retain their virulence longer in anaerobic culture; Gifford was thus able to produce a pneumococcal conjunctivitis with a culture which he had cultivated anaerobically.

Buchner's method is generally sufficient for such anaerobic cultivation:

Take a tall glass cylinder with a ground-glass lid, and pour into the bottom of it with a horn or glass spoon about 1 centimetre in depth of pure pyrogallic acid; add to this dilute (30 per cent.) caustic potash or soda solution; and then place the inoculated tube on a small glass tripod in the cylinder; quickly replace and seal the lid with paraffin or wax. The wool plug should be singed, or a little sublimate poured over it, lest after some time in the damp warmth any spores present in it should work out and contaminate the culture. Cultures deep down in the medium are occasionally useful, and sometimes cultivation in hydrogen by means of the Kipp's apparatus (*cf.* bacteriological text-books).

The direct inoculation of an animal with the material to be investigated sometimes results in the isolation of individual forms. An animal injected with sputum will die of pneumococcal sepsis. For intractable material—*e.g.*, concrements from the tear-ducts, tubercular matter, and recently in syphilis—direct inoculation is indicated.

The collection of preserved cultures can be very strongly recommended, especially for didactic purposes. Such a collection should not only consist of pure cultures, but also of original tubes directly inoculated from secretions, etc. After pouring off the condensed water, 1 or 2 drops of pure formol are dropped on to the lowest part of the culture, or the lower end of the wool plug is moistened with formol, and the top is covered for several hours with a rubber cap; the plug is then removed, and the mouth of the tube fused close. The cultures then remain permanent, and when protected from light retain their colour.

Inoculation into the Eyes of Animals.

Schmidt-Rimpler, in his research on the infectiousness of the lacrymal sac secretions, was the first to inoculate the cornea of rabbits or other animals with any organism or material containing bacteria. This is done either by means of an infected needle or knife point, or else by making a small oblique pocket in the cornea (easily

done on the luxated eye of a rabbit), and rubbing into it with a platinum loop some of the material in question. In the latter case so large an amount of the material is introduced into the tissues that the conditions are not parallel to those which obtain when the human eye is infected.

The inoculation wound must be made very obliquely—in fact, almost tangentially—to avoid perforating the thin cornea. It is advisable always to make a wound of the same size and position, and to use the same amount of material, so that a comparative idea of the virulence may be obtained. The same infecting agent, when centrally placed, will cause a more severe reaction, especially in the iris, than when in the neighbourhood of the vascular limbus.

With a very fine sharp cannula some infected fluid can be injected into the substance of the cornea. This is a rather more difficult technique, and the greatest care is necessary not to perforate the cornea.

In all these corneal inoculations in animals it must be borne in mind that large wounds, especially those forming a pocket, can become secondarily infected by other organisms from the conjunctiva or surroundings.

When an infection has resulted, it should be verified by removing material out of the pocket. I have often found that after an inoculation with *Pneumococcus*, this organism did not develop in the resulting purulent keratitis, as it happened to be of low virulence for the animal, but that *Staph. pyogenes aureus* was very plentiful.

An inoculation of the anterior chamber with solid or viscous material is easily made on the cocainized (not luxated) eye. After puncture more cocaine is instilled, and then a small particle is pushed in with an iris forceps or stylet. After a little practice this can be done without assistance. The puncture is best made up and out, as here the nictitating membrane is not in the way. The particle must be placed on the iris far enough from the wound, so that it will not be again extruded. The iris should be replaced out of the wound as thoroughly as possible.

When the material cannot be pushed in solid, it must be teased out in sterile fluid, and (as in the case of bouillon cultures, bacteria emulsions, pus, etc.), injected with a syringe. The aqueous should be first allowed to run out, as otherwise the injection could only be made against a rising tension, and when the syringe is removed the fluid would be squeezed out again.

For *vitreous inoculations* very small amounts can be at once injected through an oblique puncture. Larger amounts will cause an increase in tension, and when they must be used the anterior chamber

should be first tapped. The eye then is soft, and the puncture of the sclera is more difficult. The best method is, therefore, first to stick the syringe needle through the sclera, and then to puncture the anterior chamber, while an assistant holds the syringe. When pieces of tissue are to be introduced into the vitreous, the anterior chamber must always be punctured before opening the sclera, which latter must be done with the greatest care.

If it be especially desirable that the eye should be inoculated without wounding any vascular tissue, this can always be done through the centre of the cornea and lens (Römer).

The lids should be stitched after every inoculation of the eye. It is not necessary to stitch the whole thickness, but merely to bring a fold of skin from above or below over the opposite lid.

CHAPTER II

THE NORMAL CONJUNCTIVA

In studying the bacteriology of external eye diseases we must begin with that of the normal conjunctiva. The practical man will examine his own conjunctiva, and thus become acquainted with the saprophytes and common parasites of which he is the host. This study can be strongly recommended, because the organisms there present are scanty in number, and, being therefore isolated in the cultures, their peculiarities can be observed, and pure cultivations easily obtained.

As the conjunctival sac is open externally, it is only to be expected that all those organisms can be found in it which occur in the air, in washing water, in the skin around, or on anything with which the eye may come in contact. The great variety of organisms which may be found in these various places is reflected in the bacteriology of the conjunctiva.

Anyone taking the trouble to determine the peculiarities of all the organisms which could be found in a large series of conjunctivæ would certainly find very many varieties. Every research in this direction has produced this or that previously undescribed organism, and the future will furnish still more.[1]

Bach is an example of this. He found 27 varieties of Bacteria in 100 conjunctivæ, and described 13 of them as new forms. The serial examinations of Fick, Marthen, Bernheim, Lachowicz, Blagoweschenski, Gifford, Griffith, Jackson, Jameson, Basso, Rymowicz, and others, go minutely into the findings of every case.

On account of the great variation in the possible organisms, we can appreciate how authors' results can differ regarding the number and species of the various Bacteria found. It has been repeatedly

[1] In the dissertations of Brandt (Wurzburg, 1895) and O. Rosenthal (Berlin, 1905) are résumés of the findings according to various observers. These can be considerably reduced, for not unfrequently the same organism has been described under different names, and naturally these should not appear as distinct.

asserted that the flora of the normal conjunctiva is very variable, and that, to a certain extent, there are no constant inhabitants (Wolkowitsch). The flora is directly subjected to the changing influence of the incidental pollution around. The beginner at the present time can well appreciate this contention if he merely looks through the long list of the conjunctival organisms in the literature collection by Brandt. The opposite view is presented by Gelpke, who states that the conjunctival sac in ladies and girls of the upper social class is mostly sterile. This view, which, less definitely enunciated, recurs in the literature, presumes the idea that the bacterial condition of the conjunctiva is so definitely dependent on external influences that, when by the customary cleanliness of these people such influences are removed, the conjunctival sac will remain sterile. On the other hand, it is not surprising that, with different material, other authors have come to the conclusion that the conjunctival sac invariably contains a considerable number of different organisms (Blagoweschenski); and similarly we are not surprised to find that one and the same organism (*e.g.*, *B. xerosis*) is noted by one author as frequent, and by another as never found.

The following points must be considered if we are to arrive at a correct conclusion :

1. *The flora of this area, being subject to many contaminating influences, can, as a matter of fact, vary in quantity and quality according to the surroundings, to external conditions, and to personal habits.*

In this respect it is of interest to note that, as would be expected, Walthard,[1] Koblank,[2] and Cramer,[3] found the conjunctivæ of newly-born infants to be sterile. Organisms, however, began to appear in the first few days of life; in six days (Cramer) a few Bacteria could be found, after ten days many. When any inflammation had occurred, either at or after birth, by opening the lids during parturition, or from silver nitrate, etc., the organisms appeared relatively earlier.

After the organisms have settled down, the average flora does not materially differ from that of subsequent years. We have found the condition in children one year old not to differ markedly from that of adults. The statement made by Foote, that he found in children 50 per cent., in young adults 33 per cent., and in old people 30 per cent. of sterile conjunctivæ, certainly cannot be confirmed. So high a percentage of sterile cases is never found present in any life period, if sufficiently delicate methods are used and the material is properly collected; and the differences in percentage which he gives are within the limits of possible variation and error. Foote's other statement that the number of organisms is greater in the morning than in the evening can be considered as confirmed, for during sleep the cleansing lid movements do not occur.[4]

[1] Pflüger, *Korrespondenzblatt f. Schweitzer Ärzte*, 1895.
[2] *Festschrift f. Karl Ruge*, Berlin, 1898, p. 141.
[3] *Zentralblatt f. Gynäkol.*, 1899, No. 9.
[4] The findings of Marthen, Bernheim, Morax, Bach, Dalén correspond; they showed that the number of organisms increased under a bandage, which kept the lids still (and

Wolkowitsch emphasizes the fact that in one and the same individual the flora varies at different times of the day. This cannot be wholly denied; variations in the surroundings and in occupation are here of considerable importance.

We must, however, always remember that in the comparisons of flora, it is not feasible to make absolutely similar inoculations. It would only be possible to come to any conclusion if throughout a long series the variations were always the same. Changes in surroundings, occupation, and cleanliness can certainly influence the flora of the conjunctiva to this extent at least—that the idea of a 'normal conjunctiva,' as applied to hospital out-patients, recruited from the labouring classes, does not convey the impression which the pale, delicate mucous membrane seen in many private patients does. In the former a certain redness is very common, without being called pathological. A combination of a dusty atmosphere, even though not very full of Bacteria, with deficient personal cleanliness, and allied conditions, can produce an increase in the flora in the one class, and we must not be misled by the fictitious appearance of sterility in the pale conjunctivæ of the other. A. Fick found in normal school-children far fewer organisms than in the indolent inmates of a hygienically unfavourable charity school. If all slightly hyperæmic cases are excluded, *Diplobacilli* will be less frequently found in the 'normal' conjunctiva than was the experience of Erdmann and Rymowicz. The cases excluded are diplobacillary conjunctivitis of very mild degree.

2. *The method of examination which is used is of great importance in determining the bacteria present.*

With regard to the collection of material:

Morax dropped bouillon or melted gelatine into the conjunctival sac; this was allowed to soak into the folds of the membrane, sucked up into sterile pipettes, and inoculated on to the media. A much greater extent of conjunctiva was thus available than when the everted membrane was merely rubbed over with a platinum loop. On the other hand, the fluid more readily came in contact with the lid margins, the caruncle, and the inner canthus, so that the specimen was only a pure conjunctival one when the greatest care was exercised. Material taken from the inner canthus shows a considerably greater flora than is found in the conjunctiva itself. Further, it is doubtful if infected epithelial cells will come away with the fluid, while they can readily be rubbed off the surface with the loop. *Bacillus xerosis*, for example, clings to the desquamating epithelial cells, and thus is much more readily obtained when the loop is rubbed over the surface than when it only lightly touches it or merely removes the tears. The size of the loop and its shape, whether in a single or double twist, are to be considered. As, of course, only a small portion of the conjunctiva comes in contact with the loop, a negative result in cultures is not necessarily to be taken as a proof that the particular membrane is free from organisms. The loop, therefore, preferably bent double, should be well rubbed over the surface without contact with the margins or angles of the lids, and several attempts should be made from different positions. *When this method is adopted, a sterile conjunctiva is practically never found; and should such a finding occur, the next examination will probably show the presence of organisms.*

---

also raised the temperature). De Lieto-Vollaro obtained the same result when the lids were simply closed under a Fuch's wire frame, and Schirmer has proved by definite examination that when the blinking of the lids is prevented the passage of Bacteria into the nose does not occur.

Blagoweschenski wiped the conjunctiva with a sterile sponge, which was then ground up and inoculated on tubes. Dubief in the same manner used wool swabs. This method guaranteed a thorough inoculation, but more easily allowed a contamination, and may have been the explanation of his finding in thirty-four individuals the uncommonly large number of eighteen different bacilli: ten Cocci, five Tetrads and *Sarcinæ*, and one *Streptococcus*.

3. *Variations in the media and the technique employed are to a much greater degree responsible for the tremendous variations in the results of former years.*

The media are of slight importance in the case of the *Staphylococci*, and the similar vigorously growing organisms, which here, as well as in other parts of the body, attracted attention in the early days of bacteriology. Regarding them, the findings from the first have not varied much, when we consider the actual variations which are possible.

A very different state of affairs occurs in the case of *B. xerosis*. This has often only a very slight power of growth, due to the scanty nutrition which the tear-washed conjunctival sac affords. On its most susceptible media, therefore (blood-serum or ascites agar), after twenty-four hours, only scanty weak colonies can be seen; ordinary agar often enough shows absolutely nothing. If we leave the test culture for several days in the incubator, colonies may sometimes appear at places which at first were bare. I have often been astonished to find how apparently sterile cultures have developed numerous colonies of *Bacillus xerosis* after eight days or more in the incubator.

Other organisms again, like *Pneumococci* and *Diplobacilli*, depend upon the alkalinity of the medium for their growth.

Media which contain hæmoglobin must be used to decide the important question to what extent bacteria of the influenza group are normally present. Giarré, Picchi, and Rymowicz have used this means of examining the normal conjunctiva. Further research in this direction appears desirable.

With regard to the methods of examination, it must here be noted that single colonies of *Pneumococci* and also influenza bacilli can often only be discovered after most careful examination with a loop. Such colonies of *Pneumococci*, especially when on moist media, very rapidly become invisible by their margins merging with the surface moisture; besides which, when they are taken from the normal conjunctiva—a very unfavourable nidus for them—they have a very short life, and degenerate rapidly.

In the great majority of the older articles concerning the flora of the normal conjunctiva insufficient attention is paid to these par-

ticular points. I can neglect quoting or reviewing all these various records,[1] for when all of these precautions are observed, as is now customary, unanimous findings result, and every one can convince himself of their accuracy by his own research.

We can now take it as definitely proved that the normal conjunctival sac contains regularly, or almost regularly:

1. *The so-called Xerosis bacillus.*
2. *Non-virulent, or very slightly virulent, white Staphylococci.*

No other findings are constant.

The *Pneumococcus* is relatively the most common of the pyogenic organisms, but it is much rarer than the two organisms named, being very scanty and of low virulence (for animals). The other pyogenic organisms (*Staphylococcus pyogenes aureus* and *albus*) are not common if the skin around, and especially the lid margins, are not inflamed. *Streptococcus pyogenes* is rare.

On a healthy conjunctiva, according to my experience, *Diplobacilli* and influenzal bacilli are very rare (Erdmann found the former, Rymowicz, Giarré and Picchi found the latter, more frequently). Besides these, as accidental contaminations, we may find stray colonies of all sorts of pathogenic and saprophytic bacteria, amongst which, relatively speaking, yellow non-liquefying Cocci, *Sarcinæ*, and in some series *B. subtilis* (D. Smith, Puccioni), are common.

I will only quote one or two of the numerous recent researches made with suitable and delicate methods.

Rymowicz, working with glycerinated blood-serum (collecting material with saline solution after Morax), found in 100 normal conjunctivæ:

	Times.
Bac. xerosis	94
Staphylococcus albus (non-liq.) ...	79
Pneumococcus	9
Streptococcus pyogenes	5
Diplobacillus (Morax-Axenfeld) ...	6
Staphylococcus pyogenes aureus ...	6
Staph. pyog. albus	8

The *frequency* of pathogenic organisms in this series is relatively high. In individual cases their *numbers* were much fewer than those of the *Xerosis* and *Staph. albus*.

Under my own supervision, Heinersdorff in sixty-one cases (collecting with a double loop, and using Löffler's blood-serum), found:

	Per Cent.
Bac. xerosis	83
Staph. albus	85
Staph. aureus	11
Pneumococcus	5
Streptococcus	3
Sarcinæ	1
Other single organisms	5

Here, too, when pyogenic organisms were present, they occurred in very small numbers.

[1] This is fully done in my collected review, 'Bakteriologie und Parasiten,' 1894-1900, *Ergebnisse der Path. Anat. von Lubarsch Ostertag.* Wiesbaden: F. Bergmann, Jahr 3, 5, 6.

Örtzen examined eighty conjunctivæ with a double-looped needle, using glycerinated agar, proved susceptible to *Pneumococcus*, as the medium, and found:

	Per Cent.	
Bac, xerosis	57·5	(The number of *B. xerosis* is low because of the use of agar.)
Staph. albus	96·25	
Pneumococcus	4	(*Aureus* not found in this series.)
Various single organisms	5	

In considering the micro-organisms of the healthy conjunctiva, we must first devote special attention to the so-called **Bacillus xerosis** (*Bacille en massue*). Other synonyms: *Keulen bacillus*, *Bacillus sebi meibomiani* (Reymond and Colomiatti), *Bacillus septatus* (Gelpke), *Bacillus pseudodiphthericus vulgaris* (Heinersdorff), *Bacillus granulosus* (Lachowicz).

Those who would study the bacteriology of this region of the body at all, or would make any clinical diagnosis from it, must be quite conversant with the occurrence of this organism on the healthy conjunctiva, and must have personal experience on this point. Explanation and discussion of this subject would then be greatly facilitated. Erroneous doubts and useless controversy would then disappear, and those who have not gone deeply into the matter, but have followed the question in the literature, and would like to make practical use of their knowledge, would not then be confused and bewildered so easily.

It is instructive to glance at the history of the literature of this organism:

Bezold in 1874, in a case of xerosis and keratomalacia, found bacilli 'having the appearance of leptothrix,' whose fuller description resembles that of the later *B. xerosis*. Bezold was of the opinion, to which we have now returned, that a harmless inhabitant of the conjunctiva had greatly increased in number owing to the general disturbance of nutrition. In 1880 a short analogous notice by Denk followed. In 1881 Reymond, Colomiatti, and Perroncito published fuller descriptions, gave the organism the name *B. sebi meibomiani*, and considered it non-pathogenic. In 1882 Homer obtained similar results to Bezold in a case of keratomalacia.

The larger work of Kuschbert and Neisser, appearing in 1883, brought forward a new view. They insisted that the organism which they had found, occurred always and only in cases of xerosis of the conjunctiva. They attributed to the organism a causal significance, although an infection of the normal conjunctiva gave no result. Shortly after, but independently, came the well-known paper by Leber, who at first considered the organism as the cause of xerosis, but afterwards found these bacilli in the internal organs. Schultze had similar results. Leber furnished an exact morphological description.

In the same year Schleich reported that he had obtained pure cultures; he also found the same organism in the secretions in chronic conjunctivitis. Sattler and he found the organism in pus from the lacrymal sac, and threw doubt on its pathogenicity. Michel (1884) found the organism on normal conjunctivæ. Schleich

readily found the organism in the milky secretion at the canthus, and many considered that this condition was a slight degree of the specific disease.

Further investigations by Gallenga (1886), Fick (1887), Fränkel and Franke (1887), Schreiber (1888), showed this organism to be so widespread on the conjunctiva that any idea of a pathogenic function in xerosis must be given up. Using suitable media, especially blood-serum, Fick ('Über Micro-organismen im Conjunctival Sac,' Wurzburg, 1897) demonstrated that bacilli could be found in 80 per cent. of normal conjunctivæ, and in 100 per cent. of pathological conjunctivæ and operation cases. These bacilli were Gram positive for the most part, and their shape and characteristics agreed more or less with those of the *B. xerosis*. Fick described several varieties (*a*, *b*, *c*), and discussed the question whether these belonged to a group with the *B. xerosis* and the non-pathogenic *Luftstäbchen* previously described by v. Michel. 'This organism,' wrote Fick, 'should be familiar to every one who is looking for the specific cause of any disease, if he wishes to avoid still further increasing the present confusion'—a warning which was later greatly neglected.

Fränkel and Franke found the bacillus in many cases of chronic conjunctivitis, phlyctenules, and trachoma; that they did not find it on the normal conjunctiva can be explained by its lower vitality in this situation, and the greater difficulty in growing it. The definite conclusion from all these findings, that the bacilli are not pathogenic was emphasized by Baumgarten (Lehrbuch, 1890).

They appear again in the literature as pathogenic, for Kartulis, following up the findings of Koch (Koch-Weeks bacillus), obtained from certain cases cultures which he considered to be pure Koch-Weeks bacilli, although they obviously were the *Xerosis* which accompanied those organisms.

Weeks avoided this mistake, and showed that the club-shaped bacillus had nothing to do with the disease. When the conjunctiva was infected by them, no result followed, and a catarrh only resulted on an admixture of the other smaller Koch-Weeks bacilli. Weeks' experiments were a definite proof of the very frequent occurrence of harmless organisms in diseases caused by quite another germ.

Nevertheless these bacilli were later considered by Gelpke and Pes as the cause of epidemic conjunctivitis, the latter stating that the Koch-Weeks organism was identical with the diphtheria bacillus or *B. xerosis* (which he held to be the same organism). On account of similar findings, Eyre considered the organism, which he took to be an attenuated diphtheria bacillus, as the cause of follicular conjunctivitis. Schmidt and Kuchowski described it in cases of trachoma, without attributing any definite causal connexion. In the light of Fick's results one might have expected a universal acceptation of the presence of the *Xerosis bacillus* on the normal conjunctiva, and have considered the recurrence of these errors as impossible. For some considerable time there was a want of agreement about its occurrence. Many researches on the presence of organisms, especially with relation to disinfection, did not attempt their exact classification (Gayet, Van Genderen Stort, Santos Fernandez, Stroschein). Many others (Gifford, 1886; Bernheim, 1893; Hildebrandt, 1893; Franke, 1893; Gombert, 1889; Gasparrini, 1893; Blagoweschenski, Bach, 1894; Eyre, 1895; Puccioni, Foote) never found the organism on the normal conjunctiva; other authors (Lachowicz, Walkowitsch) did so only exceptionally.

A gradually increasing number of investigators found the organism either frequently or almost invariably (Fränkel, Uhthoff, Schanz, 1896; Peters, 1897; Morax, 1893; Cuénod, 1894; Coppez, Trousseau, 1894; Axenfeld, 1896; Heinersdorff, 1898; Lawson, 1898; Dalen, 1899; Spronck, 1896; Hirota, 1901). The text-books and hand-books of bacteriology considered its almost invariable

presence as an established fact, in some cases after their authors had made special control tests (Flügge Günther, Beck in Kolle-Wassermann, Lehmann-Neumann, and others). The fact is now generally accepted in ophthalmic circles. Again and again, however, the opinion is brought forward that this organism has a definite pathogenicity. Deyl and his pupil Hala considered it as the cause of chalazion; Peters considered it as a contributing cause in many benign membrane formations after injury to the conjunctiva. It was brought forward in cases of wound infection. Randolph and Del Monte considered that it took part in many cases of conjunctivitis. Gifford found it in lid abscesses. I will return to this question later on.

A complete description of this bacillus will not be given now, but will be found with that of the diphtheria bacillus (p. 190).

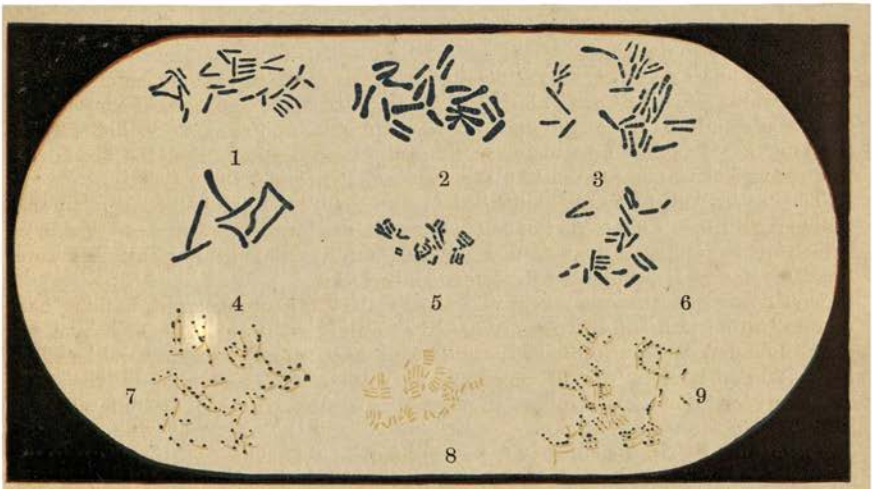

FIG. 4.—VARIATION IN SIZE AND SHAPE OF THE BACILLUS XEROSIS IN CULTURE.

1-6, Löffler's methylene-blue stain; 7-9, M. Neisser's pole-staining, 9 to 16 hours' culture on blood-serum; 7, virulent diphtheria bacilli, typical pole-staining; 8, Xerosis quite unstained; 9, Xerosis incomplete staining.

The sketches on the coloured plates, and in Fig. 4, which is by Heinersdorff, should be carefully noticed at this point.

The relation of this so-called *Bacillus xerosis* to the pathogenic Löffler's *Bacillus diphtheriæ* will now be shortly discussed. Some observers (Roux, Schanz, Peters, Hala, Behring, and others) consider that all these bacilli are identical with the diphtheria bacillus, and that the descriptive names 'pseudodiphtheria bacillus,' and 'xerose bacillus,' should not be used; we have either poisonous or harmless Löffler's (*i.e.*, diphtheria) bacilli which merge into each other. The harmless constant inhabitants of the normal conjunctiva can, under favourable circumstances, develop into virulent diphtheria bacilli.

Regarding this point, I would refer to the facts relating to the diphtheria group on page 190, and especially to the drawings Plate I., Fig. 1 and Fig. 6, *a* and *b*, and figures in the text (xerose and diphtheria bacilli) and would merely state that, as a matter of fact, a morphological and cultural differentiation of the organisms named cannot always be carried out.

A slender form, a clustered grouping, and a frequent peculiar varicosity, especially when a secretion smear is being examined, are no doubt points in favour of virulent diphtheria. After long experience and much practice in the examination of diphtheria, considerable certainty in diagnosis is attained, especially when cultures are available, so that it can be understood how Max Neisser, Morax, and others, rely considerably on this method. For a certain diagnosis, of course, it cannot be relied upon. In the same way a certain culture diagnosis sometimes cannot be carried out, although, *as a rule*, the *Bacillus diphtheriæ* grows more freely on blood-serum than does the *Bacillus xerosis*, forms acid in bouillon more strongly and rapidly,[1] and actually grows in the bouillon more diffusely and freely. But here again there is no absolutely constant distinction.

The method of polar staining given by Max Neisser cannot be considered as a radical distinction, for, as Schanz has stated, it only shows a difference in the rapidity with which the same phenomenon occurs.

In various xerose bacilli obtained from sixty normal conjunctivæ, Heinersdorff never obtained a characteristic staining reaction in a culture of more than nine to sixteen hours old, similarly Naito and Bietti. Gelpke, whose *Bacillus septatus* is identical with the *Bacillus xerosis*, never obtained a positive staining. Individual cases, however, are quoted in the literature where non-virulent bacilli have shown polar-staining (Doetsch, Bach and Neumann, Tertsch, Schwoner). If the claim be made that these were diphtheria bacilli which have become non-virulent, then the question arises as to how we can distinguish such from xerose bacilli. *A positive result with Neisser's stain in the case of the xerose bacillus must be considered as an extreme rarity.* I consider it necessary that the identical method of Neisser or Heinersdorff must be followed. It is not enough that a few granules should stain, but that a general polar staining should take place in the slender bacteria. For the future, too, it is very desirable, in exceptional cases, that the observations should be exactly described, and not merely the statement 'positive staining' given. Considering that, in the general bacteriological literature, cases of true diphtheria have been quoted with typical virulence for animals, in which polar staining failed (Lehmann-Neumann), a radical distinction cannot be based upon this point.

Attempts to differentiate the two by means of diphtheria serum (Schwoner, Tertsch) of high agglutinating valency show that the majority of xerose bacilli do not react. The latest experiments of Tertsch, however, show that not a few (about 20 per cent.) of the non-virulent inhabitants of the normal conjunctiva were agglutinated. If, with Tertsch, we deny the existence of true, but non-virulent, diphtheria bacilli, then we must conclude that the agglutination test is not an absolute differentiation. The practical application of this test in the case of organisms of the diphtheria group presents quite exceptional difficulties. It would be very interesting if attempts were made to exalt the virulence of these non-virulent agglutinating organisms.

[1] Further research is necessary before the difference in the acid formation with different kinds of sugar described by His, and later by Knapp, can be accepted as invariable.

The possibility that all these pseudo-diphtheria organisms are variations of the true diphtheria bacillus, cannot be excluded on the evidence available. Lehmann and Neumann, considering the literature of the subject, and also their own experiences, state: 'There is a large number of very closely related forms, consisting of both virulent and benign organisms, which can only be differentiated by varying combinations of characteristics; they form a considerable group, in which the true diphtheria bacillus is included.' However much the Roux-Behring hypothesis—the specific identity of the diphtheria bacillus with the closely related pseudo-diphtheria bacillus—may agree with the view of Lehmann and Neumann, and however much they may hope that this hypothesis will be confirmed by further cultivation, 'conclusive proof cannot yet be shown.' This is the position which we must take up regarding the 'Corynebacteria' of the eye.

Organisms resembling diphtheria bacilli occur widely distributed in the conjunctival sac, and also on the skin of animals.

Ollendorf (*Arch. f. Ophth.*, L., S. 455, 1900) recently described them in rabbits.[1] Blagoweschenski found them in several animals. I have found them in cats and rabbits, and, with Dr. O. Simon, observed them in fowls in an epidemic of conjunctivitis at Rostock. How widely these organisms are distributed and what errors they have given rise to is clear—and this may be a consolation to ophthalmologists—from the fact that they have been at times considered the cause of cow-pox, of syphilis, and of paralysis, only to have the statement denied or quietly abandoned.

According to Lobanow's experiments in my laboratory, the spread of these organisms is not generally through the air, but by contact, water, etc. The *Bacillus xerosis*, excepting one single strain, was not transported by a moderate draught, or the air currents of a room. The conditions are favourable for a contact infection at birth. The only record in the literature is that pseudo-diphtheria bacilli grew on serum-plates exposed in the wards of the Eppendorf Hospital. As, however, we find no such results in the literature of the bacteriology of the air, the term 'Luftstäbchen' (air bacilli) had better be given up, as the name emphasizes too strongly an infection through the air.

Staphylococcus albus.

The white *Staphylococci* are almost as numerous, and occupy the second place.

No small difficulty presents itself in making a classification of the **Micrococci** and **Staphylococci**[2] which will harmonize the results of the various authors with one's own experience. We have to deal with the large group of *Staphylococci* in which a number of well-marked types can be differentiated. The classification, however, is

[1] Randolph found *Staph. albus* more frequently.

[2] A general consideration of the *Staphylococci* can be found in M. Neisser and Lipstein, 'Die Staphylokokken. Handb. v. Kolle u. Wassermann,' 1903, Bd. iii., S. 106; and in Lehmann and Neumann, 'Atlas u. Grundriss,' 1906, 4 Aufl.

very much limited by the fact that varieties intermediate between the various types occur, in which sometimes one characteristic, sometimes another, is prominent.

It is simply impossible to describe as a new variety every strain which does not absolutely coincide with the strains already described, especially as many of their features alter on prolonged cultivation.

The pathogenic or pyogenic forms are first opposed to the non-pyogenic ones.

Regarding the *pyogenic* characteristics of the *Micrococci* of the normal conjunctiva, it is undeniable that the term 'pyogenes' is far too freely used in the literature. Many authors, without making control inoculations, always use this term when dealing with organisms developing the well-known white or yellow colour in agar cultures. In other cases the cornea is infected by making a pocket with the lance and introducing a loopful of the culture; a purulent reaction is then recorded when an opacity with inflammatory reaction develops, though it heals without perforation.

The term 'pyogenes,' however, should only be used in those cases where, after such a liberal infection, at least a rather severe inflammation results, with transient iritis and slight exudation into the anterior chamber. The inoculation experiment commonly made only shows that large numbers of the organism do cause a certain reaction, and by no means proves that such an organism is really to be considered as the cause of a suppuration or a wound infection, and thus deserve the name 'pyogenes.' If material be removed, either from such a pocket or the ulcer which results, a control research often shows that the cocci introduced very soon die out, and that the inflammatory reaction was not due to any pathogenic development of the organisms, but merely to the introduction of the bodies of the cocci.

The white *Staphylococci* of the normal conjunctiva are closely related to the **Micrococcus candicans.** Old colonies not infrequently show a small projection in the middle, and are marked with concentric lines. They do not appear to be so moist as the *Staphylococcus pyogenes*, but this varies with the medium. Where colonies have fused, their former margins often are still visible. They do not liquefy gelatine in a stab culture, but rapidly grow over the surface. Their behaviour on this medium, however, is not constant, for liquefaction may commence weeks later. Plate colonies appear darker in the centre and clearer at the periphery, being more or less granular. Under the microscope many strains show very slight tendency to occur in clusters, but, on the contrary, appear as *Diplococci*, the members of each pair having a narrow interval between them.

We have rarely found white cocci of the non-liquefying-gelatine variety which can cause a severe inflammatory reaction; and such certainly were never virulently pathogenic. With this limitation the pathogenic properties of the white *Staphylo-*

cocci found in the eye can be taken to correspond roughly to their power of liquefying gelatine. Those which liquefy freely are generally more purulent; those which do not are only rarely so.

Morax and Randolph have rightly emphasized the correspondence between the white *Staphylococci* of the conjunctiva with that form, so frequently occurring in the skin,[1] which Welch has called *Staphylococcus epidermidis albus*. They are characterized by an absence of virulence and toxicity, and often display the features of the *candicans*. We can conclude that the infection of the conjunctiva with these organisms takes place from the skin. From time to time we find in these skin organisms a relatively more frequent, though very slow, gelatine liquefaction; which may be due to their different conditions of life.

Many strains of this coccus prove to be non-pathogenic for the rabbit's cornea, and generally are not able to cause wound infection. But still it cannot be asserted that under different conditions—*e.g.*, a lowered power of resistance in the eye—they cannot lead to wound infection. We know that many saprophytes which remain indifferent in other parts of the body, are pathogenic in the eye. Cannot this also hold in the case of the white *Staphylococci* of the eye, the more so as they may be capable of an exaltation of virulence? (*cf.* chapter on 'Blepharitis,' p. 55). The action of the *candicans* in the interior of the eye has practically never been tested; Gifford alone reports having obtained a transient reaction after its injection into the vitreous. In two subacute wound infections after cataract extraction which I have examined I found in the interior of the eye white cocci only, which in one case would not cause a hypopyon-keratitis in rabbits, and in the other only liquefied gelatine after fourteen days.

[1] I must here mention that, according to the researches of Pfeiffer (*Wien. klin. Woch.*, 1903, S. 762), Von Stanziale (*Zent. f. Bakt.*, Orig., 1906, xlii. 2, 3, 4), the mucous membrane of the urethra, especially in its anterior portion, like the conjunctiva, contains non-virulent white *Staphylococci*, and polymorphic non-virulent bacilli of the diphtheria group, a similar condition to that which obtains in the surrounding skin. In the bacteriology of the genitalia the pseudo-diphtheria bacilli have also been the cause of confusion. A few years ago they were described as the cause of syphilis! *Bact. coli*, non-virulent *Streptococci*, and other bacilli, are also occasionally found.

In many respects the same is true of the bacteriology of the normal nose, where pseudo-diphtheria bacilli are practically always found; *Staphylococci* are very frequent, and *Pneumococci*, *Streptococci*, etc., are not uncommon. Great variations occur, as the varied assortment of organisms, taken in with the breath from the dust of the air, are precipitated, and remain in the anterior part of the nose; hence the frequency of *Subtilis* (Gotschlich, 'Kolle u. Wass. Handb.,' 1903, i., S. 148; Hasslauer, *Zent. f. Bakt.*, Orig., 1906, xli., S. 796).

Formerly a bactericidal function was attributed to the alkaline nasal secretion, and modern opinion tends to the view that the nasal secretion is merely a bad nutritive medium.

Staphylococci and pseudo-diphtheria bacilli (Unna's *Flaschenbazillen*), along with other rarer forms, are constant inhabitants of the skin (see the most recent researches into the bacteria of the normal external ear by Süpfle, *Zent. f. Bakt.*, Orig., 1906, xlii., S. 304; also Gotschlich, *loc. cit.*, S. 147.

I must further state that these cocci comparatively often show a hæmolytic activity which, according to Max Neisser, is a peculiarity of the pathogenic cocci. Further research is necessary on this question.[1]

The following cocci should be considered identical with the *Staphylococcus* or *Micrococcus albus*[2] (usually *non-liquefaciens*):

Coccus albus non-liquefaciens (Fick).
Staphylococcus albus non-liquefaciens (Rymowicz).
Staphylococcus epidermidis albus (Morax, Griffith, Jackson, Lawson).
[*Staphylococcus habanensis* (Santos-Fernandez) ?].
Micrococcus epidermidis albus (Randolph).
Micrococcus albus non-liquefaciens (Fick).
Staphylococcus brevis (Griffith), distinguished by the small size of the cocci.
Diplococcus amplus (Gromakowski, Basso).
Micrococcus candicans (Fick, Gombert, Marthen, Bernheim, Bach, Lachowicz, Dudzinski, Basso, Rymowicz).
Further, the greater proportion of the organisms called *Staphylococcus pyogenes albus* by many authors, and the *Trachoma cocci* (Michel, Kucharsky, Sattler, Goldschmidt, Staderini, Poncet, Petresco, Lawson), whose more exact description agrees essentially with the *Micrococcus albus*.

On account of the morphological similarity which these cocci, in secretion films, can show to the *Gonococcus*, I have named them Gram-positive *Pseudo-gonococci*, easily distinguishable by Gram's stain. This name is also used by Uhthoff, Brecht, and others, with the same significance. The name does not signify that the organism is a variety of the *Gonococcus*. At a later date I have used this name for the Gram-negative *Diplococci* resembling *Gonococci*, naturally merely to signify that these are morphologically similar *Diplococci*, which, however, cannot be considered as *Gonococci*.

Amongst the Gram-positive *Pseudo-gonococci* the *Micr. albus* and its allies take the most important place; it is exceedingly rare for pyogenic cocci to present this double appearance so thoroughly as does the *albus*.

The following occasional varieties are closely related, and, like the white cocci, have a low pathogenic value:

Staphylococcus cereus albus[3] (Santos, Fernandez, Basso).
Micrococcus cereus albus (Lachowicz).[3]
Diplococcus albicans (Gromakowski).
Diplococcus albicans tardus (Basso).
Diplococcus albicans tardissimus[4] (Basso).

[1] Bossalino succeeded by passage through animals in exalting the virulence of an *aureus*, which was low when obtained from the conjunctival sac of a rabbit operated for cataract. Rupprecht has commenced a similar attempt with the common *albus* in my own laboratory, and has sometimes had definite exaltation.

[2] In the lists by Brandt and Rosenthal, where the majority of the organisms here quoted will be found, they are erroneously arranged as different species, some as pathogenic, others as non-pathogenic.

[3] This variety, recorded by Passet, and characterized by a waxy gloss, thick growth, slow development, and no liquefaction of gelatine, was considered as pyogenic by Günther. It is not so in the same sense as is *aureus*, and it is not pathogenic for animals.

[4] Abelsdorff and Neumann identify their Gram-negative *Diplococci* with this organism. The single statement of Bumm that the *Diplococcus tardissimus* is Gram-negative, on which Abelsdorff and Neumann base their diagnosis, cannot, however, be allowed.

I have often seen *albicans* organisms, which from slow growth have appeared as thicker, whiter, and shining cultures, though only as isolated colonies.

The organism which Bach and Basso described as *Micrococcus concentricus* is characterized by the very definite concentric marking of its flat slightly iridescent colonies. I have sometimes cultivated this organism; it is comparatively rare.

White *Staphylococci*, markedly pyogenic and thoroughly deserving that title, which rapidly liquefy gelatine, and in small numbers produce a purulent keratitis, are rare; very few of the cocci described in the literature under this name can be certainly identified as such. A certain number of the cocci described as *Staphylococcus pyogenes albus* and *Micrococcus pyogenes albus* belong to this group; how large a number cannot be stated with certainty. My own experience of a large number of conjunctivæ has been that a markedly pyogenic *Staphylococcus pyogenes albus* is rare in the normal conjunctiva.[1] Heim ('Lehrbuch der Bakt.,' 1906) states that he has never obtained the *Staphylococcus albus* from pus, and contrasts with the *Staphylococcus pyogenes aureus* the 'skin cocci,' which the common conjunctival cocci so strongly resemble. I quote this opinion as one of many, only to illustrate how, in this respect, the conjunctiva presents analogies to the surrounding skin.

Amongst the colonies designated by many authors as **Staphylococcus pyogenes aureus** (Rosenbach), there are some which do not merit this name. Their diagnosis should not been made so rapidly as is often the case, merely on account of the yellow or orange-yellow colour.[2] A mistake here is far less frequent than in the case of the white cocci of the conjunctiva, for the majority of such orange-yellow colonies do, as a matter of fact, prove to be the pyogenic form with the well-known characteristics, of which I will only give a summary:

Round cocci of variable size, averaging 0·7 to 0·9 μ (Günther) in diameter, though in many purulent effusions larger or smaller (*cf.* p. 236), multiplying by fission. (Individuals dividing appear as *Diplococci*, and though when deeply stained appear round cocci, when faintly stained may show the line of cleavage.) They usually lie in clusters, and stain deeply by Gram's method. Growth occurs on all common media, even if weakly acid, at room temperature or in the incubator.

On *agar* or *blood-serum* round raised colonies, with smooth edges, develop. Under the microscope they appear coarsely granular. Macroscopically after twenty-four hours' growth (aerobic) moist, glistening, greyish-white colonies appear, and in the next few days take on a bright orange-yellow colour, the depth of which and the rapidity of its development vary with different strains. Many develop the colour more quickly when daylight is excluded.

When kept for long in a bright light, on the contrary, the colour fades completely. It is retained for a longer time in the dark. (This occurs in preserved cultures.) After continued propagation the formation of colour gradually diminishes, and in the end completely disappears.[3] It can be recovered by passage through an animal,

[1] I have been able to gain a large experience on this question, seeing that many investigators doing bacteriological work in my laboratory begin with the normal conjunctiva, especially their own, and conduct virulence tests of the organisms found. Thus I am able often to demonstrate in my clinic the relatively harmless nature of the conjunctival organisms.

[2] M. Neisser makes the same criticism of the recorded findings in the air, etc.

[3] Leber has observed these colour variations. Many writers would explain *aureus* and *albus* as varieties, each of which can be transformed into the other.

though there are strains which remain permanently bleached, and then appear as a dirty white *Staphylococcus pyogenes*.

Bouillon and gelatine, in which the *Staphylococcus pyogenes aureus* grows rapidly, become acid, the latter showing a beautiful liquefaction, with the formation of an orange-yellow deposit at the bottom of the excavation. When the gelatine is completely dissolved, and similarly in the bouillon, a thick slimy deposit is formed. The cultures smell like sour paste. The formation of acid is specially strong in the case of media containing sugar. Milk is coagulated.

Aureus remains living and virulent for a very long time, but its pyogenic properties gradually disappear on cultivation, though they can be regained by passage through an animal.

Its pyogenic activity in the cornea causes ulceration; if very virulent, rapid perforation and panophthalmitis. Infection of the anterior chamber and of the vitreous as a rule leads to panophthalmitis and discharge of the pus externally. The degree of inflammation depends, of course, upon the number and the virulence of the organism in question (*cf.* p. 79 of the 'Researches of Andogski'). Less acute inflammations may occur, just as in the case of ulcerative and fungating endocarditis. In the serous cavities, and also in the eye, such cases have been observed (*cf.* 'Wound Infection,' p. 159). These have been experimentally studied by Leber and Deutschmann.

Among the pyogenic toxines[1] formed by the *aureus*, the most important are *leukocidin* (Van der Velde), and *staphylolysin*, a powerful hæmolytic poison,[2] isolated by Neisser and Wechsberg, which is very readily obtained from blood-containing media. This hæmolytic action and the power of producing a hæmolytic serum and immunity, according to M. Neisser, is peculiar to the pyogenic forms, and supplies a delicate differentiation from the purely saprophytic *Staphylococci*.[3] An agglutinating serum is produced, and a 'serum diagnosis' in cases of staphylococcal infection is possible by testing the clumping power. It must be admitted that a positive result is not always feasible in an isolated staphylococcal infection.

According to the researches of Neufeld and Rimpau, and also of Wright, the 'bacterio-tropic' property of the serum—*i.e.*, the increased phagocytic action—is often increased against *Staphylococcus* in the case of staphylococcal infections. A positive diagnosis by this means has not yet been made.

Besides the *Staphylococcus pyogenes aureus*, there are a number of other cocci which produce a yellow pigment.

Lehmann and Neumann classify the other cocci which develop sulphur or lemon-coloured pigments on gelatine and agar as follows: *Micrococcus luteus* (powerfully liquefying; gelatine culture coarsely granular); *Micrococcus flavus* (Flügge—gelatine culture finely granular, powerfully liquefying); and *Micrococcus sulphureus* (Zimmermann—gelatine culture finely granular, not liquefying). All three are non-pathogenic.

The *Micrococcus aurantiacus*, found by Basso and Bach on the conjunctiva, and also occurring often in the air, is orange-yellow, does not liquefy gelatine, and is non-pathogenic.

[1] By a process of alcohol precipitation, Leber demonstrated an intensely pyogenic chemiotactic deposit of phlogosin, which contained the staphylococcal poison.

[2] Concerning the further toxic actions—necrosis, pigmentation, leucocytosis—and fermentation, see Neisser and Sipstein, *loc. cit.*

[3] Dr. Rupprecht and myself have had results with the *Staphylococci* found in the eye which contradict this: we found hæmolysis in the case of non-pathogenic strains from the conjunctiva.

The organisms described in our literature as *Micrococcus flavus desidens* (Burchardt, Bach, Basso, Wilbrand, Sänger, Stählin) and *Micrococcus subflavus* (Wilbrand, Sänger, Stählin) are characterized by very slight pathogenicity, and the absence of liquefaction in gelatine. The *Staphylococcus cereus flavus* (Bach, Lachowicz, Basso), so called by Passet on account of its dull, wax-like appearance, does not liquefy gelatine, is only feebly pyogenic, and is closely related to the above-named yellow cocci. In the latest literature this variety is no longer noted.

The *Micrococcus sulphureus* of Zimmermann, which Lehmann and Neumann considered as a non-liquefying form of their *Micrococcus flavus*, is a lemon-yellow coccus, of which I have several times obtained specimens. It does not liquefy gelatine, and only produces a slight inflammatory reaction in the cornea. Many cultures of this variety grow very slowly, and correspond to the *Micrococcus sulphureus tardigradus* (Flügge), which Lehmann and Neumann considered as merely a variety of the former. The *Micrococcus citreus* (Basso) of the conjunctiva is identical with this organism, and the *Diplococcus citreus conglomeratus* of Bernheim, Bach, and Basso is closely related.

Passet's form of the *Staphylococcus pyogenes citreus*, which liquefies gelatine like the *aureus*, and produces a free suppuration in the rabbit's cornea, is much rarer. I have only found it twice in scattered colonies. It is not possible to determine from the scanty details given whether the *Staphylococcus citreus* described by Pollock was pyogenic or not.

The **Sarcinæ** (especially *Sarcina lutea, aurantiaca, flava, alba*) occurring in the conjunctiva not infrequently, though mostly in isolated colonies, are related to the non-pathogenic cocci to this extent, that they can appear in the secretion as *Diplococci* or *Tetracocci*. Very possibly the large *Diplococci*, which are sometimes met with in the secretions from chronic conjunctivitis, and which, when faintly stained, can be differentiated as Tetrads, are really *Sarcinæ*. Although in the course of years I have often seen colonies of *Sarcinæ* in cultures, and have always compared the smear preparation with the culture, I cannot remember having seen a definite packet form in the conjunctival secretion, and if such did occur in a fluid it would be very easily recognized. Tetrads, too, have very often a peculiar grouping.

Migula, Stubenrath, Lehmann, and Neumann, have bridged over the line of separation between *Sarcinæ* and *Micrococci*. These investigators succeeded, on suitable media, especially hay-infusion, in growing *Sarcinæ*—forms of many *Micrococci*. In this manner Migula produced

a packet form of *Micrococcus tetragenus*,[1] and called it *Sarcina tetragena*. This name has since been confirmed and adopted by Lehmann and Neumann. The relationship between the *Sarcinæ* and the *Micrococci* is still further pursued by Stubenrath and Lehmann and Neumann, who speak of a 'sarcina-form' of their *Micrococcus luteus* and *flavus*. From the *Micrococcus roseus*, too, they developed a *Sarcina rosea*.[2]

Sarcinæ are generally distinguished by their slow growing, very prominent and deeply-coloured colonies especially well seen on agar or potato. Gram-staining in general is positive, but there are Gram-negative *Sarcinæ*. I have myself grown one from the conjunctiva, and in the secretion preparation it took the form of large Gram-negative *Diplococci* rolled up in balls, surrounded by a clear envelope like a capsule (*cf.* Plate II., Fig. 3).

Gasparrini (1895) was the first to positively assert the presence of **Pneumococci** on the normal conjunctiva. He stated that he had found them in a virulent form on 80 per cent. of normal conjunctivæ, thus proving that this membrane resembled the buccal cavity in generally containing *Pneumococci*. In collaboration with Oertzen, I have proved in a large series of cases, on the contrary, that the *Pneumococcus* is not so common in the conjunctiva as is the *Xerosis*, or as the 80 per cent. of Gasparrini would show. It was necessary to settle this question by a long series of examinations, for Gasparrini's statement had entirely altered our views of the danger of infection. The older records in the literature referring to this problem could not be relied upon, as Gasparrini had used an entirely new method—namely, the direct introduction into the tissues, of the conjunctival secretion on sterilized swabs. We did not obtain a pneumococcal infection in a single instance when using Gasparrini's method, and therefore concluded that some mistake had occurred in his experiments. We, on the contrary, using very susceptible glycerine agar, only found *Pneumococci* twice in forty-nine eyes. The *Pneumococcus* can be found here and there on the normal conjunctiva. Lawson carefully examined 200 cases with blood-serum, and found it only twice.

Rymovicz (*loc. cit.*) found it in 9 per cent. of his cases, Heinersdorff in 5 per cent. Seeing that the presence of *Pneumococci*, in the small numbers in which they occur, is rather difficult to demonstrate, it is not impossible that they really occur somewhat more frequently. I incline to this view because of the fact that *Pneumococci* occur so very

[1] This organism has been found on the conjunctiva by Dudzinski, Gromakowski, and myself. It occurs rarely in that situation.

[2] A *Staph. pyog. aureus* approximating to a *Sarcina* has recently been examined in my laboratory by Tschirkowski (K. M. f. A., 1908, i.).

frequently in the secretions from dacryocystitis. As the infection in many of such cases comes from the conjunctiva, they must not be so rare in this situation; or else we must conclude that dacryocystitis has a tendency only to occur in those people who have *Pneumococci*.

At any rate, the results of the earlier researchers, who never found them at all on the normal conjunctiva, are not conclusive; although from the recorded findings, the *Pneumococci* may not be demonstrable in a short series of cases. It is unnecessary to emphasize the fact that this occasional occurrence of the *Pneumococcus* on the conjunctiva can be reconciled with its frequent pathological significance (*cf.* chapter on 'Pneumococcal Conjunctivitis').

The *Pneumococci* which we cultivated from the normal conjunctiva were of low vitality, and very slightly, or not at all, pathogenic for animals. They evidently suffered from a want of nutrition in the conjunctival sac. A danger of wound infection could only arise from them under very exceptional circumstances. That they can, however, play a part here is proved by many occurrences of wound infection, and especially by a case in our clinic published by Oertzen (*cf.* 'Pneumococcal conjunctivitis'—literature).

Streptococci rarely occur on the normal conjunctiva. The recorded cases in the literature, the evidence of which is merely from cultures, can be regarded with a strong suspicion that they were really *Pneumococci*. The latter readily grows in chains, and when all the differentiating tests are not carried out, especially the inoculation of a mouse and examination of its heart's blood for lancet-shaped capsulated *Diplococci*, a differential diagnosis is often quite impossible. This test, however, has only been applied to a very few of the so-called *Streptococci*.

The following *isolated, and generally non-pathogenic organisms*, have been found, which need not be further considered; into their differential diagnosis I will not go:

Micrococci:

Diplococcus or *Micrococcus roseus*[1] (Bach, Basso); *Diplococcus fluorescens liquefaciens liquidus* (Bach, Basso); *Micrococcus prodigiosus* (Schmidt); *Micrococcus cinnabareus* (Bach); *Micrococcus aquatilis* (Basso); *Micrococcus carneus* (Basso); *Pediococcus cerevisiæ* (Basso); *Micrococcus coronatus* (Lachowicz); *Micrococcus coryzæ* (Bach).

Bacilli:[2]

Bac. nodosus parvus (Marthen); *Bac. luteus* (Wilbrand, Sänger, Stählin, Jackson); *Bac. cuticularis* (Bach); *Bac. inflatus* (Bach); *Bac. mesentericus* (Bach, Franke, Basso); *Bac. prot. vulgaris* (Fick, Bach, Puccioni); *Bac.*

[1] These are classed together by Lehmann and Neumann.
[2] The identification of many of these bacilli is not very satisfactory.

latericius (Bach, Bosso); *Bac. sporiferus* (Lachowicz); *Bac. subtilis* (Puccioni, Shongolowicz, Bach, D. Smith Jameson); *Bac. fluorescens putridus* (Lachowicz); *Bac. fluorescens liquefaciens* (Fick, Basso); *Bac. diffusus*, *Bac. butyricus*, *Bac. aurantiacus*, *Bac. albicans*, *Bac. pateriformis*, *Bac. liodermos*, *Bac. aureus*, *Bac. ochraceus* (all by Basso); *Aerobac. citreus* (Jameson); *Bac. coli communis* (Jameson).

Here and there isolated colonies of **Streptothrix** (von Michel, Cazalis, Bach, Gombert, Axenfeld); **Moulds** (Fick, von Michel, Bach, Plant, von Zelewski); **Hefa-colonies**, especially *Rosa hefa* (Fick, Bach, Axenfeld, Fortunati).

The foregoing résumé illustrates the truth of the conclusion, arrived at from pure clinical observation, that *the normal conjunctiva in the majority of cases contains no virulent pyogenic organisms;* in a small minority isolated instances may occur, but rarely are they present in numbers. The ordinary flora cannot be considered as absolutely causing no danger,[1] though the risk of infection from the normal conjunctiva is relatively slight.

The number of organisms in the conjunctiva is considerably less than in the adjacent lid margins, and their conditions are not favourable to vigorous growth. The temperature of the conjunctival sac,[2] although at least 2° C. lower than the mouth, is certainly more favourable than that of the lids, and is quite high enough for the growth even of delicate bacteria; on the one hand, however, the tears form a bad medium for growth,[3] and on the other the number of the organisms is continuously being lessened by the flow of sterile tears through the sac into the nose. This last condition, the mechanical flushing, is of great importance respecting its organismal contents. The importance of the blinking of the lids as a factor in purifying the sac was first stated and emphasized by Horner, Widmark,[4] and van Genderen-Stort.[5] After numerous experiments with the easily distinguishable red Kieler water bacillus, Bach[6] showed that, after an artificial infection of the human conjunctiva, the bacilli could very soon be found in the nose, and in a few hours had quite disappeared from the conjunctiva, and that more rapidly when the patient blinked vigorously. Schirmer[7] demonstrated that, in the absence of winking, there was no transmission into the nose, for the passage of tears

[1] Compare Gifford, Journal of Amer. Med. Soc., October 3, 1903.

[2] Compare here, and also concerning the temperature of the various parts of the eyeball, the works of Dohnberg (Inaug. Dissert., Dorpat, 1876), Galezowski (*Recueil d'Oph.*, 1877, p. 275), Michel (*A. f. O.*, 1886, xxxii., p. 266), Silex (*A. f. A.*, 1893, xxvi., S. 141), Giese (*A. f. A.*, 1894, xxviii., S. 292).

[3] It contains albumen, 0·5 per cent.; NaCl, 1 to 1½ per cent.; NA_2CO_3, 0·1 to 0·2 per cent.; $MgSO_4$, 0·05 per cent.; Na_3PO_4, 0·05 per cent. The extent of the bactericidal powers of the tears is discussed in the chapter on 'Wound Infection.'

[4] *Beiträge z. Ophth.*, Leipzig, 1890, S. 179.

[5] *A. f. Hyg.*, 1892, xiii. 4.

[6] *A. f. O.*, 1894, xl. 3.

[7] 2nd edit. of Saemisch's 'Handbuch,' 1904, and *Zeit. f. A.*, 1905.

occurs solely from the action of the orbicularis muscle, especially that portion called Horner's muscle. Under these circumstances, organisms which have got in, even if pathogenic, cannot easily settle down, unless, like the *Diplobacillus*, Koch-Weeks, etc., they have a special affinity for the conjunctiva. Even when there is a special predilection for organisms, such as occurs in the case of the white *Staphylococci* and *Xerosis*, which are always working in from the lids, a true growth only occurs to a very limited extent under normal circumstances, and similarly the development of a high degree of virulence is difficult. The conjunctival mucus is only a moderately favourable medium for growth (Bach).

It is well known how, by 'antagonism'[1] or by choking, the presence of the normal saprophytes can hinder other organisms from settling down or growing. It is not known whether any such peculiar property occurs with the commonest inhabitants of the conjunctiva, the white *Staphylococci* and the *Bacillus xerosis*, to such an extent as to be important in the pathology of the eye. In cultures they flourish alongside the pathogenic organisms without causing them any demonstrable restriction. Rapidly growing pathogenic forms, such as *Staph. aureus*, *Bac. coli*, or *Pneumobacillus* overgrow the *Bacillus xerosis*, completely cover the medium, and change its reaction, before this latter organism can develop. In the case of the ordinary *Staphylococcus albus*, which alters media far less rapidly or markedly than the *aureus*, the development of the *Diplobacillus*, Koch-Weeks bacillus, influenza bacillus, or *Gonococcus*[2] is not restricted in spite of their susceptibility and need for alkalinity.

On the contrary, it is not impossible that the conjunctival inhabitants assist in determining the deposition and growth of many germs. The extremely intimate mixture in which xerose and Koch-Weeks bacilli occur in secretions and cultures was long the cause of our inability to obtain pure cultures of the latter, and still makes its pure cultivation exceedingly difficult. In slight cases, where the organism has no high degree of virulence, a mixed growth of xerose and Koch-Weeks bacilli can be cultivated, although the latter often cannot be propagated alone, and dies out. The function of the xerose is

[1] Garrè found an antagonist to the *Staph. aureus* in the *Bac. fluoresc. putridus*; Döderlein, Menge, and Kroenig in the anaerobic vaginal bacilli.

[2] The conclusion which Randolph (Bull. of Johns Hopkins Hosp., Balt., October, 1906) drew from typhoid bacilli not occurring in the conjunctiva in typhoid fever, and the *Pneumococcus* being as common there in healthy subjects as in pneumonia patients—that these organisms are held off by 'antagonism'—is certainly not proven, and is unlikely. Such an antagonism does not occur in cultures. There is no reason to presume that in these diseases the organisms are very often carried to the conjunctiva.

symbiotic. The same is true for the allied influenza bacillus, which, according to M. Neisser and Rymovicz ('Postemp. okul.,' 1901), can be propagated in symbiosis with xerosis, but alone dies out even on hæmoglobin media. L. Müller has also recorded the benign influence of what he calls 'air germs'—*i.e.*, the *Staphylococci*—on his bacillus (*B. Müller*), *i.e.*, the *Bacillus influenzæ*. The conjunctival *Staphylococci* also have the same action. Usher and Fraser have corroborated this by numerous experiments (R.L.O.H. Reps., 1906, xvi., p. 434). *Bacillus xerosis*, *Staphylococci* and *Diplococci*, favour the growth of Koch-Weeks bacilli, which flourish in their vicinity, when cultures are made from these united organisms. The Koch-Weeks organism can subsequently be cultivated alone, though at first it would not grow without their presence.

Rymowicz has reported a similar fostering action of xerosis on the *Diplobacillus*. In conjunction with Macnab I have, after many trials, failed to convince myself that such is the case. Both organisms grow well together on blood-serum, but the *Diplobacillus* does so alone. We failed to induce strains of these *Diplobacilli*, which would not grow by themselves on simple agar, to do so in symbiosis. Similar attempts with *Gonococci* have so far failed.

The fact that Koch-Weeks bacilli are pathogenic exclusively in the eye only finds a partial explanation in its symbiosis and furtherance by the xerosis, for pseudo-diphtheria bacilli occur also in the nose, in the throat, and elsewhere; but the Koch-Weeks is not pathogenic in these sites; although carried by the tears, it comes freely in contact with their mucous membranes. A complete explanation of this exclusive action on the eye is for the present not available, as in the similar phenomenon in the case of trachoma. Some affinity, or some peculiar type of 'receptor,' must be present to determine the infection in this locality.

The support which the Koch-Weeks and influenza bacilli receive from the presence of these organisms is repaid by the improved nutritive conditions for the saprophytes due to the inflammatory reaction produced by the presence of the pathogenic organisms. Xerose bacilli from an inflamed conjunctiva grow more easily, more profusely, and are not so dried up. In the case of *Staphylococci* this, however, is less marked. In some cases certainly the catarrhal secretion seems sufficient to cause the saprophytes to disappear, and that to a varying degree in various infections. Thus, for example, at the height of a pneumococcal conjunctivitis the *Pneumococci* may be found in pure culture, but as it decreases the saprophytes again become evident.

Opinions vary as to whether any increase of virulence in the saprophytes—xerosis and *Staphylococcus*—is possible from the rise of temperature due to the inflammatory process, the increased nutrition of the part, and the symbiosis with pyogenic Bacteria; and whether, as a result, these saprophytes may become pathogenic, and play some part in the further development of the inflammation. Gourfein and Doret (*Thèse de Genève*, 1905) state that the *Bacillus xerosis* causes a more marked reaction in the cornea and anterior chamber of a rabbit when it is got from an inflamed conjunctiva than when obtained from a normal one.[1]

Pes reported having produced an inoculation œdema when using *B. xerosis* and *Staphylococcus*, obtained from an acute conjunctivitis, an observation which Bietti could not confirm. Bardelli found that *Staphylococci* from the hyperæmic conjunctiva of cataract patients after operation, were more virulent than those from a normal conjunctiva. The experiments which I made with De Lieto-Vollaro[2] did not confirm Bardelli's opinion. The possibility that such may be the case cannot be denied, but the virulence varies within narrow limits. Further research on these points is desirable.

LITERATURE

RESPECTING THE ORGANISMS PRESENT ON THE NORMAL CONJUNCTIVA, ESPECIALLY THE XEROSIS BACILLUS.

ACHENBACH, C., Ein Fall von schwerer Xerosis epithelialis usw. Berl. klin. Woch., 1895, S. 517.

ALFIERI, La piu recente questione sulla natura del calazio. Arch. di Ottalm., 1895, XXIV, p. 77.

ALLESSANDRO, Sulla morfologia del bacillo della xerosi. Il policlinico, 1898, VC und Arch. di Ottalm., 1898, VI, p. 145.

AXENFELD, Th., Beiträge zur Ätiologie der Bindehautentzündungen. Bericht der ophthalm. Gesellsch. Heidelberg 1896, S. 140.

Do., Über die chronische Diplobazillen-Conjunctivitis. Zentralbl. f. Bakt., 1897, XXI, p. 5.

Do., Wie weit stimmen die sog. Xerosebazillen der Conjunctiva überein mit HOFMANN-LÖFFLERschen Pseudodiphtheriebazillen des Rachens? Berl. klin. Woch., 1898, Nr. 9 u. 24; Ergebnisse von LUBARSCH-OSTERTAG, 1901, VI. Suppl.

Do., Wieweit stimmen die sog. Xerosebazillen mit den HOFMANN-LÖFFLERschen Pseudo-Diphtheriebazillen überein? Berl. klin. Woch., 1898, und Münch. med. Woch., 1902.

Do., 'Bakteriologie des Auges,' 1894-1900, in 'Ergebnissen,' von LUBARSCH-OSTERTAG (Wiesbaden, Bergmann).

BABES, V., Über isoliert färbbare Anteile von Bakterien. Zeitschr. f. Hyg., 1889, V, S. 177.

[1] This is not an increase in virulence in the sense of producing a diphtheritic action.

[2] *Arch. di Ottal.*, 1905, xii.

BACH, L., Über den Keimgehalt des Bindehautsackes, dessen natürliche und künstliche Beeinflussung usw. v. GRAEFES Arch. f. Ophthalm., 1894, XL, 3, S. 130.

BACH und NEUMANN, R., Die eitrige Keratitis beim Menschen. Eine bakteriologische und klinische Studie. Arch. f. Augenheilk., 1897, XXXIV, S. 267.

BARDELLI, L., Sulla sterilisazzione del sacco congiuntivale. Ann. di Ottalm., 1896, XXV, p. 48.

BAUMGARTEN, P., Lehrbuch der patholog. Mykologie. Braunschweig, 1890, II, p. 721 ff.

Do., Jahresbericht über die Fortschritte in der Lehre von den pathogenen Mikroorganismen. 1886, Bd. II, S. 283. Randbemerkung Nr. 396 u. S. 286, Randbemerkung Nr. 400.

BEHRING, Bibliothek v. Coler, 1901 (Diphtherie), Bd. II.

BERGEY, ref. Zentralbl. f. Bakt., 1898.

BEZOLD, Keratomalacie nach Morbillen. Berl. klin. Woch., 1874, Nr. 33.

BERNHEIM, Über die Antisepsis des Bindehautsackes usw. DEUTSCHMANNS Beiträge z. Augenheilk., 1893, S. 61.

BIETTI, Diphtheriebaz. u. einfache Conjunctivitis. Klin. Monatsbl. f. A., 1903, Beil.

BLAGOWESCHENSKI, Zur Frage über die Aseptik der normalen Bindehaut. J. A. Petersburg, 1895. Ref. MICHEL-NAGELS Jahresberichte, 1895, S. 288.

BRAND, C., Über die Bakterien des Lidrandes und Bindehautsackes usw. Verhandl. der physik.-med. Gesellschaft z. Würzburg. N. F., XXIX., Nr. 5.

BRAUNSCHWEIG, P., Zur Kenntnis der infantilen Xerosis conjunctivae. Fortschr. d. Med., 1890, VIII, S. 889.

BRIEGER, L., und FRÄNKEL, C., Untersuchungen über Bakteriengifte. Berl. klin. Woch., 1890, Nr. 11, S. 241.

CAZALIS, C. A., Étude bactériologique sur la conjonctivite granuleuse. Thèse de Montpellier, 1896.

CIRINCIONE, Ricerche batteriol. ed anat. sulla Xerosis conjuntivale. Ann. di Ottalm., 1891, XIX.

COPPEZ, H., Des conjonctivites pseudomembraneuses. Histoire, Formes cliniques, Traitement. Bruxelles, H. Lamertin. 1897.

CUÉNOD, Bactériologie clinique de la conjonctive. Gazette des Hôpitaux, 1894, p. 990.

DALEN, Bakt. d. Conj. Hygiea I. 1899, p. 326.

DEMARIA, Mischinfektion von Tuberkulose und Pseudodiphtheriebaz. Klin. Monatsbl. f. A., 1905, Beilage.

DENK, Beiträge z. d. mykot. Erkrankungen des Auges. Inaug.-Diss. München 1880. Ref. Zentralbl. f. Bakt., 1887, I. S. 183.

DENNI, Journ. of Med. Research, 1903, IX, p. 118.

DEUCHER, P., Zur klinischen Diagnose der Diphtherie. Korrespondenzbl. f. schweizer. Ärzte, 1895, Nr. 61.

DEYL, J., Über die Ätiologie des Chalazion. Verhandl. der böhm. Akademie der Wissenschaften, Prag. 1893.

Do., Über einige Entzündungen der Augenlider. Ibidem, 1893 94.

DOETSCH, Arch. f. Ophth., 1899, XLIX, 2, S. 405.

DORET, Recherches expér. sur la virulence du zérobacille. Thèse de Genève, 1904.

ELSCHNIG, Diphtherie der Bindehaut. Wien. med. Wochenschr., 1893, S. 1526.

ERNST, P., Über den Bacillus Xerosis und seine Sporenbildung. Zeitschr. f. Hygien., 1888, IV, S. 25.

Do., Über Kern- und Sporenbildung in Bakterien. Ebd., 1889, V, S. 428.

ESCHERICH, Th., Zur Frage des Pseudodiphtheriebacillus und der diagnostischen Bedeutung des LÖFFLERschen Bacillus. Berl. klin. Wochenschr., 1893, p. 492.

Do., Ätiologie und Pathogenese der epidemischen Diphtherie. I. Der Diphtheriebacillus. Wien, 1894, Alfred Hölder.

EYRE, The Xerosis Bacillus. The Lancet, December 21, 1895, and the Journal of Pathology and Bacteriology, July, 1896. Rev. Ophthalm. Review, August, 1896.

FAGE, A., Conjonctivite pseudomembraneuse; examen bactériologique. Arch. d'ophtalm., 1891, XI, p. 52.

Do., Bacille pseudodiphthérique dans un cas de dacryocystite. Ann. d'oculist., 1896, CXV, p. 55.

FEER, E., Ätiologie u. klinische Beiträge zur Diphtherie. Mitteilungen aus Kliniken u. medizin. Instituten der Schweiz, 1894, I, Nr. 7.

FELSER, Die Mikroorganismen des Conjunctivalsackes und die Asepsis desselben. Wratsch, 1888. 43 u 44 Ref. Zentralbl. f. Bakt., 1889, V, S. 321.

FERNANDEZ, S., Los microbios del ojo en estado fisiologico. Cronica medico-quirurgica de la Habana, 1891, Nr. 3. Ref.: Zentralbl. f. Bakt., 1892, XI, S. 472.

FICK, E., Über Mikroorganismen im Conjunctivalsack. Wiesbaden, 1897, J. F. Bergmann.

FLÜGGE, Die Mikroorganismen. Leipzig, 1896, F. C. W. Vogel, S. 476 ff.

FOOTE, Bact. of the norm. Conj. sac. Med. Rec., 1896, ref. Zentr. Bl., S. 661.

FRÄNKEL, C., Über das Vorkommen des LÖFFLERschen Bacillus. Berl. klin. Wochenschr., 1893, S. 252; 1897, Nr. 50.

Do., Zur Unterscheidung des echten und falschen Diphtheriebacillus. Hygien. Rundschau, 1896, VII, S. 977.

FRÄNKEL, E., und E. FRANKE, Über den Xerosebacillus und seine ätiologische Bedeutung. Arch. f. A., 1887, XVII, S. 176.

FRANKE, E., Über den Xerosebacillus und seine ätiologische Bedeutung. Tagbl. der 59. Versammlung deutscher Naturforscher u. Arzte, 1886, S. 223.

Do., Untersuchungen über die Desinfektion des Bindehautsackes nebst Bemerkungen z. Bakteriol. desselben. v. GRAEFES Arch. f. Ophthalm., 1893, XXXIX, 3, S. 1; Münch. med. Wochenschr., 1898, Nr. 16.

FRYER, Amer. Journ. of Ophth., January, 1905.

GALLENGA, Osservazioni di Bacteriologia. Ann. di Ottalm., 1886, XV, p. 441 und Brevi osservazioni sulla Xerosis e sui microorganismi. Rep. of the Italian Ophth. Soc. at Turin, 1887, Ann. di Ottalm., XXI.

GASPARRINI, E., Sui microorganismi della congiuntiva allo stato normale. Ann. di Ottalm., XXII, 6, p. 488.

GAYET, Recherches expérimentales sur l'antisepsie et l'asepsie oculaire. Arch. d'ophtalm., 1887, VII, p. 385.

GELPKE, Th., Der akute epidemische Schwellungskatarrh und sein Erreger (Bacillus septatus). v. GRAEFES Arch. f. Ophthalm., 1896, XLII, S. 97, and preliminary communication to the Heidelberger ophthalm. Gesellsch., 1896, S. 191, and Monographie Karlsruhe, 1898 (B. Septatus and its relation to the Diphtheria Bacteria).

VAN GENDEREN-STORT, A. G. H., Über die mechan. Bedeutung der natürl. Irrigation des Auges. Arch. f. Hygien., 1891, XIII, S. 395.

GERKE und KAIN, Ein Fall von Croup der Bindehaut, der Mund- und Rachenschleimhaut. Arch. f. A., 1892, XXIV, S. 305.

GIFFORD, H., Über das Vorkommen von Mikroorganismen bei Conjunctivitis eczematosa und anderen Zuständen der Bindehaut und Cornea. Arch. f. A., 1886, XVI, S. 197, also Arch. f. A., 1899, XXXIX, S. 106, and Journ. of the Amer. Med. Assoc., October 3, 1903.

GLÜCKSMANN, Zeitschr. f. Hyg. u. Inf., 1897, Bd. 26.
GOLGI, Ricerche batter. sulla xerosis della conj. sulla panophthalmia, Pavia, 1887.
GOMBERT, V., Der FRÄNKELsche Diplococcus als häufiger Erreger des akuten Bindehautkatarrhs. Arch. f. A., 1897, XXIV, S. 134.
Do., Recherches expérimentales sur les microbes des conjonctives à l'état normal. Thèse de Montpellier, 1899.
GONIN, Revue méd. de la Suisse Romande, 1899, Févr.
GRIFFITH, Thompson Yates Labor. Rep. IV, Liverpool, 1901.
GROMAKOWSKI, Zentralbl. f. Bakt., 1900, XXVIII, S. 142.
GUDER, Ein Beitrag zur Conjunctivitis diphth. und deren Bedeutung in sanitätspolizeilicher Hinsicht. Zeitschr. f. Medizinalbeamte, 1895, Nr. 1. Ref. Zentralbl. f. Bakt., 1895, XVII, S. 482.
GUIBERT, Conjonctivite pseudomembraneuse chronique. Examen bactériologique Arch. d'ophtalm., 1895, XIII, p. 627.
HALA, Chalazionbacillus und seine Beziehung zu den Korynebakterien. Zeitschr. f. A., 1901, Nov.
Do., Einheitlichkeit der Korynebakterien. Ebd., 1903, IX, 2.
HEINERSDORFF, Arch. f. Ophth., 1898, XLVI, S. 1.
HILDEBRAND, Experimentelle Untersuchungen über Antisepsis bei Staroperationen. DEUTSCHMANNS Beiträge z. A., 1893, VIII, S. 33.
v. HIPPEL, Heidelberger ophthalm. Gesellsch., 1896, S. 153 (Diskussion).
HIROTA, Inaug.-Diss., Halle, 1901.
HIRSCHBERG und KRAUSE, Zur Pathologie der ansteckenden Augenkrankheiten. Zentralbl. f. prakt. A., 1881, S. 39 u. S. 270.
HORNER, Gerhards Handbuch der Kinderkrankheiten. 1882, V, 2, S. 335. Ref. Zentralbl. f. Bakt., 1887, I, S. 178.
JACKSON, Ann. of ophth., 1901, Jan.
JAMESON, ibid., 1901, X, p. 1.
KASZTAN, Beitrag zur Frage der Augendiphtherie. Inaug.-Dissert., Würzburg, 1899.
KASTALSKI, Beitrag zur Ätiol. der Panophthalmitis. Westnik oft., 1898, XIV, S. 359.
KNAPP, A., Bacter. diagnosis of diphth. bac. in conjunct. Amer. ophth. Soc., 1904. Journal of Med. Research, 1904, XII, Nr. 4.
KARTULIS, Zur Ätiologie der ägyptischen katarrhal. Conjunctivitis. Zentralbl. f. Bakt., 1887, I, S. 289.
KUCHARSKI, Zur Frage von dem Mikroorganismus des Trachoms. Medizinski Stornik der kaukas. med. Gesellschaft, 1887, Nr. 45. Ref. in d. Arbeit von Shongolowicz.
KUSCHBERT und NEISSER, Zur Pathologie und Ätiologie der Xerosis epithelialis usw. Breslauer ärztl. Zeitschr., 1883, S. 40.
Do., Die Xerosis conjunctivae und ihre Begleiterscheinungen. Deutsche med. Wochenschr., 1884, S. 321.
KUSCHBERT, Tagbl. d. 59. Versammlung deutscher Naturforscher u. Ärzte, 1886, Diskussion S. 223 ff.
LACHOWICZ, S., Über die Bakterien im Conjunctivalsacke des gesunden Auges. Arch. f. A., 1895, XXX, S. 256.
LAWSON, The bacteriology of the normal conj. sac. Brit. Med. Journ., June 18, 1898.
LEBER, Th., Über die Xerosis der Bindehaut und die infantile Hornhautverschwärung. v. GRAEFES Arch. f. Ophthalm., 1883, XXIX, 3, S. 225.
LEHMANN-NEUMANN, Atlas und Grundriss der Bakteriologie. Bd. I, Tab. 58-61; II, S. 437 (1904).
LOBANOW, Westnik oftalmol., 1899, März-April; Über Luftinfektion des Auges Sog. Xerosebazillen. Arch. f. Ophth., 1899.

MARTHEN, Experimentelle Untersuchungen über Antisepsis bei Augenoperationen und die Bakteriologie des Conjunctivalsackes. DEUTSCHMANNS Beiträge zur A., 1893, XII, S. 1.

MAZET, C., Sur l'empyème du sac lacrymal (Étude bactériologique et clinique). Thèse de Paris, 1895.

MICHEL, Lehrbuch der Augenheilkunde, 1884, S. 231.

MCKEE, Organisms normally present in the conjunctiva. Montreal Med. Journ., January, 1906; also xiv., 1907, p. 345.

DEL MONTE, Arch. di Ottalm., 1906, XIII, S. 253 and La clin. ocul., 1906, S. 2689.

MONTI, A., Ricerche batteriolog. sulla xerosis congiuntivale e sulla panoftalmia. Arch. per le scienze med., XI, 4.

MORAX, Recherches bactériologiques sur l'étiologie des conjonctivites aiguës et sur l'asepsie oculaire. Thèse de Paris, 1894; Ann. d'oculist., 1894, CXII; Ann. d'oculist., 1895, CXIII, p. 238; ibid., 1896, CXV, p. 55; 1898, CXX, p. 161.

MORITZ, G., Zur Kenntnis der Conjunctivitis fibrinosa. DEUTSCHMANNS Beiträge zur A., 1893, IX, S. 47, and I. D. Leipzig, 1893.

NEISSER, A., Versuche über die Sporenbildung bei Xerosebazillen usw. Zeitschr. f. Hygien, 1888, IV, S. 165.

NEISSER, M., Zur Differentialdiagnose d. Diphtheriebaz. Ibid., 1897, XXIV, S. 443.

OERTZEN, Pneumokokken auf der normalen Bindehaut. Klin. Monatsbl. f. A., 1899, S. 432.

PES, D., Über die Ätiologie und Therapie einiger Formen von Conjunctivitis pseudomembranosa. Klinischer und bakteriologischer Beitrag. Arch. f. A., XXXII, S. 33; Giornale della R. Acad. di Torino, 1897, LX, p. 85; 1899, Clin. oc. di Torino. Ann. di Ottalm., XXVIII.

PETERS, A., Über das Verhältnis der Xerosebazillen zu den Diphtheriebazillen usw. Deutsch. med. Wochenschr., 1897, S. 133

PETRESCO, Sur la nature microbienne des granulations conjonctivales. Ann. d'oculist., 1888, XCIX, p. 212.

PICHLER, Zur Frage der diphtheritischen Bindehautentzündung. DEUTSCHMANNS Beiträge zur A., 1896, XXIV, S. 1.

PLAUT u. v. ZELEWSKI, Bakteriengehalt der Bindehaut nach der Tränensackexstirpation. Klin. Monatsbl. f. A., 1901.

PUCCIONI, L'antisepsi in chirurgia oculare col permanganato di potassio. La reform. med., 1895, Nr. 133. Ref., Arch. die Ottalm., 1895, XXIV, p. 135.

RANDOLPH, Arch. of ophth., XXVI, Nr. 23, Johns Hopkins Hosp. Bulletin, 1903, S. 57.

REYMOND and COLOMIATTI, Congresso internationale d'oftalmologia in Milano, 1880. Ref.: Zentralbl. f. Bakt., 1887, I, S. 177.

REYMOND, C., Dei rapporti del Xerosis epitheliale della congiuntiva col sebo meibomiano. Communic. fatte alla Accad. di med. di Torino, 1883.

RYMOWICZ, Bakteriensymbiose bei Conjunctivalinfektionen. Postemp. ok., 1901, Nr. 6.

SATTLER, Sitzungsbericht der Heidelb. ophthalm. Gesellsch., 1883, Diskussion, S. 197.

SCHANZ, F., Bakteriologische Befunde bei zwei Fällen von infantiler Xerosis mit Keratomalacie usw. Arch. f. A., 1892, XXIV, S. 110.

Do., Die Bedeutung des sogen. Xerosebazillus bei der Diagnose der Diphtherie. Berl. klin. Wochenschr., 1896, S. 250; 1897, Nr. 3 and Nr. 51; Deutsch. med. Wochenschr., 1899, Nr. 3; Zeitschr. f. Hygien. u. Inf. Krkhtn., 1899, XXXII, S. 435; Münch. med. Wochenschr., 1902; Berl. klin. Wochenschr., 1901, Nr. 16.

SCHIRMER, O., Zum klin. Bilde der Diphtheriebazillenconjunctivitis. Arch. f. Ophthalm., 1894, XL, 5, S. 160, and Münch. med. Wochenschr., 1894.

SCHLEICH, Sitzungsber. der Heidelb. ophthalm. Gesellsch., 1883, Diskussion, S. 199.
Do., Zur Xerosis conjunctivae. Mitteilungen aus der ophthalm. Klinik in Tübingen, 1890, II, 1, S. 145.
SCHMIDT, E., Über die Mikroorganismen bei Trachom und einigen anderen mykotischen Krankheiten der Bindehaut des Auges. Inaug. Diss., Petersburg, 1887. Ref. in der Arbeit v. SHONGOLOWICZ.
SCHREIBER, K., Über die Bedeutung der sogen. Xerosebazillen. Fortschritte der Medizin, 1888, VI, S. 650.
SCHULZ, Beitrag zur Lehre von der 'Xerosis conjunctivae und der infantilen Hornhautverschwärung.' Arch. f. Ophthalm., 1884, XXV, 4, S. 123.
SCHWEINITZ, Postoperative Panophthalmie. Ann. d'ocul., CXIV, 18.
SCHWONER, Spezifische Agglutination bei Diphtherie- und Pseudodiphtheriebazillen. Wien. klin. Wochenschr., 1902, S. 1275.
SHONGOLOWICZ, P., Zur Frage von den Mikroorganismen des Trachoms. St. Petersburger med. Wochenschr., 1890, XV, N. F. VII, S. 247.
DE SIMONI, Zentralbl. f. Bakt., 1899 and 1900, XXIX, S. 672.
SMITH, DORLAND, Arch. of ophth., 1905 and 1906, XXXIV and XXXV.
SOURDILLE, G., Etude clinique, bactériologique et thérapeutique sur la diphthérie oculaire. Arch. d'ophth., 1893, XIII, p. 762.
SPRONK, C. H. H., Über die vermeintlichen schwachvirulenten Diphtheriebazillen des Conjunctivalsacks usw. Deutsch. med. Wochenschr., 1896, S. 571.
STADERINI, Gli Mikroorganismi della congiuntiva allo stato normale. Ann. di Ottalm., XXII, Fasc. 6.
STROSCHEIN, E., Die Aseptik bei Augenoperationen in der Würzburger Universitäts-Augenklinik. Arch. f. Ophth., 1893, XXXIX, 1, S. 256.
TERSON, Sur le diagnostic bactériologique précoce de la diphthérie oculaire. Ref. Revue générale d'ophthalm., 1895, p. 209.
TERTSCH, Ein Beitrag zu den dem Diphtheriebacillus ähnlichen Stäbchen des Conjunctivalsacks. Zeitschr. f. A., 1904, XII, S. 621.
TROUSSEAU, M., Étude sur l'antisepsie oculaire. Ann. d'oculist., 1894, CXI, p. 433.
UHTHOFF, W., Ein Beitrag zur Hemeralopie und zur Xerosis conjunctivae epithelialis. Berl. klin. Wochenschr., 1890, S. 630.
Do., Über einige bemerkenswerte Fälle von Augenerkrankungen. 1. Fall von Conjunctivitis crouposa mit schnellem günstigem Verlauf, bakteriolog. Nachweis virulenter Diphtheriebazillen. Berl. klin. Wochenschr., 1893, S. 251.
Do., Neuere Forschungen über die Bakteriologie der äusseren Augenkrankheiten. Sammlung zwangloser Abhandlungen, 1897 (Marhold).
Do., Ein weiterer Beitrag zur Conjunctivitis diphtherica. Berl. klin. Wochenschr., 1894, S. 771.
VOSSIUS, A., Die croupöse Conjunctivitis und ihre Beziehung zur Diphtherie. Sammlung zwangloser Abhandl. aus dem Gebiet der Augenheilk. 1896, Heft 1.
WEEKS, J. E., Xerosis conjunctivae. Arch. f. A., 1887, XVII, S. 193.
Do., Der Bacillus des akuten Bindehautkatarrhs. v. GRAEFES Arch. f. A., 1887, XVII, S. 318.
Do., Bakteriologische Untersuchungen über die in der Augenheilkunde gebrauchten Antiseptica. Arch. f. A., 1889, XIX, S. 107.
WIDMARK, Bakteriolog. Studien über Dakryocyst., Hypop. Kerat., Blepharaden. Hygiea, 1895, Okt.
WOLKOWITSCH, E., Beitrag zur Bakteriologie der gesunden Augenbindehaut. Wratsch, 1897, Nr. 17, S. 485, and Nr. 18, S. 523.
ZARNIKO, Zur Kenntnis des Diphtheriebacillus. Zentralbl. f. Bakt., 1889, VI, S. 153.

General Infection arising from the Normal Conjunctiva.

The Bacteria washed away from the conjunctiva by the tears come in contact with the mucous membrane of the nose and pharynx. A path of infection is thus supplied for many organisms. Certain experiments on animals have shown that a fatal infection may arise from the normal conjunctiva, though it certainly does not occur in the manner stated by De Bono and Frisco,[1] who affirmed that *B. pyocyaneus* or *prodigiosus* (both so-called saprophytes), *B. anthracis*, the tubercle bacillus, and *Staphylococcus pyogenes aureus*, could find their way directly through the intact conjunctiva into the globe, the orbital tissues, or the ethmoid cells. They arrived at this conclusion from operations involving the extirpation of the lacrymal sac, or the obliteration of the canaliculi.

Stock,[2] using the most careful technique, was absolutely unable to confirm these striking assertions. We certainly can exclude the possibility of any passage of organisms from the normal conjunctiva into the healthy globe. The epithelium is a certain protection, and Bacteria can only penetrate it when it has become affected by inflammation or such like.

Römer,[3] to whom we owe a thorough examination of this subject, could only find a direct penetration of organisms into the conjunctiva when mechanical or chemical damage had been done to the epithelium. Mayer,[4] Hirota,[5] Hertel[6] came to the same conclusion.

The organisms of plague (German Plague Commission), anthrax, mouse septicæmia, chicken cholera, the *Pneumococci*, the organisms of mouse typhoid, glanders, "psittacosis Nocard," tuberculosis, tetanus, hydrophobia, the pseudo-tubercular bacillus of Pfeiffer[7] (Deyl), Ribbert's bacillus of gastric diphtheria[8] (Braunschweig, Conte, Römer, Hertel, Mayer, Hirota), very readily produce a general infection in white mice and rats, less readily in guinea-pigs and rabbits. If a small quantity, *e.g.*, of plague organisms is introduced into the conjunctiva, death

[1] 'Sulla permeabilita verso i microorganismo delle mucose congiuntival e nasale intatte in raporto alle infezioni endoculari' (*Arch. di Ottal.*, viii., p. 401).

[2] 'Über Infektion vom Conjunctivalsack und von der Nase aus' (*K. M. f. A.*, 1902, S. 16).

[3] 'Experimentelle Untersuchungen über Infektion vom Conjunctivalsack aus' (*Zeit. f. Hyg. u. Inf.*, xxxii., 18, S. 285).

[4] 'Zur Kenntnis der Infektion vom Conjunctivalsack aus' (*Wien. Med. Woch.*, 1901, No. 9).

[5] 'Über die Infektion vom unverletzten Bindehautsacke aus' (*Zent. f. Bakt.*, xxxi., Heft 6, S. 190).

[6] Report from the *Kaiserl. Gesundheitsamt*, 1904, xx., S. 3.

[7] 'Experimental Research concerning Pseudo-tuberculosis, especially in the Eye' (Prag Acad. des Sc. de l'Empereur François Joseph I., 1894).

[8] *Forts h. d. Med.*, 1889, S. 809.

THE ASIATIC SOCIETY OF BOMBAY LIBRARY

soon occurs. This results, however, from their passage through the lymph channels of the nose and throat. This latter site was shown by Ribbert to have been the entering point of a streptococcal infection. If we are to judge by the action of carmine dropped into the sac, the invasion of the Bacteria begins in the lower part of the nasal duct. When the canaliculi are closed, no general infection occurs.

We find a similar state of affairs in man. The smallest lesions under certain circumstances are sufficient, so that clinically the conjunctiva may appear very slightly affected, and may rapidly return to the normal, even in cases where it has been the point of entrance of a general infection. Nicolle and Dubois[1] obtained swelling of the pre-auricular gland (which cannot be due to any nasal condition) in glanders after the material infected with glanders had been introduced into the conjunctiva, which itself showed no special changes.

The conditions may vary in different Bacteria as regards the human subject. It is quite impossible, however, for organisms to pass into the interior of the healthy globe from the intact conjunctiva of the human eye.

Pathogenic Protozoa can also cause general infection from the conjunctival sac. This has been recorded by Stargardt in the case of the *Trypanosoma evansii*, the cause of surra (in horses), by Römer, with *Tr. gambiensi*, the cause of sleeping sickness ('Ophth. Congr. Heidel.,' 1906, SS. 317 and 325).

The same thing may be possible in human beings with the organisms already mentioned. A severe general infection from the conjunctiva has only been observed in the case of acute streptococcal infection (see p. 205). In pneumococcal cases and pyogenic staphylococcal cases we may thus explain the slight rise in temperature, which also occurs in Koch-Weeks cases. The general symptoms in true (Löffler's) diphtheria of the conjunctiva are mostly toxic. For further information see chapter on 'Conjunctivitis.'

[1] *Presse Médicale*, 1902, p. 977.

CHAPTER III

THE LIDS

THE bacteriology of the lids is the same as that of the surrounding skin.[1] Normally staphylococci are present, especially the white variety, having little or no power to liquefy gelatine or produce an inflammatory reaction—the same *Staphylococcus albus epidermidis* we have already noted in the conjunctival sac. The majority of the cocci present are closely related to the *Micrococcus candicans* (see 'Normal Conjunctiva').

There are very few records available relating to methodical examination of the lids, and these require supplementing by larger series. Terson and Cuénod[2] examined twenty normal lids in Panas' laboratory. The white *Staphylococci* obtained only once produced a severe purulent keratitis. On every other occasion the infiltrate at the site of inoculation healed up rapidly and spontaneously. The name *petit abcès*, which Cuénod gave to this reaction, cannot be recommended. It is doubtful whether a rise in virulence may not occur (*cf.* p. 60), and whether the action does not differ in the human cornea.

M. Neisser and Wechsberg considered that pathogenic *Staphylococci* are specially characterized by a hæmolytic function. In the case of five white *Staphylococci*, grown on blood media from the skin, such was absent, and the regularity and constancy of this phenomenon is still to be demonstrated. I regularly obtained a hæmolysis with six strains of white *Staphylococci* obtained from the normal conjunctiva, only one of which had definite pyogenic properties. Gallenga, Gifford, Bach, Brandt[3] have all found these *Staphylococci;* my own findings also are similar.

Yellow *Staphylococci* are rarer, but still are more common than on the conjunctiva; these yellow cocci, though of low virulence, generally are definitely pyogenic.

Virulent bacilli of the diphtheria group are often found on the skin; at the lid margins they regularly occur in large numbers.

Cuénod and Terson only succeeded in cultivating such bacilli once in twenty cases, but they worked with blood-serum, besides which the platinum loop (which

[1] *Cf.* Gotschlich, 'Handb. v. Kolle u. Wass.,' 1903, Bd. i., S. 147, 'Bakterienflora der normalen Haut.'

[2] *Thèse de Paris*, 1894, 'Bact. et Parasit. des Paupières.'

[3] Inaug. Dissert., Würzburg, 1895. Compare here the literature.

they used) does not take up sufficient material. Xerose bacilli will generally be obtained if we scrape the skin rather firmly near the lid margins. Further away from the eye their number, relative to the cocci, diminishes, but they never entirely disappear.

Though *Staphylococci* and xerose bacilli are the only constant inhabitants of the normal lid margins, all kinds of organisms can occur as accidental contaminations; they have been observed in single cases, but not in large series, and are of very little interest. Cuénod definitely states that the other organisms which he found were not pathogenic. Micro-organisms forming chains have never been observed on the skin of the normal lids.

To give a comparison with the rest of the skin, I will epitomize a paper of recent date:

Süpfle (*Zentr. f. Bakt.*, Orig., xlii., 1906, S. 304) found that the normal external ear, like the rest of the skin, almost always contained large numbers of white *Staphylococci*, both liquefying and non-liquefying, which were either identical with, or closely related to, the *Micrococcus candicans*. They were never virulent. *Sarcinæ*, in small numbers, occurred frequently. Pseudo-diphtheria bacilli were very common, especially when there was much wax present (corresponding to the prevalence of *B. xerosis* in the Meibomian secretion and fatty degenerated epithelial cells). Other bacteria, *Micrococci*, *Staph. pyog. aureus*, and other yellow cocci (*Micr. luteus*, *sulfureus*, *aurantiacus*), various bacilli, and moulds, were in comparison very rare, so that in general it could be said that only harmless organisms were present. *Streptococci* and *Pneumococci* were never found.

The great similarity of these results with those found in the conjunctiva is obvious.

The organisms mentioned are situated in the superficial layers of the conjunctiva, in the pores, the mouths of the glands and hair follicles, also on the hairs (Strohschein, L. Müller, v. Pflugk, Gifford, Herzog). In the hair follicles they only penetrate down to the bottom of the ampullæ (Herzog).

The presence of these saprophytes and non-virulent organisms naturally complicates the bacteriology from an etiological point of view. They have been the cause of mistakes in dermatology, as in ophthalmology, and must therefore be carefully noted in the bacteriology of the lids.

Blepharitis.

The mildest form of blepharitis, the **hyperæmia marginalis** or **blepharitis squamosa**, is hardly a primarily infective condition. The slight formation of scales, without pustules or ulceration, corresponds to dandruff formation in the scalp, and is caused by a dry seborrhœa. This is confirmed by the bacteriology of the condition.

Cuénod,[1] who has paid particular attention to lid bacteriology, in thirty cases found large numbers of non-pyogenic *Staphylococcus albus*, often in pure culture, and besides these only scattered examples of non-pathogenic cocci and bacilli of various species. The only difference from the normal lids was that the number of colonies was greater and their development freer; they were not, however, pathogenic for the rabbit's cornea. Along with these we occasionally find yellow cocci, which are only sometimes virulent. Bayersdorfer[2] came to a similar negative conclusion.

Burchardt cannot be supported when he states that the connexion between *Staphylococci* and blepharitis is so intimate that he can diagnose 'latent lid eczema' merely from the presence of these organisms, without any other changes.

The slight importance of the presence of *Staphylococci* is shown by the fact that they also occur in comedones. Cuénod found them also in milium. Those cases, too, where the skin and margins of the lids are affected with acne rosacea cannot be considered as primary.

The occurrence of hyperæmia and seborrhœa of the lid margins is due to a combination of various influences—anæmia, scrofula, irritation by dust, puberty, the menopause, eye-strain, uncorrected errors of refraction, etc.

The lid margins participate in inflammations of the conjunctiva. Herzog considers that the increased secretion of fluids is the cause of this. Röder and Truc[3] lay too much stress on lacrymal affections.

It is possible that this seborrhœa prepares the way for the true lid inflammation by blocking up the mouths of the sebaceous glands. Such a condition is well known to have considerable influence on the determination of acne vulgaris.

Eczema.

An acute eczema of the lids is just the same as an eczema elsewhere. A moot question will be discussed in the chapter on 'Scrofulous Inflammation,' as to whether the inflammation is to be ascribed to the presence of Bacteria, especially *Staph. pyog. aureus* (Unna, etc.), or whether this organism is only a chance contamination (almost invariable), which influences the latter course of the disease (*cf.* p. 234). Straub has paid special attention to eczema of the lids in scrofulous subjects, and found large numbers of *Staph. aureus*. The almost

[1] 'Bact. et Parasit. Clin. des Paupières,' *Thèse de Paris*, 1894.
[2] Quoted by Derby, Amer. Ophth. Congress, 1906.
[3] Truc, *Rec. d'Ophth.*, 1897, p. 575; Röder, *K. M. f. A.*, 1887, S. 261.

invariable presence of this organism in acute eczema has been demonstrated, from the dermatologist's point of view, by Scholz. Herzog[1] takes the intermediate view, and regards the *Staphylococci* as causal in many cases of eczema where there is a disposition, and only as secondary in the other cases.

The presence of pus-forming cocci in large numbers is a characteristic of *impetiginous eczema ; Streptococci* also are very often present.

Impetigo contagiosa[2] sometimes occurs on the lids, and in the fresh eruptions we find large numbers of *Streptococci*,[3] less commonly pyogenic *Staphylococci*.[4] Terson considered that the *Streptococci* were primary, and that the *Staphylococci* were a contamination which persisted after scabbing occurs.

Kolle and Hetsch[5] consider that there is not sufficient proof that the pus-forming cocci are really the cause; some unknown specific germ may be the cause of its transmission.

Blepharitis Ulcerosa.

When a suppurative ulceration develops at the lid margins, either as a primary condition or as the result of a simple seborrhœa, then the etiological bacteriological problem becomes of considerable importance, although in the course of the affection the general health of the patient and the condition of the nidus is even of greater interest.

In searching for cases parallel in their dermatology, we meet with the difficulty that these lid changes are not thoroughly understood. Horner and Von Michel[6] were at great pains to introduce a dermatological classification for diseases of the lids, and considered that blepharitis ulcerosa was actually an eczema with excessive secretion ; this in hairy regions affects the mouths of the follicles, settling in them and causing the hairs to fall out. Infection, pustules, and chronic infiltration followed. Michel's pupil Herzog[7] has recently given expression to the same views. According to him, the ulceration and abscess formation imply partly an impetigo of the hair follicles, partly a *folliculitis suppurativa externa* or *interna*, or else a combination of these produced by the eczema of the skin.[8]

[1] *Zeit. f. A.*, 1904, xi., S. 163.
[2] *Cf.* Moberg, *Münch. Med. Woch.*, 1905, S. 2095.
[3] Kurth, *Arbeiten des Kaiserl. Gesundheitsamtes*, vii., p. 389.
[4] Kaufmann, *Arch. f. Dermat. u. Syph.*, xlix., 2-3.
[5] 'Handb. Kol. u. Wass.,' Bd. iii., 1903, S. 903.
[6] 'Handb. der Augen. von Graefe-Saemisch,' 1 Aufl., Liderkrankungen.
[7] *Zeit. f. Aug.*, 1904, xii., S. 151 *et seq.*
[8] Since Mulder (*Neederl. Tijds. v. Geneesk*, 1899, ii., p., 803), Hunsche (*Münch. Med. Woch.*, 1900, S. 1563), and Jörss (*Deutsche Med. Woch.*, 1899, No. 1), have proved it to be quite as frequently present under normal conditions, the saprophytic *Acarus folliculorum*, described by Rählmann (*K. M. f. A.*, 1899, xxxvii., S. 33) and Snellen, jun. (*Neederl. Oogh. Bijdr*, 1899, viii., p. 85), as the cause of blepharitis, has lost this attributed etiology. Oyenard came to the same result ('El Desmodex Folliculorum en los Parpados Tesis,' 1907, Buenos Ayres). Herzog (*K. M. f. A.*, 1904, i., S. 177) granted that it favoured the entrance of cocci by preparing the way. Majocchi and Burckardt found *Acari* in chalazion.

On the other hand, the affection of the hair follicles, with the formation in them of small abscesses, strikes one so forcibly that the disease reminds one strongly of an acne of some hairy region, of a sycosis simplex[1] ('sycosis staphylogenes,' Herzog). Many cases of blepharitis are of this nature, especially those where a typical sycosis of the beard is present. Clinically, those forms of blepharitis which begin in the hair follicles cannot with certainty be distinguished from the eczematous forms, especially in their later stages. Herzog agrees with Unna in wishing to reserve the name 'acne' for those cases where the gland ducts are blocked by a hyperkeratosis, and suppuration then occurs through the growth of organisms. He reserves the expression 'superficial or deep furuncle' for those cases occurring independently of the formation of comedones. The isolated hordeolum usually belongs to the latter group, as do the cases referred to later. Widmark,[2] Leber and Sattler,[3] and Gallenga,[4] were the earliest investigators of ulcerative blepharitis, also Deyl,[5] Burchard,[6] Gifford,[7] Weeks,[8] Straub,[9] Morax,[10] Bach,[11] Terson and Cuénod,[12] Bayersdorfer, Herzog,[13] and Duane,[14] have worked out this subject.

Aureus was usually met with. In twelve cases from the bead of pus occurring under the crust, Cuénod obtained *aureus* pure eight times, mixed with *Staphylococcus albus* twice, and *Staphylococcus albus* pure twice. The *aureus* was always very pyogenic in the rabbit's cornea, the *albus* only slightly so. In ten other cases direct inoculation from the crusts always produced yellow cocci; their virulence was not tested.

Bayersdorfer always got *aureus* from blepharitis ulcerosa. Straub had the same result in ulcerative eczema of scrofulous patients. Personally, I have regularly obtained the *aureus* in marginal pustules of the lid.

Herzog's findings agree; the *Staphylococci* which he obtained very often showed a double form and varied greatly in size. The *Diplococcus albicans* which he grew from one or two cases is very closely related to the white non-liquefying *Staphylococcus*, but has a low pathogenicity.

He obtained *Staphylococcus albus* in a patient with sycosis staphylogenes of the beard and eyelashes. (Herzog differentiates sycosis simplex from sycosis parasitica (herpes tonsurans) by the fact that in the latter the hairs break off and in the former they completely disappear.

[1] Winselmann (*K. M. f. A.*, 1902, xl., ii., p. 393) considers blepharitis ulcerosa as a primary sycosis.
[2] *Hygiea*, 1885. p. 581; *Beiträge z. A.*, 1891, Leipzig, bei Veit u. Co.
[3] 'Die Bedeutung der Bakteriologie in der Augenheilkunde' (Internationaler Ophthalmologenkongress in Heidelberg, 1889).
[4] Ital. Ophth. Kongr. Genua, 1886 (*Ann. di Ottal.*, 1887).
[5] 'Über einige Entzündungen der Augenlider' (Böhmische Akademie d. Wissenschaften, 893-94).
[6] *Zent. f. A.*, 1887, S. 40, and *Dermat. Zeit.*, 1894, i. 4.
[7] *A. f. A.*, 1886, xvi., S. 197.
[8] Amer. Jour. of Dermat., 1905, S. 366.
[9] *A. f. A.*, 1892, xxv., S. 416.
[10] *Thèse de Paris*, 1894.
[11] *A. f. O.*, 1894,, xl., S. 3.
[12] 'Bactériologie des Paupières,' 1894.
[13] *Zeit. f. A.*, 1903, xi., and 1904, xii.
[14] *A. f. O.*, 1906, xxxv., S. 484.

Deyl;[1] following up the experiments of Garrè, rubbed pure cultures of *Staphylococcus pyogenes aureus* into the healthy margins of the lid, and produced hordeola, folliculitis, and eczema. The point of entrance for the pyogenic cocci was obviously the mouths of the glands. The result of this inoculation, however, was not a true eczema, but rather an adenitis, which, under some circumstances, might even develop into a furunculosis.

There are cases where in *the ulcers* and *abscesses* we can only find white *Staphylococci*, causing a transient infiltration of the rabbit's cornea (Cuénod). Unless we presume that there were other organisms present, which escaped recognition, we must conclude that pathogenicity towards animals does not in every case correspond with the effects on man. According to this view, and considering the variable factor of personal disposition, it appears quite possible that even the less virulent cocci under favourable conditions can cause an inflammation.

The irritation of the conjunctiva and the catarrh which accompany a blepharitis partly result from the blepharitis. It is in this kind of case especially that we find large numbers of *Staphylococci* alongside the xerose bacilli.

Similarly a blepharitis can result from either a conjunctivitis or a lacrymal affection. Acute conjunctivitis is rarely the cause; the chronic forms are more commonly so, especially those with lacrymal affections. By far the most common, and in practice the most important, of this group are the diplobacillary infections (see p. 161).[2]

Hyperæmia marginalis, especially when it takes the form of an intertrigo and affects the angles of the lids, is very often solely due to a diplobacillary conjunctivitis, and is cured by zinc. It should be noted that the conjunctival secretion in these cases may be very scanty. When ulceration does develop, *Staphylococci* are found in the pustules, just as in blepharitis ulcerosa; the *Diplobacilli* alone cannot cause follicular suppuration. The cure of the ulceration, nevertheless, is dependent on the removal of the *Diplobacilli*.

The infective diseases of the lids are important in the pathology of the cornea[3] and in wound infection. The forms of superficial keratitis and marginal ulceration associated with them are not yet defined from a bacteriological point of view. It is quite possible that the *Staphylococci* have a great deal to do with these complications, and their form and severity may depend on variations in the virulence of the cocci. Further bacteriological researches are necessary here.

[1] 'Über einige Entzündungen der Augenlider' (Akad. der Wissensch. Franz Joseph I., Prag., 1893-94).

[2] This has been especially emphasized by Macnab (R.L.O.H. Rep., 1905, xvi. p. 307).

[3] *Cf.* Terson, 'Compl. Cornéennes des Bleph.' (*Rev. Gen. d'Oph.*, 1897, No. 6).

Hordeolum, Lid Furuncle, Lid Abscess.

The mild form of hordeolum, and the deeper furuncle of the lid are pyogenic infections of the lid glands of varying severity.

The accompanying Fig. 5 shows a lid furuncle arising in an infected sweat gland. The tubule of the gland and its duct are plugged with a (black) mass of cocci; around is necrosis and inflammatory reaction. The cylindrical column of organisms forms a zoogloea mass, which extends beyond the usual calibre of the tubules. A similar, but more superficial, infection of the skin of the lid, and one arising from the lanugo hairs, is shown in Fig. 6. The hairs have fallen out, and their places are

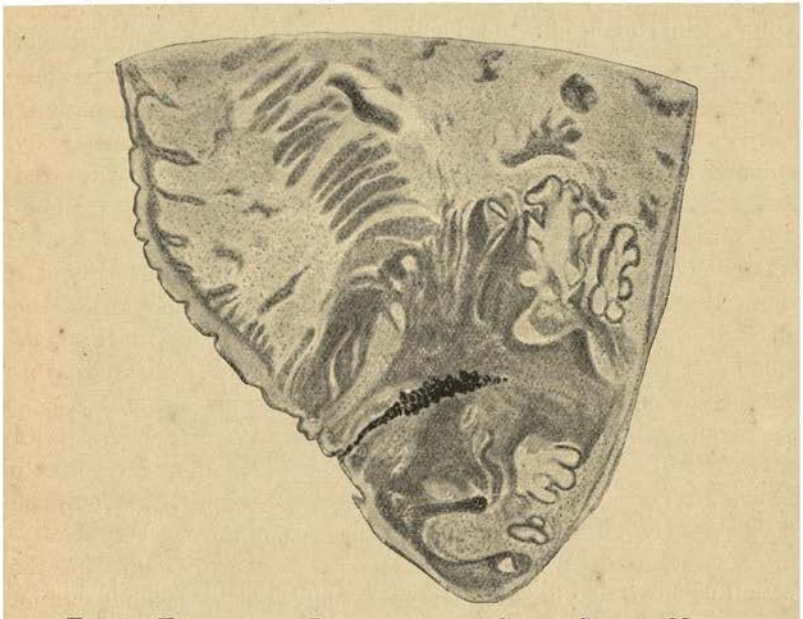

FIG. 5.—FURUNCLE OF LID ARISING IN A SWEAT GLAND. MASS OF ORGANISMS BLACK.

taken in the skin by plugs of cocci, surrounded by unstained necrotic tissue, outside of which is a reaction zone, which finally will cause the separation of a surface slough. Such may be called superficial furuncles.

The surface necrotic area is not usually so extensive as this in a hordeolum. The hair is usually cast off early, as has been microscopically demonstrated by Herzog, who showed that the spread of the cocci was not only along the hair follicle, but that from a folliculitis externa the cocci could break through into the sheath of the hair.

These preparations were obtained from a newly-born child which had inflammatory nodules and pustules of varying size on its face and eyelids, and finally died of streptococcal sepsis.[1] I did not take cultures from the pustules, as that would have

[1] For the intra-ocular condition (hæmorrhages in the retina containing cocci), see Axenfeld, 'Eitrige Metast. Ophth.' (*A. f. O.*, 1894, xl., S. 206).

spoiled this rare preparation. The infection was probably staphylococcal, but *Streptococcus brevis* could not be excluded, even although an infection of the hair bulbs by the latter is so rare.

The typical hordeolum is almost invariably a staphylococcal infection, *aureus* generally being the cause. Any condition which predisposes to furunculosis and acne can also predispose to recurrent hordeola—anæmia, scrofula, diabetes, dyspepsia, convalescence from fevers (measles), etc. Hordeola may be merely incidents in a chronic blepharitis. They have an intimate connexion with blepharitis ulcerosa. Recurrent hordeola, such as follow measles, may be the starting-points of a chronic blepharitis, which leads to a deeper

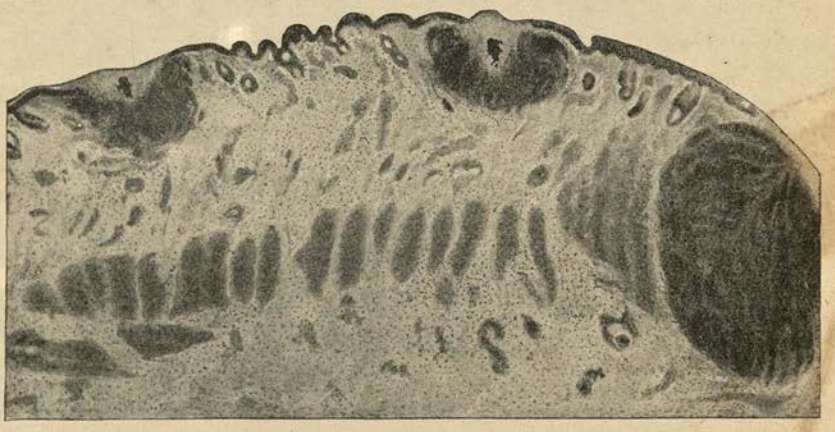

FIG. 6.—ACNE PUSTULES OF LID, WITH CENTRAL MASS OF COCCI (BLACK), ARISING FROM THE LANUGO HAIRS.

infection of the hair follicles. Even the simple squamous blepharitis or seborrhœa can cause the formation of hordeola, which diminish when that condition is treated. Hordeola, sometimes with eczema of the lid, commonly occur when a bandage has been used for a long time. A furuncle of the caruncula lacrymalis is rare, and arises in the glands of the hair follicles. It usually contains *Staphylococci*.

Virulent pyogenic cocci occur in all these cases, so that a contact infection can almost always be excluded. The cocci come from the patients themselves. Seeing that only in a small proportion of the cases can pyogenic *Staphylococci*, usually yellow, be found in or on the normal skin of the lids, it might be supposed that it was only those having these cocci who suffered from hordeola or other staphylococcal skin affections. It is more probable, however, that the avirulent saprophytic cocci of the skin can become virulent, and thus, under predisposing

circumstances, lend to self-infection. The *Staphylococci* vary in virulence, and when, through long cultivation, *aureus* begins to lose its virulence, it can regain it by passage through an animal. Bossalino produced exaltation of virulence in a stem of *aureus* obtained from the conjunctiva in a case of cataract. At first it was only moderately pathogenic for the rabbit's cornea, but after being twice inoculated, a severe purulent infection occurred.

As with the conjunctiva,[1] so here, there is no evidence to justify a generalization that the common skin saprophytes can assume a marked pyogenic character. The experiments of Rupprecht in our laboratory, however, point that way. A. Terson[2] is very emphatic in favour of a transformation of the skin organisms into pyogenic forms; so are Duane and Hastings,[3] the latter quoting Gifford.[4]

Wright's specific vaccine treatment should be carefully considered in chronic staphylococcal affections of the lids. This subject will be fully considered later under the heading 'Opsonic Index.'

The condition known in the literature as a '**lid abscess**'[5] is generally only a severer form of what we have already described as an infected gland, furuncle, or hordeolum. The majority of those cases of Gallenga's[6] which occurred so frequently in the summer of 1904 fall into this class. *Staphylococcus aureus* and *albus* were found in the pus; *Streptococcus* only twice. Pyogenic *Staphylococci* are generally the cause of those circumscribed abscesses which have no special tendency to diffusion. In the case of those more profuse and phlegmonous suppurations which occur after wounds and erysipelas, *Staphylococci*[7] can certainly be found; but the *Streptococci* are more important, just as in the case of the phlegmonous dacryocystitis, in which Widmark has shown the importance of the *Streptococcus pyogenes*.

Lid abscesses have been noted after various general infections, but without definite determination of the organisms present.[8] Frugiuelli[9]

[1] Terson, *Arch. d'Ophth.*, 1893; Gallemaerts, *La Policlinique* (Brux.), September 15, 1897; Richter, *Beiträge z. Aug.*, 1905, S. 63 ('Streptococci').

[2] *Loc. cit.*, p. 455.

[3] New York Med. Jour., May 26, 1906.

[4] *A. f. A.*, 1887, xvi., p. 197.

[5] Fatal septic infection from a hordeolum or lid abscess is very rare (Guth, *Prager Med. Woch.*, 1898, No. 3; Gallemaerts, *l.c.*). I have myself seen a fatal case of thrombosis of the orbit and sinus, due to *Staphylococcus pyogenes aureus*, which arose from a lid furuncle. Lesniowsky described a similar result in a hordeolum.

[6] *La Clinica Oculistica*, October, 1904.

[7] Zia, 'Phleg. Entzund. der Lider u. Gangrän der Bindehaut durch Staphylokokken,' *'Ophth. Kl.,'* 1904, p. 306; Valude, *Ann d'Ocul.*, 1890, C., p. 60.

[8] Bock (*Zent. f. A.*, 1890, p. 508), Landolt (*Semaine Méd.*, 1890, No. 3), and others, after influenza; Jackson (Brit. Med. Jour., March 23, 1895), after scarlet fever. Fuchs ('Text-book,' 1905) reports a lid abscess in blennorrhœa.

[9] *Gaz. Internat. di Medicina Pratica*, 1900, iii. 286.

described a pneumococcal abscess following on a pseudo-membranous conjunctivitis. Gifford found sclerosis alone in some cases (Jour. Amer. Med. Assoc., October, 1903).

Erysipelas.

Erysipelas of the lids, just as elsewhere, is caused by the *Streptococcus pyogenes*. The *Streptococcus erysipelatis* first described by Fehleisen, cannot be definitely distinguished from the *Streptococcus pyogenes*, either microscopically or by cultures, especially as the power of producing suppuration or erysipelas in animals can vary in one and the same strain of the organism.

I am not aware of any special investigations of erysipelas of the eyelids. In cases where recurrent erysipelas arose from an infected lacrymal sac, I found *Streptococcus pyogenes* in the pus from the sac, and Morax, Cuénod, and A. Terson[1] have reported the same. Bacteriological examinations have been made of the less common lid abscess and the still rarer gangrene after erysipelas. Mitvalsky, Cuénod, and Gabriélidès[2] found *Streptococci;* Roger and Weil, on the other hand, found *Staphylococci* (*cf.* p. 63, 'Gangrene'). This latter observation recalls the fact that *Staphylococci* can produce an appearance similar to erysipelas, but without the same infectiousness or peculiar method of spreading.

Erysipelas of the face or eyelids can spread to the orbit and even to the meninges, serum treatment will perhaps be very valuable in such cases.

It may be remembered that, according to Leber, in such cases an erysipelas of the skin may rapidly disappear, and that then the orbital cellulitis is the prominent feature (suppressed erysipelas). No bacteriological examinations of such cases are available, and it is still a question whether or not a suppressed sinus affection was not the original cause. Von Michel[4] found *Streptococcus pyogenes* in the eruption of an impetiginous eczema resembling the bullous form, which developed on an erysipelatous area of skin. Mosetti[3] described a streptococcal suppuration of the lacrymal gland after erysipelas.

Cases where the skin is swollen and there is a suspicion of erysipelas are only differentiated from a commencing eczema with great difficulty. To make a bacteriological examination the margin of the affected area should be carefully cleaned, the skin scarified, and the blood or serum examined for *Streptococci*.

Cuénod holds the view that *Streptococci* remain present in the

[1] 'Maladies des Paupières,' *Encycl. Franç. d'Ophth.*, 1906, p. 399.
[2] 'Ophthalmologie Microbiologique,' 1907, p. 320.
[3] *Ann. di Ottal.*, 1905, xxxiv. 3. [4] *A. f. A.*, 1901, xlii., p. 301.
[5] Cuénod, *Thèse de Paris*, 1894. p. 67.

thickened lids and face after erysipelas, just as Sabouraud[1] found to be the case in similar skin thickenings of other parts of the body. Definite proof of this in the lids has not yet been brought forward.

Gangrene of the Lids.

There is no sharp demarcation line between those infections which cause abscesses of the lids and those inflammatory necroses called in the literature 'gangrene of the lids.' It must be noted that in our literature this name is not only used for that form of decomposition which, as Römer and Morax show, is due to the putrefactive Bacteria, but also as a general term for any inflammatory necrosis of the lid tissues. The bacteriological examinations which have been made in such cases give various results, corresponding to the fact that the necroses can result from various infective agents. The possibility of a specific serum treatment (streptococcal, anthrax, or diphtheritic) gives an importance to their bacteriological differentiation.

Such cases can occur in the course of *general fevers* (influenza, measles, scarlet fever, typhoid, small-pox, chicken-pox, erysipelas, whooping-cough). Joss described an apparently metastatic case after erysipelas. Mitvalsky[2] found *Streptococci*, Roger and Weil[3] found non-liquefying *Staphylococci* in a case of gangrene after erysipelas. Römer found *Streptococci* and *proteus* in gangrene after chicken-pox. Axenfeld described a case of commencing gangrene of all four lids in a streptococcal diphtheria of the conjunctiva after measles, and similar cases have been described clinically by Fieuzal and Knies. Valude and Morax found *Streptococci* in gangrene following on a slight injury to the lids. Pes found *Streptococcus* after the sting of an insect, and *Staphylococcus pyogenes aureus* with *Streptococcus* after a scratch. Possek also found *Streptococcus*.

Other cases may be due to *pyæmic metastases*. The case quoted by Mitvalsky, in which gangrene from *Streptococci* followed endometritis, is certainly of this nature. I have seen and examined microscopically a metastatic lid gangrene from *Staphylococcus pyogenes aureus* in a girl suffering from pyæmia.

Infection by diphtheria bacilli can also cause gangrene of the lids. In a case from Tübingen (Schleich) Steffens and Schillinger found diphtheria bacilli (along with *Staphylococci* and *Streptococci*) in the necrotic tissues of the lid. They emphasized the importance of serum treatment. Mori and Yamanoto record another case of the same kind. Hala,[4] Randall, Kölle, Caspar (quoted by Brons), have described similar suppuration of the lids from diphtheria infection. These

[1] *Ann. de Dermat. et Syph.*, May, 1890. [2] *K. M. f. A.*, December, 1892.
[3] Roger and Weil, 'Gangrène bénigne des Paupières,' *Presse Méd.*, 1901, p. 157.
[4] *Wien. Klin. Rund.*, 1904, No. 49.

cases agree with what we observe in animals on infecting the conjunctiva after scarification with virulent diphtheria organisms, when, after subsidence of the brawny œdema, the hairs fall out and actual gaps occur in the lids. In conjunctival diphtheria, too, the necrotic process and membrane formation can spread past the margins of the lids on to the skin; in such a case Uhthoff and Fränkel found virulent diphtheria organisms in the eczematous pustules of the face which accompanied the eye condition. In the case recorded from my clinic by Plaut the *Staphylococci* and *Streptococci* which he cultivated were only secondary, as the gangrene was due to excessive applications of ice.

Marlow (Ophth. Rec., 1901, p. 626), under the title of 'Noma of the Lids,' described a case of gangrene in a badly-nourished child. He gave no bacteriology, and it must be confessed that the clinical 'noma' is not a bacteriological entity. Wagenmann[1] and Vix[2] only found *Staphylococci*. In Kipp's rare case of *senile lid gangrene*[3] infection was only secondary.

LITERATURE.

Apetz, Münch. med. Woch., 1906, S. 908.

Axenfeld, Gangrän der Lider nach Morbillen. K. M. f. A., 1904, I, S. 576.

Brons, Infektiöse Liderkrankungen, 'Ergebnisse' (Lubarsch-Ostertag), 1900-1905.

Castersana and Goiccecha, Gangr. aller Lider nach Erysipel.; Jahresber., 1904, S. 488.

Elschnig, Gangrän der Lidhaut. K. M. f. A., 1893.

Giulini, Gangrän nach impetiginösem Ekzem. Münch. med. Woch., 1889, S. 401.

Hilbert, Lidhautgangrän bei Kindern. Vierteljahrsschr. f. Dermat. u. Syphilis, 1884, S. 117.

Isola, Gangrene de los parpados postvaricelosa. Arch. de oft. hispano-amer., 1905, Febr.

Kölle, Lidgangrän nach Scharlach mit Conj.-Diphth. Inaug. Diss., Giessen, 1902.

Morax, Necrose et gangrène des paupières. Annales d'ocul. T. 127, p. 143.

Pes, Die akute gangränöse Phlegmone der Lider. Z. f. A., 1904, Bd. XII, S. 438.

Mori and Yamamoto, Lidgangrän mit Diphtheriebazillen. Ophth. Klinik, 1905, S. 119.

Plaut, Lidgangrän durch übertriebene Eisanwendung. K. M. f. A., 1899, S. 35.

Possek, K. M. f. A., 1907, Bd. I, February.

Roger and Weil, La gangrène bénigne des paupières. Pressę Méd., 1901, p. 157.

Römer, Lidgangrän. Halle, 1900, bei Marhold.

Schillinger, Ein weiterer Fall von Lidgangrän mit Diphtheriebazillen. Inaug. Dissert., 1903, Tübingen.

Steffens, Lidgangrän mit Diphtheriebazillenbefund. K. M. f. A., 1900, S. 337.

Valude, Lidgangrän. France Med., January 10, 1890.

Malignant pustule (anthrax, Miltzbrandgangrän, charbon) generally has a different appearance. The usual pustule appears, and rapidly

[1] *Deut. Med. Woch.*, 1901, Vereinsbeil, p. 236. [2] Inaug. Diss., Jena, 1901.
[3] Oph. Rev., 1896, p. 249.

passes into a black spreading slough, frequently surrounded by a ring of superficial vessels.[1] Anthrax rarely begins as a pure œdema.

Anthrax bacilli cannot always be found in the fresh pustules or in the slough; they have often passed into the tissues around, and in the slough we find pyogenic cocci and other Bacteria. The margins of the patch should be scarified, and there the anthrax bacilli will be found during the first few days. Later on it is necessary to examine the blood, and even then we do not always get a positive result. The organisms are readily recognized as spore-forming bacilli, Gram-positive, often segmentally stained, 3 to 10 μ long and 1 to 2 μ broad. They have a clearly staining ectoplasm.

Subcutaneous inoculation in rabbits and mice causes an œdema, rapidly followed by hæmaturia, and death usually occurs. When the virulence is low the animal may survive. Elschnig obtained such attenuated forms from a case of lid anthrax. Buy since obtained the *B. anthracis* in the serum exuding from the scarified lids in a case presenting the œdematous type. Moreau describes a similar case.

Sgrosso, Strzminski, Elschnig, Praun and Pröscher, Pes, and Tertsch, describe typical cases of malignant pustule on the lids with the presence of the bacilli.

In all such cases anthrax serum [Sobernheim (Merck)] should be used. It is said to have good results.

LITERATURE.

Buy, Thèse de Paris, 1881.
Elschnig, K. M. f. A., June, 1893.
Praun und Pröscher, Zentralbl. f. Augenh., February, 1900.
Strzminski, Zentralbl. f. allg. Pathol., 1901, S. 169.
Sgrosso, Annali di Ottalmol., 1899, p. 308.
Pes, Zeitschr. f. A., XII, 1904, S. 442.
Moreau, Revue générale d'Ophth., 1905, p. 193.

Chalazion.

Acute infections of the meibomian glands, such as hordeola and lid abscesses, are caused by the common pyogenic organisms; concerning the cause of the chronic slowly-developing chalazion, however, opinions differ very much.

Baumgarten and his pupils Tangl and Wichert, and to a less degree Parisotti, considered a chalazion to be a manifestation of

[1] A similar appearance may occur in other infections. Gabrielidès ('Ophthalmologie Microbiologique,' 1907, p. 310), instead of the anthrax bacillus which he expected, found a facultative anaerobic Gram-negative polar bacillus, which formed on agar round, yellowish-white colonies, without any odour, and in bouillon a diffuse cloudiness, with a distinct surface film; which liquefied blood-serum and gelatine, did not coagulate milk, and was very pathogenic for guinea-pigs.

tuberculosis, on account of the presence of cell nests and Langhan's giant cells. This view cannot be completely justified.[1] Direct implantations of the contents of chalazia into susceptible animals have repeatedly been made by Weiss, Deutschmann, Vossius, Aschheim, Strzminski, and also by myself, without ever causing tuberculosis. Tubercle bacilli have only been found in rare cases, and caseation has never been seen. The balance of evidence is against tubercle, especially when we consider that the presence of epithelioid and giant cells is not a certain indication of tuberculosis. We can only say that the rare tuberculosis of the tarsus (as also tumours and syphilis) can resemble a chalazion. When carefully and exactly examined, a tuberculosis is found not to begin inside the gland tubule, like a chalazion, but in the surrounding tissue; this point is, however, very difficult to determine clinically. Stock, in his experiments with tubercle of the eye, produced a peri-acinar tuberculosis which broke through into the interior of the gland, and the clinical appearances greatly resembled those of a marginal chalazion. Baumgarten has lately weakened in his views. The occurrence of giant cells, which presumably correspond to the epithelium of the acini, is referred by Henke to the absorption of lime salts. The blockage of secretion appears to be of considerable importance in the disease, although, as E. Fuchs has shown, it cannot alone explain it.

It is not at all unlikely that some infective agent, as well as the retention of secretion, is at work. In favour of this view we have the fact that a second chalazion often occurs on the other lid at the point of contact, and also the considerable inflammatory reaction which sometimes occurs. The common pyogenic organisms are not always found in the interior of the chalazion. Priouzeau certainly reports that, in the great majority of a long series of inoculations, he found the various pus-forming organisms, most often white *Staphylococci*, less often *Diplobacilli*, *Pneumobacilli*,[2] and *Streptococci*; he considered that the *Staphylococci* had a causal significance. Along with Dianoux he claims the existence of an infective 'chalazion conjunctivitis.' On the other hand, it appears to be conclusively shown by Deyl, Hala, and others, that when the contents of the chalazion are isolated without contamination by conjunctival secretion, in many cases no pyogenic organisms can be found; and it is quite clear that the presence of *Staphylococci* (Sattler, Dianoux, Vassaux, Lagrange, Poncet and

[1] Nor can they be classified as 'tuberculids' of the skin, being considered by Hallopeau, Darier, and L. Dor as non-bacillary results of general tuberculosis (para-tuberculosis). The subjects are often quite healthy, and show no tuberculin reaction.

[2] Maklakow (*A. f. A.*, 1901, Bd. xliii., S. 10) described a case with *Pneumobacilli*.

Boucheron, Addario, and Cuénod) is not constant. I can confirm this, as Bietti and I did not see pus-forming organisms in the majority of our cases of chalazia (of course, cases of acute hordeolum internum, which are generally due to such organisms, especially *Staph. aureus*, were excluded). The view that such organisms are present in the gland in the early stages, cause the irritation, and then die out, while the reaction continues, cannot be maintained, for quite in the early stages these organisms are absent.

Deyl found the *B. xerosis* very often in early chalazia, and that too in pure culture; he called the organism the 'chalazion bacillus,' and considered it as causal.

It is quite true, as I convinced myself years ago, that these bacilli can often be obtained in pure culture from chalazia which have only been present for a short time. As they are normally present in the secretion of the meibomian glands, the question arises as to whether they are not indifferent inhabitants of the chalazion, and as such they could be present at the first. Deyl records the fact, on which Hala has again insisted, that the bacilli disappear when the lesion has existed for some time. In spite of this, however, we can see that the chalazion increases and grows even when its contents have been evacuated. Must we not, then, conclude that the *causa nocens* is present during the whole progress of the lesion, as is the case in other infectious diseases? If we give the Deyl bacilli an etiological role, it can only be with regard to the first onset of the affection, which we must consider as capable of continued development after the rapid disappearance of these bacilli.

Deyl finds support for his contention in that he was able to produce small rounded tumours resembling chalazia, by directly injecting about a cubic centimetre of a thick suspension of the bacilli under the skin of the ear or under the conjunctiva. In such swellings the bacilli rapidly disappear.

Hala produced the same result by injecting various bacilli obtained from the healthy or diseased conjunctiva, from the urine and blood of typhoid cases, etc. Dead cultures produced the same result as living. In these experimental chalazia the bacilli die out so rapidly that they can only be cultivated during the first few days.

These results were confirmed by Bietti working with many xerose bacilli in my laboratory. It should, however, be noted that many different non-pathogenic bacteria, when injected in the enormous numbers which such a suspension contained, would produce a similar result. Bietti produced nodes, similar except that they resolved more

rapidly, with *Sarcina aurantiaca*, dead *Hefa rosa*, a *Pseudo-gonococcus* and a *Subtilis* organism. The chalazia do not contain these (Deyl) organisms in such large quantity, but often only very scantily. According to Bietti's results, too, the Deyl bacillus cannot constantly be demonstrated in early chalazia.

As the relationship of these organisms to those of diphtheria should be taken into consideration in every experimental research, Bietti repeated the lid injections in animals immunized to diphtheria with Behring's serum, and obtained the same result, even when the serum was mixed with the bacterial emulsion.

With rare exceptions, the organisms obtained from chalazia, on subcutaneous or intraperitoneal injections even of large quantities, showed no pathogenicity for guinea-pigs. The formation of these nodes at the sites of inoculation bears no relationship to specific diphtheritic action, and Hala is wrong when he sees in them any proof of the identity of these organisms with the diphtheria bacillus.

Under these circumstances the proof of the etiological rôle of the *Bacillus xerosis* regarding chalazia must be considered as not sufficiently established. We can only say with certainty, with Fuchs and De Vincentis, that there is an adenitis and a peri-adenitis, during whose course masses of inflammatory material are formed, which resolve with difficulty, and that a granulation tissue containing giant cells results. Henke emphasized the presence of debris and crystals, which acted as foreign bodies. Whether the structures described by Alessandro as occurring in the epithelioid and giant cells really are Blastomycetes, still requires proof. How far bacterial irritation is at work also needs further investigation. Even if we accept the *Bacillus xerosis* as its cause, Hala's explanation as to how the chalazion infection occurs still appears inadequate. He considers that the bacilli normally present in the conjunctiva are rubbed in by wiping the eyes, etc. As a matter of fact, however, the bacilli could not thus be brought into the meibomian glands lying in the tarsus where the reaction occurs, but only into their ducts lying in the lid margin, where they actually are found under normal circumstances, as are the *Staphylococci* in the hair-follicle glands of the skin; and as these latter, in cases of special diatheses and anomalies of secretion, can produce acne pustules, a similar result may follow the action of the organisms which are found in the meibomian glands, which are merely giant sebaceous glands.

LITERATURE.

ADDARIO, Ann. di Ottalm., 1889.
ALESSANDRO, Blastomiceti nel calazio. Clin. ocul., 1906, S. 2690.
ALFIERI, Archivio di Ottalmol., vol. 3, p. 77, 1895.
BAUMGARTEN, Lehrbuch der pathol. Mykologie, 1890.
BIETTI, Archivio di Ottalmol., XII, Fasc. 11, 12.
BOSSIS, Thèse de Paris, 1902.
BOUCHERON, Recueil d'ophth., 1886.
CUÉNOD, Bacter. des paupières. Thèse de Paris, 1894, p. 125.
DEUTSCHMANN, Beiträge z. Augenh., 1891, Heft 2.
DIANOUX, Arch. d'ophth., 1891, p. 302.
DEYL, Verhandlungen der Prager Akademie der Wissenschaften, 1893-94.
ERDMANN, Über einen Fall von Chalazion marginale. Arch. f. A., LI, 1905, S. 171.
FUCHS, E., Text-book, 1897.
FUKALA, Zentralbl. f. A., Oct., 1893.
GIFFORD, The Journal of the Amer. Med. Assoc., October, 1903.
HÁLA, Z. f. A., 1901, Bd. 6, S. 371.
HEINERSDORFF, A. f. O., 1898, Bd. 46.
HENKE, Virchows Archiv, 1900.
KOHLMOES, Inaug. Diss. Giessen, 1893.
LANDWEHR, Zieglers Beiträge z. pathol. Anat., Bd. 16, 2, 1894.
LAGRANGE, Archives d'ophth., May to June, 1889.
MANFREDI, Internat. Kongr. Rom, 1894.
PALERMO, Annali di Ottalmol., vol. 26, p. 481, 1896.
POROSCHIN, Zentralbl. f. pathol. Anat., 1899, S. 669.
PRIOUZEAU, Annales d'ocul., t. 119, p. 126, 1898.
PONCET et BOUCHERON, Archives d'ophth., 1886, p. 283.
PARISOTTI, Soc. franç. d'ophth., XI, p. 210.
ROLLET, Tarsite tuberculeuse. Archives d'ophth., June, 1905.
SATTLER, Internat. Ophth. Kongr. Heidelberg, 1888.
TANGL, Zieglers Beiträge z. pathol. Anat., Bd. 9, 1891.
VASSAUX, Comptes rendus de la Soc. de biologie, June 17, 1886.
VOGEL, Inaug. Dissert. Tübingen, 1898.
VON WICHERT, Zieglers Beiträge z. pathol. Anat., Bd. 15, 1893.

Molluscum Contagiosum.

Molluscum contagiosum is an infectious and by no means uncommon lid affection. The characteristic round white elevations, with a central depression, out of which the molluscum contents project, are often overlooked or wrongly diagnosed. The expert clinician will make a positive diagnosis (especially after examining with the loupe), which can be confirmed by examining the material expressed from the tumour under the microscope in salt solution or glycerine, when oval, refracting, granular molluscum bodies appear, surrounded by membrane of double contour; their diameters average 30 by 20 to 25 μ.

In microscopical sections the bodies can be seen to arise in the

peripheral epithelial cells of the molluscum. They increase in size towards the centre at the expense of the cells, and finally leave the flattened squamous epithelial cells and lie free.

Cultures have not succeeded.[1] The generally accepted view that the bodies themselves are the parasites is still disputed by many, who consider the molluscum bodies only as cell degenerations and the results of an infective process. It is universally agreed that infection can be carried by the contents of the cysts when expressed; this is confirmed by numerous trials and the clinical records of infections, among which we have the positive inoculation which Paultry[2] made on himself with a molluscum of the lid margin.

Fuller details of this subject can be found in the article by Mütze (*Arch. f. Aug.*, 1896, xxxiii., S. 302). For the literature, see Falkenburg (Inaug. Dissert., 1898, Munich); Elschnig (*Wien. Klin. Wochens.*, 1897, No. 43); Fischer (Inaug. Dissert., Rostock, 1903); Herzog (*Arch. f. Anat. u. Mikros.*, 1904); Oppenheimer (Oph. Record, April, 1905).

Rarer Lid Infections.

When the clinical appearances have fully developed, **favus** of the lid resembles the same disease in other regions. An early case, however, requires careful examination, and will be first recognized by the microscope.

Cases of favus exclusively affecting the lids are recorded by Narkiewicz,[3] Schiess and Gemuseus,[4] McHardy,[5] Cuénod,[6] Gloor,[7] Schmidt-Rimpler,[8] Libman,[9] Derby,[10] Pecoraro,[11] Pergens,[12] Treacher Collins.[13]

Ovoid spores 3 to 4 μ broad are found in the fine scales, either singly or in chains, and along with them the mycelium of the *Achorion Schönleinii*. This forms a network of granular hyphæ, varying in thickness, easily recognized in an unstained preparation (water and glycerine) after the addition of a little acetic acid or clearing with caustic soda. The organism grows readily on agar. In a few days it forms a yellowish-white surface crust, which is often covered with a white down. Schmidt-Rimpler obtained cultures on panada.

The varieties (α, β, γ) described by Quincke, and the many modifica-

[1] We generally obtain the common cocci (Herzog).
[2] Quoted by Cuénod, p. 115.
[3] *K. M. f. A.*, 1870, viii., S. 78.
[4] *Ibid.*, 1873, xi., S. 238.
[5] Lancet, March, 1885.
[6] 'Bakt. des Paupières,' *Thèse de Paris*, 1894, p. 101.
[7] *A. f. A.*, 1898, Bd. xxxvii., S. 358.
[8] *Deutsche Med. Woch.*, 1902, No. 2.
[9] Arch. of Ophth., 1887, Vol. v., p. 199, quoted by Derby.
[10] T. Amer. O. S., 1906.
[11] *Arch. di Ottal.*, 1904, xi., p. 311.
[12] *K. M. f. A.*, 1897, xxxv., S. 241.
[13] T. O. S., 1903, p. 1.

tions enumerated by other authors (Unna, Bodin, etc.), are found on prolonged cultivation not to be constant. The researches of Kral, Sabrazès, and Pick, have shown that they are merely variations of the same mould.[1]

Cuénod conducted an investigation to see whether the *Achorion* played any part in the cause of the ordinary ciliary blepharitis, induced thereto by the fact that Ellinger (*Virchow's Archiv f. Path. Anat.*, 1862, Bd. xxviii., S. 449) found a mould resembling favus in the roots of the cilia in a case of apparently simple blepharitis. Cuénod only once found something similar along with many colonies of *aureus*. In an article by Gunning (*Neederl. Tidjschr. v. Geneesk.*, 1865, ii., 4, S. 417) we find a record similar to that of Ellinger. Vörner (*K. M. f. A.*, August, 1901, ii., S. 872) is of the opinion that, in the cases of Ellinger and Gunning, it was not favus which was observed, but either a *Trichophyton* or a chance occurrence of some mould in a simple blepharitis ciliaris. According to Pecoraro, the lid margin is generally exempt from favus.

Tinea Trichophytina (Ringworm) of the lids presents no special peculiarities. In the cases of Cartaz (*Lyon Médicale*, 1870, No. 2) and Gailleton (*Gaz. Hebdom.*, June 21, 1889) the lids were involved in a tinea of the face. Mibelli (*Ann. di Ottal.*, 1894, xxiii., p. 368) described a 'blepharitis trichophytica.' Further observations are given by Niclos and Hallopeau (*Médecine Moderne*, 1895, No. 6), fully quoted by A. Terson (*loc. cit.*, p. 440), Vörner (*Klin. Mon. f. A.*, 1901, p. 971),[2] Snell (Ophth. Rev., 1902, p. 90). Herzog (*Z. f. A.*, 1904, xi. and xii.) gives a detailed description of lid favus, with special reference to the peculiar histological changes (*Plasmonbildung*) which occur.

From epilated cilia Vörner obtained on various media snow-white cultures, with aerial hyphæ several millimetres high. Microscopically the mycelial hyphæ presented the appearance of septate filaments dividing dichotomously; fructification organs developed in older cultures. The long aerial hyphæ, even in young colonies, showed buds from which the reproductive organs developed; later on fructification became more and more obvious. A thick felted mycelium of the *Trichophyton*, throughout which are reproductive organs, lies in the root sheath of the epilated hair.

In a case which I observed in Rostock, where, along with an eruption on the temple, the under lid was also affected, I was easily able to

[1] *Cf.* Plaut, 'Handbuch von Kolle und Wassermann,' 1903, Bd. i., S. 604 *ff.*
[2] Vörner quotes cases by Del Chiappa, Majocchi, and Dubreuille.

grow the *Trichophyton tonsurans* on agar, on which a snow-white, soft, open-meshed mycelium developed. Considering the variability of the *Trichophyton*, we cannot yet say whether these peculiarities of culture will be observed in the other cases.

The *Trichophyton* grows best on yeast agar and maltose agar (Sabouraud). Cultures can be obtained both from the scales at the progressive margin and from the roots of the epilated hairs.

The sub-species of *Trichophyton tonsurans* described by Sabouraud and others are varieties which can certainly be transformed into each other. According to Plaut (Kolle u. Wass., 1903, i., p. 616) they resemble the varieties of favus in possessing many specific peculiarities. The *Trichophyton* grown by Vörner and myself was of the variety called *Trichophyton ectothrix* by Sabouraud.

Under the heading '**Monilithrix**,' affecting the eyelashes and eyebrows, Treacher Collins (T. O. S., 1898, xi., p. 1) described a condition which differed from the ordinary blepharitis in the marked brittleness of the hairs. It also occurred on the scalp. Most of the hairs were broken short close to the skin, and could only be epilated with difficulty, being so brittle. Baldness resulted, but some of the hairs grew again. The condition strongly resembles trichorrhexis nodosa. No distinct micro-parasitic cause for this disease was found, only the inevitable cocci. (The name 'monilithrix' refers to the disease, not to the Hyphomycete.)

In the collected literature given by Groenouw ('Handb. der Aug. von Saemisch,' 2nd edition, 1903) two cases of **Oriental sore** (*Aleppo boil, Delhi boil, Biskra button,* etc.) recorded by Willemin, 1854, are given. A. Terson records such a case in the museum of the St. Louis Hospital (*loc. cit.*, p. 408). According to the later researches of Brocqu and Veillon, this disease is perhaps a *Streptothrix* infection (*cf.* Babes, Bd. iii., p. 446, *Handb. von Kolle u. Wassermann*). The various cocci and bacilli recorded by other authors are probably secondary. Recently many observers have referred this affection to Protozoa.

Rhinoscleroma may affect the tear ducts, the lacrymal sac, and the adjacent parts of the skin (*cf.* Gallenga, *Zentr. f. Aug.*, 1899, S. 289). Bacteriological examinations with positive results are recorded by Gallenga. His findings were typical: capsulated bacilli strongly resembling the *Pneumobacillus* in morphology and biology, and, according to de Simoni (*Zentr. f. Bakt.*, 1900, xxv., S. 625,) certainly belonging to that group. Their decolorization by Gram's method was not so constant; the stab-culture in gelatine had more of a grey transparency, and was not so white as that of the typical *Pneumobacillus*. The bacilli are

regularly found in rhinoscleroma, from which fact, in spite of occasionally expressed doubts, the majority of dermatologists accept them as causal.

Examples of typical **Actinomycosis**, with microscopical proof of the presence of nodules (Drusen), are given in the cases recorded by Partsch (*Zentr. f. Aug.*, 1893, S. 161), Darier and Gautier (*Ann. de Dermat. et Syph.*, 1891, p. 449), Dor (*Gaz. hebd. de Méd. et Chir.*, 1895, No. 4), and Ransom (Brit. Med. Jour., June 27, 1896). The lids participate in the marked changes occurring in the cheek and orbit. The bacteriological diagnosis is of interest to the ophthalmic surgeon on account of the 'fungus concretions'[1] described in Chapter VII., whose classification causes considerable difficulty because of the variability of the organism, and the keen discussion which is now taking place respecting the whole group of Actinomycetes.

The 'branching fungi'—the Actinomycetes—on solid media form thick, prominent, tough, crinkled, or knobby colonies; and in fluids rounded granules or nodules, which sink to the bottom and cannot be shaken out. In the body yellow granules are formed. When examined microscopically, we see long, thin, straight, or coiled filaments, Gram-positive, having side branches, and often ending in club-shaped thickenings. They may stain in sections, and thus present the appearance of chains. In young cultures they sometimes greatly resemble the *Bacillus diphtheriæ*. By multiple fission an appearance of spores or cocci is formed by their resolution. In the centre of the culture, and well seen in embedded sections, a thick tangle is formed, with radial bundles of fibres passing out from it. In the tissues of animals radially arranged knobby swellings are formed, which do not stain with Gram. Amongst the many members of this group we recognize, on account of its orange agar cultures, and its slow liquefaction of gelatine, the *Actinomyces bovis*, the cause of the disease in man and cattle. Descriptions, however, vary considerably. For further particulars see Schlegel, *Handb. von Kolle und Wass.*, Bd. iii., and Petruschky, *ibid.*

Israel's form of *Actinomyces bovis*, which is characterized by its anaerobic. growth, and by the absence of branching in the cultures, according to Mertens, (*Zentr. f. Bakt.*, xxix., S. 641) can be transformed into the aerobic form of Bostroem of which it is only a variety.

Glanders (farcy, Rotz, morve) has several times been observed on the lids. Knapp (*Arch. of Oph.*, xxvii., p. 374) found the *Bacillus mallei* in an ulcer of the lower lid. In Neisser's case (*Berl. Klin. Woch.*, 1892, S. 321) an inflammatory swelling developed from the inner canthus, and later led to a dacryocystitis. Gourfein found the *Bacillus mallei* in the pus from a lacrymal sac, identifying it by inoculating guinea-pigs, from which he was able to grow the bacilli in the typical manner. (Cultures are essential to differentiate allied

[1] It must be emphasized that the case of De Vincenti (*Lavori della Clin. Ocul. di Napoli*, iii., p. 324) was later proved by Fuchs to be a 'concretion in the conjunctiva.' Similarly the case of Demicheri (*Arch. d'Oph.*, 1899, xix., p. 102) is not one of actinomycosis, but a concretion, mistaken on account of its radial arrangement.

species. See chapter on 'Conjunctivitis,' p. 108. For further details bacteriological textbooks should be consulted; also the articles by Krajewski, 'Blepharitis von eigentümlicher Form,' Jahresber., 1873; Tedeschi, *Ann. di Ottal.*, xxi., p. 455 (experimental inoculation); Andral (see A. Terson, *loc. cit.*, S. 417); Tarnawski, *Thesè de Paris*, 1867.

Ulcus molle (soft chancre), has been observed in rare cases on the lids (Hirschler,[1] Coppez père,[2] Galezowski,[3] Würdemann,[4] Tastoux, Gaston.[5]

Just as is the case with such ulcers in other situations, so we find here the Ducrey-Krefting soft chancre bacillus[6] in the material scraped from the cleansed margin of the ulcer.[7] This organism is 1·5 to 2 μ long 0·5 to 1 μ broad, rather more slender in the middle, non-motile, and tends to lie in pairs, or in chains—a *Strepto-bacillus*—especially when in sections. It is Gram-negative. The poles of the rather faintly staining bacillus are often rather more deeply coloured than the light centre. They grow on blood-agar (1 : 2 to 4) when in the incubator, forming greyish prominent coherent colonies, which perish after a few generations. Inoculation of men or apes with a pure culture causes typical soft chancre. The etiological records of soft chancre of the lid generally belong to the period before the discovery of the Ducrey bacillus. The certain bacteriological findings in our literature are those of Gaston and Tastoux.

The bacilli have been found in the still rarer ulcus molle of the conjunctiva (see p. 249) by Vignes.

In the differential diagnosis the *Diplobacillus* must be considered; it is much larger, and its cultures are quite different. The clinical appearances also are very unlike.

Greef and Kowalewski report that they have found the *Spirochæta pallida* in **ulcus durum** of the lids.

With regard to the disease described by Gilchrist[8] under the title '**blastomycosis cutis**,' we have only a few records from America, especially the work of Montgomery (Jour. Amer. Med. Assn., 1902, p. 1486), Wilder (*ibid.*, 1904, p. 2026), Wood (Ann. of Oph., 1904, p. 92). According to the review of G. S. Derby (*loc. cit.*), the skin of

[1] 'Blepharitis Syphilitica,' *Wien. Med. Woch.*, 1866, Nos. 72-74.
[2] *Journal Méd. de Bruxelles*, November, 1894.
[3] *Recueil d'Ophth.*, October, 1882.
[4] Amer. Jour. of Ophth., May, 1891.
[5] *Thèse de Groleau*, quoted by A. Terson, *loc. cit.*
[6] *Cf.* collected references by Zeissl, *Zent. f. Bakt.*, xxxi., S. 169.
[7] As the ulcer can be freely contaminated with other organisms, the superficial layer of granulations should first be removed.
[8] Johns Hopkins Hosp. Rep., 1896, vol. i., p. 206.

the lid is the favourite site of this essentially rare disease. In about forty or fifty cases at least ten were primarily lid affections.

The single similar record in the German literature is that of Rosenstein (*Zentr. f. Aug.*, 1904, S. 14), who found a pure 'hefa' in an ulcer of the lower lid. The organism was 'mostly in a spore condition; here and there mycelial forms could be seen.' Cultures failed. The case differed clinically from that of Gilchrist, in that within fourteen days a deep ulcer the size of a bean developed. At the end of his paper Rosenstein describes the case as 'contaminated by hefa cells.' The etiological significance therefore of this finding is not determined.

The disease described by Gilchrist begins as a papule, which then slowly passes into a dark red moderately elevated swelling, in which numerous small abscesses develop, without, however, any tendency to widespread ulceration. While the disease progresses healing may occur at the original site.

(The clinical aspect resembles that of 'framboesia Brasiliana,' which Breda[1] has found affecting the lids in a single case. The etiology of this disease is still unknown.)

The Blastomycetes appear in the contents of the small abscesses as small round, refractile, vacuolated bodies, having a double contour, often lying in pairs or in branching chains. In culture (small white colonies, with thread-like processes and aerial hyphæ) a mycelium is formed. Busse (Kolle u. Wass., Handbuch 1903, Bd. i., S. 681) therefore denies that this fungus is a Blastomycete; it belongs more to the *Oidia*. Microscopically the skin shows profuse hypertrophy of the epithelium, with an inflammatory infiltration and abscess formation in the corium. Inoculations of the culture in animals produced a similar clinical picture.

This infection might, with more careful examination, be found by us (in Europe) more commonly. Our knowledge of pathogenic hefæ (*Saccharomyces hominis* or *S. Busse*) is mostly due to the work of Busse. According to him, their demonstration in the tissues is most readily achieved in fresh preparations, especially after the addition of caustic soda. The bright concentrically marked hefæ with their double contour are then very clear.

In aniline stained preparations it is very difficult to find them. The best method is to counter-stain a hæmatoxylin or hæmatein preparation with very dilute carbol fuchsin (1 : 20 water) for one-half to twenty hours, and slightly decolorize with alcohol. If

[1] *Annali di Ottal.*, xxiv, supl. 189.

successful the *Hefæ* will show up as glistening red bodies of varying sizes.

By means of experimental endogenous infection with pathogenic *Hefæ*, Stock[1] produced numerous miliary nodules and small abscesses in the skin of the lids and conjunctiva in rabbits.

Regarding the so-called **Botryomycosis,** which has been observed as an infective tumour on the vas deferens of animals, and which can be conveyed to men, see the remarks in the chapter on 'the Cornea.' Ten Siethoff's case (*Weekblad*, 1888, No. 12, Bd. i.) at first clinically resembled a hordeolum, but there was a swelling of the conjunctiva and the formation near the lid border of small yellow deposits resembling actinomycosis granules. A slimy mass was discharged from the hordeolum, in which Ten Siethoff reports that he found the *Botryococci*. Many hold that these organisms are identical with the *Staphylococcus pyogenes aureus* (literature, *cf.* Bargeton, *Thèse de Lyon*, 1905).

For Leprosy, Tuberculosis, Syphilis, *cf.* Chapter IX.

[1] Zeigler's *Beiträge z. Path. Anat.*, 1908, 2.

CHAPTER IV

WOUND INFECTION

COMPARED to the frequency of secondary healing in other parts of the body, post-operative suppuration in the eye, even in the pre-antiseptic days, was singularly infrequent. The loss by skilled operators in the period of the flap section was about 10 per cent., and this was considerably reduced by A. von Graefe's linear section. The relative smallness of the wounds and the short duration of operations on the globe, which in themselves tend to lessen the danger of infection, do not completely explain this relatively favourable state of matters, as they are offset by the vulnerability of the eye[1] and the low power of resistance presented by its almost avascular tissues. The true explanation, according to modern science, lies in the fact, already fully considered, that the surroundings of the eye, when in a healthy condition, do in fact possess a relatively lower tendency to infection than most other parts of the body. Even if the self-cleansing of the conjunctiva is unable to make it quite sterile, still it greatly lessens the number of organisms present, and produces a condition of nutrition most unfavourable to their increase or virulence (*cf.* p. 42).

The direct **bactericidal influence**[2] so often attributed to **the tears** is of comparative insignificance in comparison to the mechanical factor discussed under 'Normal Conjunctiva,' and plays a very small part in the auto-sterilization.

Van Genderen-Stort (*loc. cit.*) found that the tears had no lethal action on *Bac. coli;* on the contrary, Bernheim[3] found that they had

[1] Bossalino (*Ann. di Ottal.*, 1904) has thoroughly established this low resistance of the eye relatively to the subcutaneous tissues, by a special series of experiments with *Staphylococcus aureus* (see also under 'Saprophytes,' p. 91).

[2] The opinion of Muck (*Münch. Med. Woch.*, 1900, SS. 1168 and 1732) that the action of the tears depends on their containing sulphocyanides still requires confirmation. The sputum, which is secreted by the parotid and its allied glands, is stated by Clairmont (*Wien. Klin. Woch.*, 1906, No. 47) to have a restrictive action on the development of small numbers of pyogenic *Staphylococci* and *Streptococci*. Generally, however, the sputum has no bactericidal action.

[3] 'On the Antisepsis of the Conjunctiva and the Antibacterial Action of the Tears' (*Beil. z. Aug.*, 1893, Bd. viii., S. 6).

such on *Staph. aureus* and *Bac. subtilis*, and more freely the less the number and virulence of the Bacteria in question. On the *Micrococcus prodigiosus* the tears had no influence. Marthen[1] demonstrated some action on *Staphylococci*, and investigated at the same time the results on some saprophytes (*Micrococci* and *Sarcinæ*); a certain diminution in their number occurred under the influence of the tears. Bach obtained positive bactericidal results with *Staphylococcus aureus* and *B. typhosus*, though not invariably. A similar result was obtained with saline solution of the same concentration,[2] dialysed blood-serum, and distilled water. According to Bach, heating the tears has no effect on this action, which he terms bactericidal; it cannot therefore be due to the serum albumin. The Kieler water bacillus is not affected.

Valude was the first to announce the view that the lacrymal sac was not susceptible to infection by tubercle bacilli, because of the bactericidal action of the tears. Gourfein[3] showed, however, that the bacterial emulsion injected by Valude had simply flowed through the tear passages, and had not settled in them. When he introduced a pure culture into the sac and allowed it to remain there, tuberculosis regularly supervened. Valude[4] then conducted further experiments with a retention fluid collected under the lids which had been stitched together, and concluded that the tears are not merely a bad nutritive medium for the tubercle bacilli, but that they produce a lowering of virulence. With *Staphylococci* there certainly was no bactericidal action. (The whole experiment still leaves in doubt the question whether the fluid used really was similar to the tears.)

Ahlström[5] could demonstrate no bactericidal action in sterile tears obtained from a fistula of the lacrymal gland; in the majority of the experiments the *Staphylococci* increased. With tears from a patient with conjunctivitis he obtained a slight diminution, which he attributed to the lower alkalinity. Bach, after repeating his experiments with alkaline saline, protested against such a conclusion.[6]

In a later communication Bach[7] stated his views more precisely: the action (of the tears) resembled that of saline or water, and was far less important than the mechanical effect.

[1] 'Experimental Research on Antisepsis in Eye Operations and the Bacteriology of the Conjunctival Sac' (*Beit. z. Aug.*, 1893, xii., S. 1).

[2] Francke argues against any bactericidal action of normal saline on the *Staph. pyog. aur.* Bach, on the other hand, insists that when the *aureus* culture is thus diluted down it will die in twenty-four to forty-eight hours. The name 'bactericide' has been given up by Bach.

[3] 'Étude Expérimentale sur la Tuberculose des Voies Lacrimales' (*Ann. d'Ocul.*, 1899, cxxi. 351).

[4] 'Action Bactéricide des Larmes' (*Ann. d'Ocul.*, cxxii. 168, and IX. Inter. Congr., Utrecht).

[5] *Zent. f. Aug.*, 1895, S. 193.

[6] *A. f. A.*, 1898, xxxiii., S. 102.

[7] *Z. f. A.*, 1903, Bd. xi., S. 1.

The experiments of De Bono and Frisco[1] on goats, asses, and calves, showed no bactericidal action. *Staph. pyogenes aureus*, typhoid, cholera and diphtheria bacilli multiplied in the tears. The tubercle bacillus did not lose its virulence; on the other hand, the *Staph. aureus* and diphtheria bacillus were weakened[2] (*vide infra*). These results are not so applicable to man as to those animals whose Harderian glands can be affected.

Helleberg[3] and Hirota,[4] who worked with *Staphylococci*, favour a bactericidal property for *Staph. aureus*, though it is slight and not always demonstrable. Addition of tears to bouillon had more effect than a similar addition of water. In the case of *Staph. albus* (from the normal conjunctiva) any bactericidal property of the tears was certainly not obvious. As this property was lost when the tears were heated to over 58° C., Helleberg considered that the action was due to an admixture with the tears of 'alexine,' which was destroyed by this temperature.

Römer[5] ascribed no definite bactericidal function to the tears. He found that after remaining eight days in the conjunctival sac behind the sutured lids, anthrax spores were unchanged and still virulent.

From these experiments it is clear that a bactericidal action can only occur to a limited extent. The same Bacteria, too, do not always react in the same way. There are two points to be considered:

(*a*) Do the tears form a favourable medium for the growth of Bacteria? The answer is that they are a very bad one.

(*b*) Have they a positive bactericidal (disinfecting) power, or can they diminish virulence?

Although a definite bactericidal action for the *Staph. aureus* occurs, yet such is by no means the case with other pyogenic organisms. Even the *Staph. albus non-liq.*, the common inhabitant of the conjunctiva, is not susceptible to this influence.

With regard to the **bacilli of the diphtheria group,** I consider that any bactericidal action of the tears is practically disproved, seeing that these organisms not only exist and grow in the normal and the pathological conjunctival sac, but even after excision of the sac develop in enormous numbers in the stagnant tears.[6]

It would naturally be of interest to learn what action the tears have on the important pathogenic organisms of the conjunctiva. The *aureus*, which, at the time of the experiments referred to, was considered to be the most important, is much less so than the *Pneumococcus* and others. Dr. Blair (Pittsburg), and Professor Ogawa (Okayama) have carried out some experiments in my laboratory, the former with the *Gonococcus*, the latter with the *Pneumococcus*. For both of these important organisms the tears are naturally a very bad medium; but even with their admixture, no bactericidal action could be shown on susceptible media. These results have been confirmed by Zur Nedden.

[1] 'Sul comportamento della glandole lagrimale e del suo secreto verso i microorganismi' (*Arch. di Ottal.*, 1899, vii. 195).

[2] An excretion by the lacrymal gland of Bacteria in circulation (anthrax, *Prodigiosus*, *Pneumococcus*) did not occur in these animals, although *Pneumococci* could be demonstrated in the intertubular vessels. It only occurred to a limited extent after section of the sympathetic (vasomotor paralysis).

The statement by Valentini (*Boll. dell' Osped. oft. della Prov. di Roma*, 1903, S. 174) that the course of an inoculation keratitis in animals was more severe when the lacrymal gland had been excised requires further confirmation.

[3] Widmark's 'Mitteilungen' (Fischer, Jena, 1901), iii., S. 39.

[4] Hirota, *Cent. f. Bakt.*, xxxi., S. 225.

[5] *Zeit. f. Hygiene u. Infektionskrankheiten*, 1894, xxxii., S., 285.

[6] Plaut and Von Zelewski, *K. M. f. A.*, 1901, S. 369. Marthen (*loc. cit.*), at any rate, obtained no results with the *Bacillus* (*x*). From the description, I would consider it to be the *Bacillus xerosis*.

According to the previously mentioned experiments and results of Gosetti and Jona,[1] which were confirmed by De Bono and Frisco, the tears should show an antitoxic property against diphtheria toxin. If tears be added to the lethal dose the experimental animal should not die so soon as the control. Coppez[2] had already expressed doubts on this point; and Demaria[3] conducted a full investigation into the matter. Absolutely no diphtheria antitoxic action could be found in the tears of voluntary subjects. As it is possible that the amount of antitoxic substance in the blood depends upon some previous diphtheritic attack, we have inoculated ourselves with large doses of Behring's antitoxic serum. Even then, however, our tears were not antitoxic, nor were those of convalescents from diphtheria. And as under normal conditions a higher antitoxic power than that investigated does not occur, we have proof positive that no antitoxic action against diphtheria bacilli occurs. To what extent the lacrymal gland can allow the passage of other antibodies, is not yet determined. Neither had the tears of Demaria's immunized persons any agglutinating action on the diphtheria bacilli. Rymowicz[4] obtained the same negative result with dogs immunized against typhoid and cholera. The same author, using Pfeiffer's experiment, could obtain no bactericidal action with the tears of a dog immunized against cholera, although the blood gave a very marked positive result. The attempt to demonstrate the presence of hæmolysin in the tears of an animal previously treated was negative.

Schulz,[5] Dieulafoy, Widal, and Siccard, opposed to Rymowicz, have found that the tears of many typhoid patients show the Widal reaction (agglutinate typhoid bacilli).

The last-mentioned observations have been made in only a few cases and need enlarging.

The **prevention of wound infection,**[6] in the case of a healthy conjunctiva only necessitates therefore simple and mild procedures, and it is fortunate that such is the case. The energetic use of soap, alcohol, and disinfectants, as in other surgical areas previous to operation, is quite out of the question when dealing with the conjunctiva or eyeball; the skin of the lids alone can thus be treated. Gentle mopping with a swab soaked in non-irritating sterile or antiseptic fluid is all that can be allowed, for any stronger disinfecting or irritating substance will cause a catarrh, with an increase in the organisms, and thus favour an infection. Many surgeons therefore content themselves with sterilized saline, and obtain good results.

A post-operative conjunctival catarrh, a **'post-operative conjunctivitis,'**[7] is not dependent merely on the methods used for

[1] *Riforma Med.*, 1897, iv. 543-555. [2] *Arch. d'Ophth.*, 1899, xix. 565.
[3] *K. M. f. A.*, 1905, Beilageheft (research in Axenfeld's laboratory).
[4] *Arch. Rus. de Path. et de Méd. Clin. et de Bact.*, 1902.
[5] *Med. Klinik*, 1905, 54.
[6] An infection from bacteria of the nose through the nasal duct can be put aside, according to Bach's (*loc. cit.*) experiments. Even when there is a previous stenosis such does not occur (Hauenschild). It is naturally very different with bacteria from a diseased lacrymal sac.
[7] I refer to uncomplicated healing, excluding cases where secretion results from infection of the globe; also cases where a contact epidemic has occurred.

cleansing; there is often a very variable individual disposition to such a condition.

Many patients develop it after every operative interference, even when physiological saline alone is used; the loosening of the epithelium by cocaine has perhaps something to do with it. Post-operative catarrh usually commences after several days. The bacterial contents of the secretion vary. In three almost consecutive cataract cases Ahelsdorff and Neumann (*A. f. A.*, 1900, xlii., S. 68) found Gram-negative *Diplococci*. De Lieto-Vollaro (*Archivio di Ottalmol.*, 1905, xii., 7, 8), working in my clinic, obtained xerose bacilli and occasional yellow *Staphylococci* of low virulence; and since then I have often obtained cultures of *B. xerosis* and white *Staphylococci*,[1] the latter of low or moderate virulence. Bardelli and Bossalino, on the contrary, report that the virulence of these Bacteria is raised by the same causes which promote their growth.

The varying findings show that the Bacteria here are of quite of secondary importance. This view is confirmed by Knapp's researches. He found the common conjunctival organisms in the secretions in post-operative conjunctivitis. We cannot, however, exclude the possibility that they influence the catarrh, or that they can cause a wound infection later, although that only rarely occurs. This post-operative conjunctivitis certainly is less common with the open treatment and thorough asepsis.

Entropion spasticum and similar conditions can act in the same way and produce a catarrh. I have seen a peculiar case with profuse secretion and numbers of *Pneumococci*, where, as a result of the wound giving way, secondary infection resulted, and the eye was lost from pneumococcal panophthalmitis. As there was no previous catarrh, perhaps scattered *Pneumococci* on a normal conjunctiva multiplied and increased in virulence in this case.

Let alone that patients find it objectionable, from a bacteriological point of view suspicion has been aroused as to the formerly universal bandage after cataract operation. This has led many ophthalmic surgeons to dispense with it altogether. The bandage certainly prevents lid-blinking, and thus removes a considerable factor in the physiological self-cleansing. By its action, and also from the increase in temperature, a renewal of bacterial growth in the conjunctiva must occur in spite of previous cleansing. Repeated experimental and bacteriological researches prove that a **bandage applied for twenty-four hours considerably increases the number of organisms in the conjunctiva** [Bernheim (*loc. cit.*), Marthen (*loc. cit.*), Morax,[2] Bach,[3] Dalén,[4] Knapp[5]].

[1] The drawing, Plate II., Fig. 6*b*, showing Gram-positive *Diplococci*, was made from such a conjunctivitis.

[2] 'Recherches Bactériologiques sur l'Étiologie des Conjonctivites Aiguës et sur l'Asepsie Oculaire' (*Thèse de Paris*, 1894).

[3] 'Über den Keimgehalt des Bindehautsackes, dessen natürliche und künstliche Beeinflussung, sowie über den antiseptischen Wert der Augensalben' (*A. f. O.*, 1894, xl. 3). Again, 'Antisepsis und Asepsis in ihrer Bedeutung für das Auge' ['Samml. zwangloser Abhandl.' (Vossius), 1897 (Marhold, Halle)].

[4] 'Mitteilungen aus der Univ.-Augenkl. in Stockholm,' 1899 (Fischer, Jena).

[5] *Berlin. Ophth. Ges.*, June, 1907; *K. M. f. A.*, July, 1907, Bd. ii.

The authors mentioned prove this by the numbers of organisms found before and after the bandage is applied: Morax and Marthen in cases of cataract, the others on normal persons. The variety of the organism is not appreciably altered; after bandaging, *B. xerosis* and white *Staphylococci* are more obvious, and any pathogenic organisms previously present are naturally increased. Dalén also showed that on removal of the bandage the numbers of the Bacteria gradually fell again.

The increase in Bacteria depends on (1) the loss of the cleansing lid movements and the diminished lacrymation; (2) the increased temperature under the bandage and the congestion of the conjunctiva. The first factor is in action without any andage when the eyes are closed during the night (see p. 26).

The dread of this bacterial increase has led many to an **open method of treatment**—*i.e.*, the leaving off of any dressing. Hjort[1] of Christiania, who certainly had previously a disproportionate amount of wound infection, preferred that the lids should move even after cataract extraction. Better to renounce rest and protection than have an increase in Bacteria!

A critical examination of this apparently exact scientific statement showed it to be very fallacious.[2] Dalén tested the bacterial increase in the conjunctiva after application of a bandage, not for twenty-four, but for eight to twelve hours, and showed that till then the Bacteria were fewer in number than before the preliminary cleansing. Even after twelve to fourteen hours (forty cases) he found an increase on both sides in only four cases, an increase on one side and decrease on the other in six cases, and a decrease on both sides in seven cases. From other sources we know that a well-placed corneal section, especially if it be in the vascular limbus, will, with complete rest, be quite closed by this time.[3]

A dressing for the eye which will completely restrain lid movements during the early stages is neither irrational, unmodern, nor unscientific, and even a moderate increase in the number of the organisms does not affect the incision, if well made. Our knowledge of infective processes is not merely concerned with the presence and number of Bacteria, but with the condition of their habitat and the method of infection. Each individual surgeon

[1] *Zent. f. Prakt. A.*, 1897, SS. 138, 329; 1898, S. 33. Also Schiötz, Intern. Med. Congr., Paris, 1900, section for Ophth.; further literature, see my 'Ergebnisse,' Lubarsch-Ostertag, 1896-99, S. 49.

[2] *Cf.* Axenfeld, *Münch. Med. Woch.*, 1903.

[3] Clarke ('Report of the International Congress in Utrecht,' 1899) showed that when rabbits were kept narcotized, corneal wounds healed more rapidly, and that the process was delayed by movements of the animal. Similarly every condition which hinders rapid healing favours infection—*e.g.*, excessive use of cocaine, which damages the epithelium (Mellinger, see literature, Masugi, *K. M. f. A.*, 1901, ii., S. 634). The action of antiseptics may be of importance ('Epithel-schädigung durch Sublimat'; see Widmark and Dalén). Rapidity and dexterity in operating and a clean delivery of the lens are important in preventing infection, while the opposite favours it.

must estimate for himself the value of the factors operating in his cases if he would do the best for his patients; and it is not correct to take a narrow view and institute a radical and perhaps incorrect schema.[1]

The question as to whether this rest in the early stages should be obtained by means of a bandage, and how it should be applied, finds various answers. We can say that protective goggles lined with wool produce a condition of rest, as eye movements cease in the dark. I find this quite suitable for most cases, and more comfortable for patients. A well-applied bandage for twenty-four hours, however, is very serviceable, and cannot be considered irrational. The method of bandaging has produced quite as good aseptic results as 'the open method.'

Without going into the whole literature of cataract statistics (*cf.* Hess, 'Pathologie des Linsensystems,' 'Saemisch Handbuch,' 2nd edition), we may note that the large series, almost without infection, of von Michel (Hauenschild, *Zeit. f. Aug.*, 1899, S. 227), along with many others, was obtained by treatment with a bandage.

With wire goggles, and the eyes kept shut under them, a noticeable bacterial increase occurs in the first twenty-four hours, though it is less than that which results from the bandage. De Lieto-Vollaro[2] proved this on cataract cases in my clinic. Even in the case of patients who, for experimental reasons, were given open protective goggles, and left free to move their lids (iridectomy or needling casse), a bacterial increase occurred with primary healing, though not to the same extent. It must be noted that the results obtained on bandaging the normal eye do not exactly correspond with those after operation, as in the latter case the irritation of the operation, added to that of the previous preparation, will account for a certain increase even under 'open' treatment of the eye.

The presence of microbes, which may appear quite numerous in cultures (ten to twenty or more colonies of *Staphylococci*), and which may cause an inflammation in rabbits, does not always produce suppuration in the affected eye.[3] This fact, which was proved by H. Knapp in 1886, must not be forgotten. Hildebrand, Bernheim, and Marthen have shown that primary healing can occur in spite of the presence of pathogenic organisms in the conjunctival sac.[4] Antiseptic compresses laid on the lids have very little influence on the presence of these pathogenic organisms. Bach has confirmed this experimentally on artificially infected animals, using bandages, compresses, and ointments on the lids (*A. f. A.*, 1895, xxxi., S. 181). Bach has also seen cataract wounds heal in the presence of numerous

[1] Knapp's recent researches gave the same result (*Berlin. Ophth. Ges.*, June, 1907; *K. M. f. A.*, July, 1907, Bd. ii.).

[2] *Arch. di Ottal.*, 1905, xii., Fasc. 7, 8.

[3] See also Ramsay, 'Ophthalmology,' 1905, p. 430; also Gifford.

[4] Septic bandages, too, do not necessarily lead to wound infection (*cf.* Genth, *A. f. A.*, 1903, xlvi., S. 135).

Staph. aureus. When a virulent culture of *aureus* was dropped into the conjunctival sac of rabbits, and then the section made, only 20 per cent. were infected, while wounds made with infected instruments practically always suppurated (*A. f. A.*, 1895, xxx., S. 225).

Morax rightly insists that a corneal pocket inoculated with countless organisms from a culture is very different from the presence of a few microbes in the conjunctival sac.[1] As a current passes out from every perforated corneal wound (Knapp,[2] Wilson[3]) until it closes, the Bacteria may often never come in contact with the lips of the wound; and even if they do, it is always questionable whether the 'infection' with such scattered organisms must necessarily cause an inflammation. **The eye does possess a power of antagonizing and neutralizing an infection.** Putting aside the question of specific immunity, the result will be determined by the general and local power of resistance, the initial damage to the tissues, the site of the infection, and the variety, number,[4] and virulence of the organisms introduced.

The aqueous fluid alone is a bad medium for the growth of Bacteria (Nuttall, Buchner, Marthen, Bach). The antagonistic action of the uvea and removal by the lymph stream,[5] acting with a vigorous phagocytosis,[6] ward off a simple infection of the anterior chamber. By injecting a trace of an undiluted bouillon culture of *aureus* into the anterior chamber in rabbits, Andogski[7] only obtained a purulent iritis, which healed spontaneously: $\frac{1}{4}$ c.cm. undiluted bouillon was the least that would cause a panophthalmitis; very diluted bouillon culture would only cause slight transient iritis. The action was the same on eyes which had been iridectomied; also in aphakic eyes, where, some time previously, the posterior capsule had been removed with the lens intact. If, however, the lens had been freshly needled or extracted, so that from the admixture of lens substance with the aqueous a medium very liable to infection resulted, then panophthalmitis followed the injection of the merest trace of the culture, and this occurred most readily when the posterior capsule had been injured. This was the case in a simple needling of a secondary

[1] Schmidt-Rimpler had previously shown that the action of the secretion of the lacrymal sac was not identical with that of the Bacteria cultivated from it.

[2] *A. f. A.*, 1886, xvi., S. 167. H. Knapp, sen., was the first to study this subject bacteriologically.

[3] 'Bacteria and Ophthalmic Surgery' (*Ann. of Ophth.*, 1896, v. 2053).

[4] Pereles, inoculating the eye with the heart's blood of a mouse dead from pneumococcal septicæmia, only obtained a severe but transient inflammation. Using the splenic pulp of the same animal, which contained a greater number of the same virulent organisms, a purulent panophthalmitis resulted.

[5] According to the preparations of Andogski and Picot, the crypts of the iris have nothing to do with this. The removal of the Bacteria occurs in a somewhat different manner from that of indifferent granules of indian ink (Nuel and Bénoit), and takes place chiefly through the angle of the chamber. This has been corroborated by the simultaneous researches of Römer (*A. f. A.*, 1906, lv. 4, and lvi. 1, 2).

[6] *Re* phagocytosis of the eye with reference to the *Staph. aureus*, *cf.* Hess, *Virch. Archiv*, 1897, Bd. cx.; Kalt, *Ann. d'Ocul.*, 1895, cxv. 61; Picot, *Arch. d'Ophth.*, 1898, xviii. 341.

[7] Concerning the danger of infection in different eye operations, and the conditions under which suppuration extends from the anterior chamber to the deeper structures of the eye.

cataract. Otswald found that the mixture of lens substance favoured infection. Korotkow found the same condition of affairs (*Wratsch*, 1903, No. 50; *Ann. d'Ocul.*, 1904, cxxxii., 152). He found that the course of an endogenous wound infection was much more serious if the lens capsule were opened and the vitreous damaged. A wound infection much more rarely occurs in the case of a pure anterior chamber wound, as the Bacteria introduced are much more rapidly overcome.

The varying virulence of one and the same organism has resulted in different experimenters obtaining different results, so that it would be hazardous to definitely establish any standard. Bearing this limitation in mind, the large comparative series of Picot[1] definitely shows the action of the various pathogenic organisms in the anterior chamber. *Staph. aureus* and *Streptococcus pyogenes* produce rapid suppuration; *Pneumococci*, *Pneumobacilli*, and *B. coli* act more slowly, producing a more fibrinous exudation. Typhoid bacilli produce no local results, even though, like the other organisms, they may cause a fatal general infection.[2] Anthrax bacilli produce a fibrinous, gelatinous exudate, free from cells. *Tetragenus* causes an inflammation, which resolves spontaneously, even though fatal septicæmia results. Picot could trace in his preparations with what varying rapidity the different organisms died out locally; this occurred relatively soon in the case of *B. coli*, *Pneumococcus*, and *Tetragenus*, though it varied very much according to the virulence of the particular culture used.

Although it is well established that the immediate vicinity of the eye is comparatively safe, that the eye occasionally overcomes an infection, and that primary healing is not impossible in spite of the contact of pyogenic organisms, we must still consider that the removal of the Bacteria, both before and during wound healing, is well worth our utmost endeavours.

It is now generally agreed that the conjunctival sac, like all other exposed mucous membranes, cannot always, perhaps even can never, be made absolutely sterile without damaging it by the very means employed. The results quoted in the collected literature of antisepsis and asepsis, referring to 'sterility in so many cases per cent.,'[3] and arrived at by actual trial, must be interpreted in the sense that *the number of organisms was so reduced that a test collection no longer showed any Bacteria.* De Lieto-Vollaro's researches with susceptible media never showed a complete sterility after cleansing, but only a diminution; these results agree with those of Morax, Rymowicz, and others.

The variation in the bacterial contents of the normal conjunctiva makes it difficult, as Haab and his pupils have shown, to establish from purely clinical statistics, the value of any method of cleansing

[1] *Arch. d'Ophth.*, 1898, xviii. 341.

[2] Römer's researches (*A. f. A.*, 1906, lv. and lvi.) in intra-ocular inoculation show how regularly and rapidly the infective agent is taken up by the blood-stream, so that it can circulate in other organs, especially in the other eye, and settle down in them. Such a transference is very little noticeable during purulent infection of the human eye. Fatal general infection is very rare. On the other hand, Römer refers sympathetic ophthalmia to such a blood infection.

[3] Records such as those of Bardelli, showing a 90 to 98 per cent. sterility with dilute formol, are certainly too high; the control research by Bach has proved this.

or disinfecting as a means of preventing wound infection. For this reason experimental research methods were first employed by Bernheim. Bach and Neumann have shown that localized smooth areas of the conjunctiva can be often cleaned quite free from organisms, even when they are very plentiful; the whole conjunctival sac, however, cannot be so purified.

Bernheim carried out experiments on the conjunctiva, which he infected with easily recognizable organisms.[1] His method was followed by Bach,[2] using *Staph. aureus* and the red Kieler water bacillus. Hildebrand, Marthen, Van Genderen-Stort, Strohschein, Franke,[3] Morax, Gifford,[4] Blagoweschenski,[5] Bardelli,[6] Dalén (*loc. cit.*), Despagnet,[7] Velez,[8] De Lieto-Vollaro, Ahlstroem, etc., however, estimated the number and pathogenicity of the organisms naturally found on the conjunctiva before and after cleansing.

All these researches, and the whole discussion, can be summed up by saying that *cleansing the conjunctiva with the usual antiseptics has no advantage over a simple treatment with saline solution*, as in a permissible strength their disinfecting power is very slight, and stronger solutions cannot be used on account of their irritating properties.

The previously mentioned researches of Andogski show the extremely low resistance of the vitreous, and how very rapidly organisms multiply in it. In many injuries (perforating wounds, etc.) the organisms are exclusively localized in the vitreous, or at least show a marked preference for this situation. Such are the cases which Straub[9] designated 'hyalitis,' as the exudation in these 'vitreous inflammations' or 'vitreous abscesses' is derived from the neighbouring tissues. This property is not so marked in vitreous which has been boiled and sterilized. Herrnheiser, in his researches into the nutrient value of sterilized vitreous for certain pathogenic Bacteria (*Prag. Med. Woch.*, 1894, Nos. 22, 24), found that, with the exception of diphtheria,

[1] On such artificially infected conjunctivæ the determining influence of the lid motion on the passage of fluid through the nose is most easily demonstrated (Van Genderen-Stort, Bach, Schirmer).

[2] See here literature up to 1894, *A. f. O.*, xl. 2.

[3] *A. f. O.*, 1893, xxxix., S. 1.

[4] *Arch. of Ophth.*, xxvii. 6; *A. f. A.*, 1899, xxxix. 106; Jour. of Amer. Med. Assoc., October, 1903.

[5] Inaug. Diss., St. Petersburg, 1895.

[6] *Ann. di Ottal.*, 1896, xxv. 48.

[7] *Recueil d'Ophth.*, July, 1895.

[8] *Thèse de Concours*, 1899; *Ann. d'Ocul.*, cxxii. 459.

[9] Ophth. Congress, Heidelberg, 1878 and 1896; *Nerd. Tijdsch. voor Geneesk*, 1903, i. 925; also Vogelsang, 'Bijd. tos de kennis der ontsteking van het Glasachtig Lichaam' (Dissertation, Amsterdam, 1907). I cannot entirely agree with the idea of 'hyalitis,' seeing that the vitreous substance itself does not conduce to the formation of inflammatory exudations, especially their cellular elements. It is noticeable that infections and exudations are often enough limited to the vitreous, and such cases can show special peculiarities.

cholera, and *Bacillus pyocyaneus* the growth in such vitreous was less vigorous than in bouillon, a conclusion which was confirmed by Possek. **On the other hand, in the vitreous of the living eye many Bacteria multiply and develop a very severe inflammatory reaction; although in other parts of the eye they may, in similar quantities, remain encapsuled, or at least have a very much less severe reaction.** The action of the pus-forming organisms is especially vigorous and their development enormous. This can be observed microscopically in wounded eyes, or better in those with metastatic infections, in which latter, for example, the whole vitreous chamber may be filled up with masses of *Streptococci*. Injections of vitreous fluid are very useful in exalting the virulence of attenuated pyogenic organisms. In such cases trial sub-inoculations must be made early, as a secondary diminution of virulence rapidly ensues. Most *Streptococci* under these circumstances form specially long chains.

Small numbers of typhoid bacilli or cholera bacilli produce suppuration in the vitreous, often with fatal general infection (Herrnheiser, Axenfeld, *A. f. O.*, 1894, xl., S. 57; Gillet de Grandmont and Gasparrini, *Ann. d'Ottal.*, 1895, xxiv., p. 343). Similar results were obtained by Sattler[1] in his examination of the Bacteria of lacrymal abscess. He obtained *B. prodigiosus*, a saprophyte which in the cornea only produced a feeble reaction, but in the vitreous caused a suppuration, though certainly not progressive in nature.

The special pathogenic action in the vitreous is only in a very slight degree due to the low temperature in the anterior portion of the eye. The nutritive value of the medium offered by the vitreous is very striking. Not only normally is it poor in, or free from protective bodies, but even when irritated (according to Wessely and Römer) such bodies do not immediately show themselves in it, as is the case with the anterior chamber (further *vide infra*, p. 99). A defensive power is only developed with the inflammation, especially with the invasion of leucocytes, and in the meantime the Bacteria have already enormously multiplied. The elimination of organisms from the vitreous, too, is much more difficult than from the aqueous chamber.

This excessive reaction in the vitreous occurs to a very high degree with many stems of *Bacillus subtilis*, which have practically no action in the cornea, and are only slightly irritating in the anterior chamber, but can produce a fulminating suppuration in the vitreous. As these

[1] 'Verhandl. der Ophth. Ges.,' Heidelberg, 1885, S. 18.

observations have been made in cases of wound infection in men (wounds with pieces of wood, etc.), the literature of *Subtilis* will be now discussed, and I will preface it with some remarks on bacteriology.

Bacillus Subtilis (Heubacillus).[1]

(*Plate III., Fig.* 6.)

Haab and his pupil Paplawska found a large Gram-positive bacillus ('Haab's Panophthalmiebazillus') as the result of a wound from a splinter of wood. Römer has since expressed the opinion that this organism, which he found in a cataract infection, was a variety of *Subtilis*. The bacillus, however, could not be cultivated. In 1902 Silberschmidt proved experimentally by cultures that we had to do with an organism of the *Subtilis* group which occurred in the soil. Kayser confirmed this. Polatti furnished a very full experimental examination of the *Subtilis* forms in the soil of Western Switzerland and their pathogenicity for the eye. Stregulina, under the direction of Silberschmidt, examined the ground flora in the region of Zurich for the presence of pathogenic *Subtilis*.

Morphology, Cultures, Pathogenicity.

General features of the *Subtilis* group: Motile Gram-positive bacilli 1·2 to 3 μ long, 0·8 to 1·2 μ broad, forming oval (usually centrally placed) spores, tending to grow into long chains of rods and filaments. They liquefy gelatine with varying rapidity. Most stems are absolutely aerobic.

On *gelatine-plate* cultures, the single grey colonies show a felted central mass and have a curly edge, with feathery processes; on the surface the liquefied gelatine forms a soft crumbly skin, which is sometimes wrinkled. On *agar plates* greyish white colonies develop, with filamentous or feathery margins (*cf.* Fig. 10). In *bouillon* there is clouding and formation of a scum, and development is well marked, especially in *sugar bouillon*. *Milk* is peptonized; *blood-serum* slowly liquefied. On *potatoes* a creamy scum forms, which is sometimes folded, and in many stems stains yellow or red. The optimum temperature is 22° to 37° C., but growth is free at room temperature; at 0° C. and 50° C. growth ceases. Spores

[1] Axenfeld, *K. M. f. A.*, 1905, xliii., Beilageheft, S. 102. Bänziger and Silberschmidt, *Ophth. Ges.*, Heidelberg, 1902. Bietti, *Ann. di Ottal.*, 1906, xxxv., p. 518. Chaillous, Soc. d'Ophth. de Paris, *K. M. f. A.*, 1907, i. 1. Delbanco, *Münch. Med. Woch.*, 1900, S. 951. Derby, American Jour. of Ophth., 1905, p. 7. Gonella, Internat. Ophth. Kongress, Luzern, 1904, C, S. 75. Gourfein, ebd., B., S. 10. Haab, *Fortschritte der Med.*, 1891, ix., S. 781. Hartwig, Inaug. Diss., Jena, 1903. Hess, 'Pathologie des Linsensystems,' 'Handb. d. ges. Augenh.,' 2nd edit. Kayser, *Zent. f. Bakt.*, 1902, xxxiii. 1, S. 241. Kisskalt, *Zeit. f. Hyg. und Infect. Krank.*, 1904, xlvii., S. 244. Koske, *Arbeiten aus dem Kaiserl. Gesundheitsamt.* Berlin, 1905. Lobanow, *Westnik Oftal.*, 1896, xvi. Meyer, *Zent. f. A.*, July, 1903. Michalski, *Zent. f. Bakt.*, 1904, xxxvi., S. 212. Perles, M., *Virchow's Arch.*, 1895, cxl., S. 209. Polatti, *Ann. di Ottal.*, 1905, xxxiv. Paplawska, *A. f. A.*, 1890, xxii., S. 337. Römer, *Ophth. Ges.*, Heidelberg, 1901. Sidler, *Korrespondenzbl. f. Schweizer Ärzte*, 1903, S. 691. Silberschmidt, *Ann. de l'Inst. Pasteur*, 1903, xvii., p. 268. D. Smith, A. of O., 1905 and 1906, 34, 35. Ulbrich, *A. f. O.*, 1904, lviii., S. 243. Weidmann, Inaug. Diss., Zürich, 1888. Zur Nedden, *A. f. A.*, 1905 lii., S. 143.

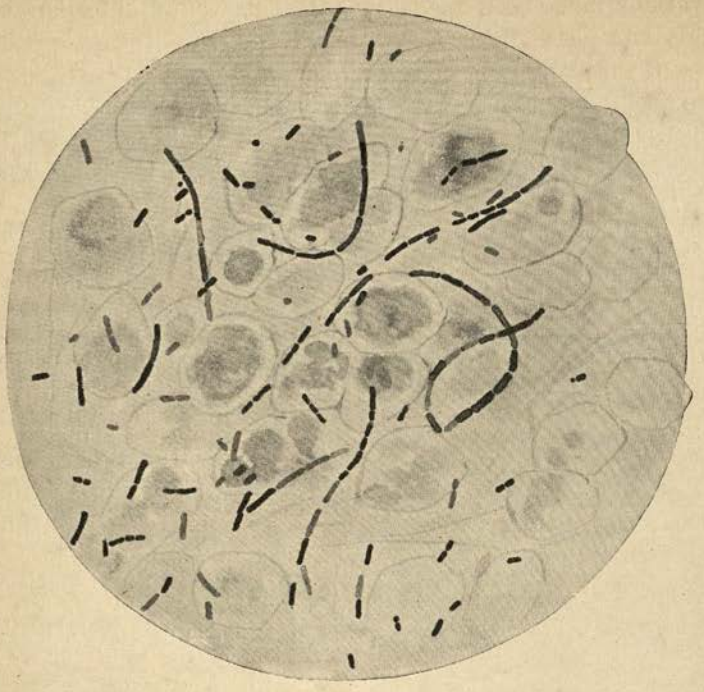

FIG. 7.—BACILLUS SUBTILIS IN SUPPURATING VITREOUS. FREIBURG CASE (KAYSER).

(For differential diagnosis, *cf. Bac. perfringens*, p. 96.)



FIG. 8.—PURE AGAR CULTURE.

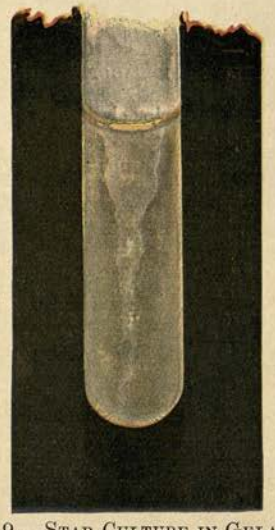

FIG. 9.—STAB CULTURE IN GELATINE OF B. SUBTILIS FROM PANOPHTHALMITIS.

are only killed when kept at 100° C. for one to three hours. Many stems obtained from the earth produce toxic symptoms when injected subcutaneously or into the peritoneum of animals (Stregulina). This has also been demonstrated with the panophthalmitis bacillus (Silberschmidt, Kayser). No particular toxin has been obtained from the bacilli, and an identification of the various stems by means of the agglutination test has not succeeded.

The organisms described under the names *Bacillus mesentericus* (potato bacillus) and *Bacillus megaterium* are very closely related to the *Subtilis* group, from which it is difficult, if not impossible, sometimes to differentiate them. This results from the great variability of *Subtilis*, which can assume those characteristics which many investigators have stated to be peculiar to these two bacteria. These bacteria certainly do belong to the *Subtilis* group.[1] Gourfein found a *Bacillus mesentericus* in an eye infected after cataract operation.

The *Bacillus mycoides* (root bacillus), which occurs plentifully in soil, and is the most closely related saprophyte to *Subtilis*, can also cause severe inflammatory reaction in the eye (see the article by Czermak, *Prager med. Woch.*, 1905, Bd. xxx., No. 8). In his case the globe was perforated by a dirty piece of iron; a ring abscess of the cornea resulted, ending in panophthalmitis. The *Bacillus mycoides* exclusively was found in the pus. Nothing is said about pathogenicity for animals. On agar the colonies were soft greyish-white, and formed freely branched root-like processes, which finally covered the whole surface.

FIG. 10.—AGAR PLATE COLONY OF B. SUBTILIS FROM PANOPHTHALMITIS.

The culture on *potatoes* is at first similar to that of *Subtilis:* at first it is white, then dull yellow, with slender processes.

The pathogenic action on the eye varies greatly in the different stems of *Subtilis*. While Perles and Lobanow only obtained a transient reaction in the cornea, anterior chamber, and vitreous of rabbits, Bänziger and Silberschmidt, on the other hand, obtained a panophthalmitis by injection into the vitreous, thus confirming the findings in cases of wounds with wood-splinters. (The difference in these results is partly due to the different technique, as Perles did not inject, but inoculated with the loop.) We have, however, obtained quite different results when using the identical method with different stems.

In the interior of the eye the *B. subtilis* rapidly dies out. Kisskalt proved that the bacilli at first increased in numbers; even in cases where they did not produce any severe inflammation an increase can be shown to occur within the first thirty-six hours, but after forty-eight hours degeneration sets in. According to Silber-

[1] Chaillous (*Soc. d'Ophth. de Paris.* November 6, 1906), in a case of severe traumatic iridocyclitis, found a Gram-positive *Bacille sporulé*, not quite identical with *B. subtilis* in so far as it was non-motile, more slender, and formed finer and more transparent cultures on agar, no surface film on bouillon, did not liquefy gelatine, and did not grow on potato. The spores were not killed by being heated to 100° C. for ten minutes, and a temperature of 90° C. could be withstood for one hour. The bacilli sometimes produced a purulent inflammation in the vitreous, and the spores, after heating, could still develop. Cultures could not be obtained from the animal's eye again.

schmidt, as a rule, bacilli cannot be found in the vitreous after four days; Stregulina and Sidler agree with this. Kayser could find no bacilli after seven days. Stregulina attributes this largely to phagocytosis. I think, however, that the bacilli also find the natural limits of their growth in the enclosed capsule of the globe, and that their death still further inhibits the growth of the rest. Kisskalt holds the same views. There is generally no formation of spores in the vitreous.

It is possible, when *Subtilis* spores are introduced into the eye, that they only act pathogenically after a considerable period of incubation. Hess brought this forward in connexion with a case of late infection after cataract extraction, and stated that recurrences of inflammation could be explained on the supposition that spores had been enclosed in the healing wound.[1] Till now a latent period has never been recorded after inoculation of *Subtilis* spores; infection has always developed immediately (Ulbrich). Kayser has shown that the toxin lies in the bodies of the bacilli, and filtered cultures do not cause any action when injected into the vitreous. It is especially interesting to note that stems which are very pathogenic in the vitreous produce no inflammation worth mentioning in the cornea. This, however, is not quite true for all stems of *Subtilis*, as is shown by the inoculation experiments of Michalski and Gourfein, and especially the findings of Zur Nedden, who cultivated pathogenic *B. subtilis* pure from the cornea in two cases of Ulcus serpens.

When introduced into the anterior chamber *B. subtilis* produces a severe iritis, which, however, heals without suppuration. I also have noticed how low the pathogenicity of *B. subtilis* is for the anterior chamber in man. From the exudation in the anterior chamber in a case of a perforating splinter of iron, though the condition was improving, I was able to cultivate a *Subtilis* which produced rapid panophthalmitis when introduced into the vitreous of a rabbit.

These *Subtilis* results are of very great interest, as they show how this organism, considered to be a mere saprophyte, can act as pathogenic in a wound, especially of the eye. A few similar observations had previously been made.

Gifford[2] produced a moderate reaction by using large numbers of saprophytic organisms. Sattler found that *Prodigiosus* was pathogenic for the vitreous. Perles and Lobanow carried out a large number of inoculations with various saprophytes. Perles[3] produced a moderate inflammatory reaction in the anterior chamber and vitreous with *Bac. dendriticus*, with *Sarcina aurantiaca* no result, and with *S. lutea* an iritis only when it was injected into the anterior chamber, no result when into the vitreous—*i.e.*, in general he obtained a negative result. Lobanow,[4] on the contrary, injecting *Sarcina lutea*, *Proteus*, *Subtilis*, *Prodigiosus*, *B. agilis*, *Fluorescens putridus*, and *Mic. roseus*, into the anterior chamber and into the vitreous, produced an inflammation varying in degree. *B. violaceus*, *B. ruber indicus*, and *B. candicans* alone were non-pathogenic according to Lobanow.

Certain stems of hefa, according to the experiments of Stöwer[5] appear capable of producing inflammatory infiltrates. Lundsgaard[6] produced a keratitis with hefa, but Knapp[7] could get no action from the same organism.

Deyl[8] found that many stems of the so-called *B. xerosis* produced chronic intra ocular inflammation in rabbits; Kastalska[9] and Demaria[10] found the same, and the latter stated that this action was not equally intense with all stems.

[1] In other parts of the body (bones, encapsuled abscesses) the common pyogenic organisms can become quiescent, and after a long time can cause a recurrence. This has not yet been observed in the eye.

[2] *A. f. A.*, 1886, xvi., S. 197.

[3] *Virchow's Arch.*, 1905, cxl., S. 209.

[4] *Wjestnik Oftal.*, 1899, xv., SS. 3, 215, and *Wratsch*, xx., p. 265.

[5] *A. f. O.*, 1899, xlviii. 178.

[6] *K. M. f. A.*, 1900, xxxviii. 13.

[7] *A. f. A.*, 1886, xvi. 167.

[8] *Böhmische Akad. d. Wissens.*, 1893.

[9] *Gesammelte Arbeiten. Deutsch.*, 1899 (Moskau).

[10] *K. M. f. A.*, 1905, Beilageheft.

These experiments were continued and extended by Noske[1] and also by Ulbrich,[2] with the result that all the organisms which they used could produce inflammation in the eye, even those previously held to be non-pathogenic. The severity of the action varied in the different organisms. *B. cyanogenus*, *B. fluorescens*, and *B. indicus* produce a massive exudation in the anterior chamber, but only slight irritation in the vitreous.[3] *B. candicans* and *B. acidi lactici*, on the contrary, produce only a slight iritis when introduced into the anterior chamber, but in the vitreous a very severe inflammation. *Oidium albicans* at first only causes an iritis, but after about eight days a hypopyon develops.

The general tendency, however, is for inflammations in the anterior chamber to heal without any serious result, while after vitreous infection the appearance of a pseudo-glioma, cataract, and in the end *phthisis bulbi*, is the rule, the final result being due to changes in the uvea.

The action of the saprophytes is not exactly parallel to that of a foreign body, as Ulbrich found no reaction on injecting concentrated carmine, suspension. It is due much more to the chemical action of the disintegrating Bacteria, along with a toxic activity. After injection, the great majority of these organisms rapidly die: they cannot multiply in the eye; the spore-forming bacilli (*B. subtilis, mycoides, megaterium*) prove more resistant,[4] and the *B. acidi lactici* can undoubtedly multiply.

Ulbrich raised the question whether the subacute and insidious forms of wound infection (iritis, iridocyclitis) could not be explained in many cases by saprophytic infection, as the actual experimental organisms which he used, especially the spore-forming ones, can, as a matter of fact (see Chapter II., 'Normal Conjunctiva') be found in the conjunctiva (*Subtilis* group). In a case of insidious late infection in a cataract case (Hess), where the wound did not heal well on account of a capsule inclusion, Römer,[5] after two punctures of the anterior chamber, succeeded in demonstrating spore-forming organisms of the *Subtilis* group. They did not liquefy, but possessed all the other characteristics and caused severe inflammation in the vitreous. The great difference in the recorded results of Perles, Lobanow, and Ulbrich, concerning one and the same organism, depends partly on its variability in character and virulence, and partly on the difference in the methods of research employed. Perles attempted to infect perforating wounds with the loop, and perhaps the organisms did not adhere. The other authors preferred injections which are certain to introduce large numbers of the organism into the eye even when only small doses are given (Ulbrich used 0·04 c.cm.). Bietti[6] emphasizes the fact that in human pathology we cannot unreservedly give the significance to these organisms which the results of their experimental inoculation might seem to imply.[7] He also showed that small doses would act pathogenically. Perles' inoculations with the loop, therefore, much more nearly correspond to the conditions in man than do injections. Inoculated with the loop, many otherwise pure saprophytes produce a vigorous reaction in the anterior chamber—*e.g.*, *B. radiciformis*, *megaterium*, *mycoides*, *subtilis*, *fluorescens*, *liquefaciens*; others do so to a less degree.

While we must bear the possible action of many saprophytes in mind, with reference to the eye we note that the great majority of

[1] What changes result from the injection of bacteria, hefæ, moulds, and toxins into the anterior chamber? (*Arb. aus dem Kais. Gesundheitsamt*, 1905, xxii. 411).

[2] *A. f. O.*, 1904, lviii. 243.

[3] The predilection for the vitreous does not occur with all organisms.

[4] An injection of spores alone caused suppuration in the vitreous, but not in the anterior chamber. The spores were only able to develop in the vitreous.

[5] *Cf.* Ulbrich.

[6] *Ann. di Ottal.*, 1906, xxxv. 1.

[7] *Cf.* also Leber, *A. f. O.*, 1904, p. 324.

those organisms quoted in the review by Brandts only occur scantily on the conjunctiva on rare occasions. The more common *Sarcinæ* cannot multiply in the eye. Individual examples of the *Subtilis* group are found fairly frequently on the conjunctiva. The cases, however, of infection with *Subtilis* so far recorded have mostly been due to direct infection from a soil-contaminated foreign body.

The Changes which result from an Infected Wound of the Eye.

The examination of human eyes with infected wounds should show to what extent saprophytic inflammations occur, especially how far Ulbrich's view that they are responsible for the subacute and chronic forms (**Iridocyclitis**)[1] can be confirmed.

The material is rarely accessible to bacteriological research, and, with the exception of the quoted case of Hess and Römer (*Subtilis*), we have only the following records: Hirschberg and Frosch[2] cultivated *Pneumococci;* Cuénod[3] obtained the same. I have on one occasion cultivated very small Gram-negative bacilli, which would only grow on blood media, and were closely related to the influenza group;[4] on another occasion *Staphylococcus pyogenes albus* of moderate virulence. There is evidence in favour of the other possibility brought forward by Ulbrich, **that pyogenic organisms can also cause insidious inflammations** (Leber, Deutschmann). A wound infection of this kind which, even after several weeks' duration, did not lead to panophthalmitis, has been examined in my clinic, and in it Brons found the *Bacterium coli liquefaciens* (*Bacterium punctatum*), an organism which till then had never been recorded as pathogenic, but had only been found in water.[5]

This question appears of great interest to me: How far should we fear an infection from the ordinary saprophytes of the conjunctiva? and to what extent has such been observed?

If we consider the common white *Staphylococci* of the normal conjunctiva (see chapter on 'Normal Conjunctiva') as belonging to this class, we note that Gifford

[1] Aqueous fluid from the living eye is only very occasionally available for examination; it is not permissible to open the vitreous chamber for the purposes of obtaining material for inoculation. Living eyes under these circumstances are therefore rarely available, and those which are enucleated are usually in such an advanced stage that a bacteriological examination is unsuccessful (*cf.* p. 4).

For these reasons the question as to whether any mode of treatment (*e.g.*, Schirmer's mercurial treatment) is of use against a definite organismal wound infection cannot be decided by the findings in the human eye, but at best merely by experimental methods.

[2] Heidelberg Congress, 1892: discussion on Greeff's communication.

[3] *Compte Rendu de la Soc. Franç. d'Ophth.*, 1895, p. 534.

[4] Dissertation of Oertzen, Rostock, 1898, 'Über Pneumokokken' (Schluss).

[5] Schirmer (Internat. Ophth. Congress, Utrecht, 1899) attributed a number of subacute infections to impure boric lotion.

obtained only a slight reaction when he injected small amounts into the vitreous; often only a transient cloudiness occurred. Nevertheless Rupprecht and myself have shown that subacute cataract-infection occurs in the human eye from infection by white *Staphylococci*, which cause no reaction in the rabbit's cornea. These cocci may perhaps find a specially favourable medium in the aqueous mixed with lens matter, the more so when the power of resistance is low.

In an eye with iridocyclitis, after cataract extraction and prolapse of vitreous, Gourfein[1] found the *Micrococcus candicans—i.e.*, the white non-liquefying *Staphylococcus*.

Many strains of *B. xerosis*, the commonest of the conjunctival flora, do not possess the power of active multiplication in the interior of the rabbit's eye. With Dr. Vogel[2] I have injected a number of these strains into the vitreous. When in great numbers they cause an inflammatory infiltration, varying in degree; but in a few days only degenerate bacilli can be found, and in cultures very few colonies were obtained. After about a week all was sterile. With very small injections of other strains, Bietti[3] obtained the same result. Although we are not justified in attributing to the majority of the conjunctival xerose bacilli the power of infecting wounds, yet there are here and there strains which can grow in the interior of the eye, and can remain alive there for a considerable time. This is shown by the experiments by Deyl and Demaria,[4] and in cases of wounds recorded by Kastalska, Gourfein, and D. Smith, such bacilli were obtained. The first two authors had cases of panophthalmitis in the full sense of the word. It would have been interesting had controlled inoculation been made with small quantities of these bacilli to determine the power of reproduction.

I would like to note here that the inflammatory reaction produced by these pseudo-diphtheria bacilli is not influenced in the slightest degree by diphtheria antitoxin.

The following bacteriological researches are available on the question of **post-operative panophthalmitis** in the human eye:

Staphylococcus pyogenes aureus: Cases by Leber, Sattler (Internat. Ophth. Congr., 1889), Weeks,[5] Terson and Gabrielidès,[6] De Schweinitz[7] (*Staph. pyog. citreus* and pseudo-diphtheria bacilli).

Ozæna or *Pneumobacillus:* Cases by Terson and Gabrielidès (*cf.* p. 242).

Xerose bacilli or *bacilli of the diphtheria group:* A few cases (Kastalska, Gourfein, *loc. cit.*).

Pneumococci: Cases by Gasparrini,[8] Ewetski,[9] Mundler,[10] Oertzen,[11] Kuhnt,[12] Schirmer and Flatau,[13] Schmidt and Hirota,[14] Johnston,[15] Woods and Johnston,[16] Taylor,[17] Duclos[18] (the last-named seven cases).

Besides the two published cases by Oertzen, from 1897 to 1907, I

[1] *Revue Méd. de la Suisse Romande*, January, 1904.
[2] Inaug. Dissert., Freiburg, 1906.
[3] *Ann. di Ottal.*, 1906, xxxv. 1.
[4] Levy and Fukler speak in a similar way of a *Corynebacterium pyogenes* (*cf.* Lewandowski, *Zent. f. Bakt.*, 1904, xxxvi. 369).
[5] Arch. of Ophth., xxi. 22.
[6] *Arch. d'Ophth.*, 1894, xiv. 488.
[7] Ophth. Rev., 1896, p. 32.
[8] *Atti della R. Acad. dei Fisiocrit.*, 1894, v. 48 (Siena).
[9] *Wjestnik Oftal.*, 1895, p. 222.
[10] Ziegler's *Beiträge*, 1897, xxii. 248.
[11] *K. M. f. A.*, 1899, p. 432.
[12] *Zeit. f. A.*, 1899, p. 52.
[13] *Ibid.*, 1903, ix. 213.
[14] *Ibid.*, 1902, vii.
[15] Med. News, 1904, 85.
[16] Ophth. Rec., 1904, p. 149.
[17] T. O. S., 1903, p. 130.
[18] *Ann. d'Ocul.*, 1905, cxxxiv. 409.

have seen five more cases of panophthalmitis from pneumococcal infection after cataract, and three from *Staphylococcus aureus*, in one of which the infection spread from a conjunctival suture.

Streptococci: Two cases by Duclos (*loc. cit.*), one of which had also influenza bacilli.

The Pneumococcus therefore is by far the most important organism in post-operative infection of the globe. A dacryostenosis, a conjunctivitis, occasionally the *Pneumococci* of the normal conjunctiva, and the sputum (Flugge),[1] which may infect sterilized instruments, form the sources of contamination. Hotta[2] infected rabbits' corneæ with sputum, and in about one-third of the cases pneumococcal infection resulted.

Transference from the mouth or nose can only occur by external contact. Under no circumstances can the pneumococcal infection pass through the healthy *ductus naso-lacrimalis* (Bach),[3] nor can they pass up when there is a permeable stricture (Hauenschild).[4]

In the case of **panophthalmitis after wounds** the conditions are somewhat different. Pneumococcal infection is not so preponderant in these cases, as in many cases the body causing the wound carries with it the organism which produces the reaction.

Streptococcus pyogenes here plays an important part (Gallenga,[5] Deutschmann, De Schweinitz,[6] Enslin and Kuwahara, *loc. cit.*). I have grown it five times.

Pyogenic staphylococci: (Leber, Sattler, Gallenga). I have grown them many times.

Pyogenic bacilli are often found: *Subtilis* and its allies (*vide supra*);[7] also *B. pyocyaneus* (Sattler,[8] Hanke[9]), *B. coli* (Randolph[10]).

B. pyogenes Passet (Monti, Scimeni, Gallenga[11]). The bacillus grown by Finlay[12] must be classed here. Chaillous[13] found an anaerobic pyogenic bacillus—the *B. perfringens*—in the vitreous in two cases of traumatic panophthalmitis after splinter wounds. In both cases

[1] *K. M. f. A.*, 1903, Bd. ii., p. 474.
[2] *Ibid.*, 1905, Bd. ii., p. 237.
[3] *A. f. O.*, xl.
[4] *Ophth. Klinik*, 1898, No. 16.
[5] *Rassegna di Scienza Med.*, 1888, p. 1.
[6] Ophth. Rev., 1896, p. 32.
[7] Urbahn reported that he had occasionally grown *Proteus* (*Ophth. Klin.*, 1903, p. 226).
[8] Ophth. Congr., Heidelb., 1892.
[9] *Zeit. f. A.*, 1904, x. 373. Hanke recorded his findings as *Bacillus proteus fluorescens*. According to MacNab (*K. M. f. A.*, 1905, ii. 542), it really was *B. pyocyaneus*.
[10] Am. Jour. of Med. Sciences, 1893, p. 440.
[11] *Cf.* Gallenga, *Rassegna di Scienza Med.*, 1888, iii. 2.
[12] *Ann. d'Ocul.*, 1893, t. cix., p. 130.
[13] *Ibid.*, August, 1905, cxxxiv. Till then this bacillus was only found in appendicitis, otitis, gangrene of the lung, and putrid sinus empyema, and always mixed with other bacteria; but here pure cultures were found in the eye. Veillon and Morax found another anaerobic bacillus in a case of dacryo-pericystitis gangrænosa.

there were fever and vomiting. From a slide which was very kindly sent me Fig. 5 on Plate III. is prepared.

The bacilli appear in the secretion as large (1 μ by 3 to 9 μ) Gram-positive bacilli, often granular and staining irregularly, sometimes growing in filaments, and in form and size greatly resembling the *B. subtilis* depicted alongside, from which indeed, they cannot be microscopically distinguished with certainty. The two figures differ considerably, but *Subtilis* can also show similar appearances in pus to those of the *Perfringens* here depicted, and vice versa (*cf.* figure in text, p. 80) The bacilli are surrounded by clear spaces, which however, are not true capsules, but a retraction of the medium. They have no spontaneous movement and no spore formation. Growth is only anaerobic. Free gas-formation occurs on sugar media ; in bouillon clouding, with formation of a deposit. Offensive smell in all cultures. On agar small, flat, grey colonies. Gelatine not liquefied. Subcutaneous injection causes an emphysematous inflammation in guinea-pigs, but not in rabbits. Injection into the vitreous of rabbits causes panophthalmitis, into the anterior chamber a purulent iritis.

In microscopic preparations of the enucleated globe dense masses of bacilli are found, but only at some distance from the vessels, corresponding to their anaerobic nature.

The *B. perfringens*, first described by Veillon and Zuber,[1] must always be considered, as well as *Subtilis*, when dealing with large Gram-positive bacilli in pus, and in such cases it is advisable to make an anaerobic culture. On account of the omission of cultures Chaillous was doubtful whether this organism was present in two further cases of '*panophthalmie gazeuse*' recorded by Darier (*La Clin. Ophth.*, 1906). In another case of '*ophthalmie gazeuse*' enucleated by Gayet, Arloing cultivated bacilli from the fluid obtained by puncture. These were very small, resembling those of mouse septicæmia, and produced an inflammatory emphysema in guinea-pigs (Soc. de Biologie, November, 1887 ; quoted by Gabrielidès).

Regarding panophthalmitis following a direct **perforating wound** with a **pneumococcal infection,** see cases by Gasparrini, Lucciola,[2] Cuénod (*loc. cit.*), De Lapersonne and Painblau,[3] Mayweg,[4] and Lagrange.[5] I have often seen such an infection. If we add to the cases of wound infection those in which septic hypopyon-keratitis,[6] especially ulcus serpens, follows on an abrasion of the epithelium, then pneumococcal cases form the great majority of wound

[1] *Arch. de Méd. Expériment.*, 1898.
[2] *Ann. di Ottal.*, 1893, xxi. ; *Giorn. Med. di R. Esercito*, August, 1896.
[3] *Rev. Gén. d'Ophth.*, 1897, No. 6 ; *Thèse de Lille*, 1897.
[4] *Cf.* Axenfeld, 'Serumtherapie Infekt. Augenerkrankungen,' Freiburg, 1905.
[5] *Recueil d'Ophth.*, 1901, p. 551.
[6] See chapter on 'Cornea' for such corneal infections, also for other forms of traumatic infective keratitis, and those from the moulds (*Aspergillus fumigatus*). We should here note that in rare cases a perforating mould infection has been observed (Leber and Nobbe, Römer, Kampherstein, Schirmer). In Römer's cases cultures of *Aspergillus fumigatus* were obtained.

infections, as they also do when we include in the total the panophthalmitis developing out of a corneal sepsis. (Panophthalmitis resulting from reinfection of old adherent scars belongs in part to this group.)[1]

Prophylaxis in Affections of the Lacrymal Passages, Conjunctiva, or Lids.

Special emphasis must be laid on the preventive treatment of the source of the infection, particularly if it be pneumococcal—such as a conjunctivitis, and more particularly in the working classes, a dacryocystitis. In all cases where conservative measures fail to secure the removal or destruction of the infection, especially in the case of the labouring classes, a radical extirpation of the sac is usually the best procedure. What, then, will be the condition of the conjunctiva with regard to its bacterial contents and its infectiousness after excision of the sac?

We have already shown that the flow of the tears is an important factor in the self-cleansing of the eye; yet in such cases this is permanently interfered with. Can we then consider the condition after excision as comparatively favourable with regard to infection? The condition improves after the operation, because a stagnation and multiplication of the organisms previously occurred above the stricture in the nasal duct, and from this source infected material could find its way backwards into the conjunctival sac. Of course there is a stagnation in the conjunctival sac after the operation, but there is obviously a radical difference if the interruption is above or below the lacrymal sac. In the lacrymal sac the conditions are most favourable for the growth and increase in virulence of organisms, especially the *Pneumococcus*—the commonest and most dangerous one for the eye—not only because the temperature of the sac exceeds that of the open and moist evaporating conjunctiva, but also because the constant washing with sterile tears ceases as soon as a complete stenosis occurs. No further fluid can find its way into the sac when it has already been filled and cannot empty itself. The fluid in the sac, too, is a better nutritive medium, the more so when a catarrh of the sac causes an increase in its organic contents.

From clinical experience and the bacteriological researches which Plaut and Zelewski[2] carried out at my instigation, we know that, a few weeks after an extirpation, provided such has been perfectly accomplished, the conjunctiva has become relatively safe from infection, and can be satisfactorily cleansed. The interval between the sac operation and any other must not be made too short; and it is wrong to lay down any hard-and-fast time for every case, for the conjunctiva and the lid margins in patients with dacryocystitis are

[1] *Cf.* Wagenmann, *A. f. O.*, 1889, xxxv. 116; Terson, *Ann. d'Ocul.*, 1898, cix. 116; Dolganoff and Sokoloff, *A. f. A.*, 1903, xlvii. 361.

[2] Shutting off the sac by cauterization of the canaliculi is a protective measure; in my experience this closure, however, is not quite reliable (*K. M. f. A.*, 1901, xxxix. 1, p. 369.

often greatly changed, and will require some special treatment. Microscopic control of the conjunctival secretion is the only method of determining when operative procedure is safe after a sac excision. In those cases where there is a severe blepharo-conjunctivitis, trachoma, or such-like condition as well, the extirpation of the sac will only improve matters; it will not of itself be sufficient.

The danger of infection increases with any pathological condition of the conjunctiva, and renders some preliminary treatment necessary before operations. We should pay attention to the *Diplobacilli* when found in the secretions of such cases. Post-operative infections with this organism have not yet been recorded, but as both the Morax-Axenfeld and the Petit types can cause severe hypopyon-keratitis in the history of which a trauma often occurs, their preliminary cure with zinc is advisable.

A preparation should be made from the conjunctiva of every patient before an operation on the globe, especially a cataract extraction, even though the conjunctiva be healthy. The loop is passed over the lower fornix and close up to the caruncle; some moisture, with a few cells, is thus always obtained. If no organisms can be found in this, or should there be merely xerose bacilli or scattered *Staphylococci*—*i.e.*, small *Diplococci*—there is nothing against an operation; but if *Pneumococci* be present—and they will be recognized by their elongated shape—a delay of a few days for treatment with zinc is necessary, and then the condition controlled until they disappear. L. Müller[1] and Stedman Bull[2] also treat their cases in this way.

With regard to the possibility of a wound becoming infected from the lid margins, especially the cilia, it is interesting to note that eyelashes driven into the interior of the eye have almost never caused a septic reaction. This is clearly shown in the profuse literature concerning the implantation of cilia in the iris and anterior chamber, with cystic formation resulting. L. Müller planted cilia in the anterior chamber of rabbits, and they always healed in without irritation.

On the other hand, a few cases are recorded of abscesses in the conjunctiva due to cilia forcibly driven in (Hummelsheim, *Zent. f. A.*, 1895, p. 567; Günsburg, *Wjestnik Oftal.*, 1897; Kraisky, *ibid.*, 1902, p. 364, quoted by Saemisch). Logetschnikow, however, found cilia in the conjunctiva without suppuration; so also did Uhthoff, but in his case a cyst formed. Cilia are often found healed into this structure.

Schioetz[3] goes too far when he considers it necessary, before operation, to epilate even quite healthy lids, and lays too much weight on the findings of Holth, who cultivated *Staphylococci* from the cilia. The roots of the hairs do not cause so much danger as he thinks. Experiments have shown that the healthy cilia are quite sufficiently purified, even though the lid margins are not quite sterile, by the more energetic methods of cleaning and disinfection which are still

[1] *K. M. f. A.*, 1901, xxxix., Bd. i., S. 369. [2] Tr. Amer. O. S., 1904.
[3] Internat. Med. Congress, Section for Ophth., 1900.

possible (Gifford, Bach), especially when these are combined with the action of some substance which dissolves fat (benzene or alcohol, according to Pflugk[1]), or with an antiseptic dissolved in oil (Panas[2]).

It is different in lids inflamed by the various forms of blepharitis. Here pyogenic organisms are much more plentiful, especially *Staph. aureus*. A preliminary treatment is necessary before operation.

The Serum Treatment of Infected Wounds.

When in cases very liable to infection (general debility, diabetes, etc.) *Pneumococci* are found to be numerous, or when the operation has gone badly, I give an injection of 10 c.cm. Römer-Merck's anti-pneumococcal serum (*vide infra*) either just before or immediately after the operation. I do this even although repeated experiments, which I have carried out with Drs. Zade and Brons, have shown that the interior of the eye partakes to but small degree in the general pneumococcal immunity, be that active (including the so-called 'aggressin' immunity), passive, or simultaneous, even although the experimental animal be immunized with the actual *Pneumococcus* used for infection.

The results of *infecting the anterior chamber* with highly diluted cultures did not differ in the immunized animal from the control. At most only in a few instances was a slightly milder suppuration produced.

In similar *infections of the vitreous* the influence was even less apparent. This is what would have been expected, for Römer and Wessely have shown that protective bodies of the hæmolysin (cytotoxin) group do not pass into the vitreous;[3] and, according to the latest results of Wessely, only repeated tappings of the anterior chamber can cause a transference of albumin into it. To a less extent even can the passage of precipitins occur (von Dungeon). (Receptors of the second order—complements—according to Possek,[4] are present in the vitreous.) A passage of hæmolysin into the anterior chamber cannot be demonstrated under normal conditions, but after irritation (subconjunctival injections of saline, tapping of the anterior chamber) such may occur. Römer and Rymowicz obtained a positive result in the case of many agglutinins—*e.g.*, for typhoid agglutinin—even in the absence of irritation. Schneider[5] found small amounts of alexins in the aqueous. The

[1] *A. f. A.* 1902, xlv., S. 176. The benzene also possesses a certain antiseptic power. Gifford (Jour. of the Amer. Med. Assoc., October, 1903) could not demonstrate that the lid margin could thus be quite sterilized. Cocci remained in the mouths of the follicles.

[2] *Acad. de Méd.*, Paris, September, October, 1893, and *Arch. d'Ophth.*, November, 1893.

[3] According to Possek, however (*K. M. f. A.*, 1907, i. 339), an immune serum can be obtained in rabbits by subcutaneous injection of vitreous substance, and this serum contains hæmolytic amboceptors. His results contradict those of Paul (*K. M. f. A.*, January 1, 1907), who made similar experiments.

[4] Possek, 'Über die Antigenetische Wirkung des Glaskörpers,' *K. M. f. A.*, 1907, i. 329.

[5] *Münch. Med. Woch.*, 1907, p. 146.

latest work of A. Leber[1] with typhoid and cholera show that the amount of protective bodies in the anterior chamber, which though still perceptible, is normally very low, is considerably raised by any irritation.

It is remarkable that it was higher in the case of passive than in the case of active immunity, although the serum is richer in protective substances in the latter than in the former. These are, perhaps, retained more in the blood in active immunity. The aqueous of the immunized animal showed only a very feeble bacteriolytic action. Schneider (*Münch. Med. Woch.*, 1907, p. 146) reports the complete absence of alexin (hæmolysin, bacteriolytic or bacteriotropic substance) in the normal aqueous of an immunized animal. These bodies were only found after tapping.

R. Possek[2] has carried out further researches into the cytotoxin contents of the vitreous in normal and immunized subjects. Although diffusible substances slowly pass into it from the blood, this does not occur with antibodies. The normal vitreous is wanting in the antibacterial power possessed by the blood-serum; and, further, it has no hæmolytic power, such as the serum of the pig, for example, has on bullock's blood. Neither does the vitreous participate in any artificially produced increase in hæmolytic power of the serum. Possek's results confirm the principle laid down by Römer[3] of 'the retention of cytotoxins by the secretory apparatus of the eye.' It was only after repeated saline injections and tappings of the anterior chamber that traces of hæmolysin could be found in the vitreous, as was shown by Wessely,[4] although such substance could readily be found in the anterior chamber after slight irritation. Investigating the occurrence of bactericidal substances in the eyes of a series of non-immunized individuals, and working with the bacilli of dysentery, Zur Nedden[5] found the normal aqueous and vitreous not to be bactericidal, but merely bad media for growth. Bactericidal material, however, entered the anterior chamber after puncture, and similarly but more slowly, after loss of vitreous into that chamber. Congestion of the eye or head by Bier's method produced no bactericidal increase, though an inflammatory condition of the globe did.

If we assume that a similar condition obtains in the human subject, then prophylactic pneumococcal immunity after cataract operation may have a certain value, as the opening of the eye and the whole procedure causes a flow from the vessels, both into the interior and also outwards, with which there may be some access of protective substances. Should any inflammation occur, the reactionary exudation from the vessels and our serum treatment will have still more influence in this direction. The cornea, too, according to Römer, participates to a high degree in the immunity. Serum treatment, therefore, can be of value. We cannot, however, affirm that its restraining action is at all equivalent to the influence which the opening of the lens capsule has in favouring an infection.

[1] 'Immunitätsverhältnisse der vorderen Augenkammer,' *A. f. O.*, 1906, lxiv. 413 (see here collected literature).

[2] *K. M. f. A.*, 1906, Bd. ii.

[3] *A. f. O.*, 1905, lx., 'Die Cataracta senilis vom Standpunkt der Serumforschung.'

[4] *Deutsch. Med. Woch.*, 1902, and 'Flussigkeitswechsel im menschl. Auge' in 'Ergebnisse der Physiologie,' 1905.

[5] *A. f. O.*, 1907, lxv., S. 267.

We obviously cannot bring any certain proof that such injections have protected any individual case. I have never had a pneumococcal infection in an immunized patient. In estimating the value of the protective power which we thus desire to produce, it would be of special value if cases of pneumococcal suppuration in patients thus treated with serum were to be observed.

An intra-ocular pneumococcal suppuration, when already developed, either in experimental or clinical cases, *is not influenced at all by any serum treatment yet devised.*[1]

Rymowicz's[2] results with the more commonly applied streptococcal immunity are rather more favourable. He immunized the cornea by previous serum injections. Simultaneous injections caused a corneal infection to heal up slowly; later injections had no effect. Previous injections alone protected against infections of the anterior chamber. Previous immunization had a very doubtful influence on eyes which were infected after the lens had been extracted. No curative action could be obtained in such cases by later injections. Streptococcal serum is much less often useful in cases of wound infection. Such prophylactic measures were recommended in 1896 by Boucheron (*Soc. de Biologie*, April, 1896). Rogman, Angelucci,[3] and Attanasio,[4] recommend injections of pneumococcal or streptococcal serum in all suspicious cases. (This should certainly be done, on account of the danger of a general infection, in severe conjunctival or corneal lesions due to *Streptococci.*)

Rymowicz had analogous results with staphylococcal serum; but Paltschikowski[5] was quite unable to modify staphylococcal infection of the anterior chamber by immunization.

Löffler, working with chicken cholera, and Römer with *Pneumococci*, have experimentally shown that the cornea participates not only in any general *antitoxic* immunity — *e.g.*, against diphtheria toxin (Römer)—but also in an antibacterial immunity. It was possible by active, passive, or simultaneous immunization, to protect the cornea against anything less than a very large dose of virulent *Pneumococci.* A curative action, was, indeed observed in animals, but to a much less degree than the prophylactic. On this Römer based a serum-prophylaxis and a serum treatment of pneumococcal infection of the cornea, especially the ulcus corneæ serpens. This affection should here be noticed, as it usually results from the infection of small corneal

[1] Axenfeld, 'Serumtherapie infektiöser Augenerkrankungen,' Freiburg, 1905 (U. Hochreuther), p. 76. In the future larger doses must be tried.

[2] *Wjestnik Oftal.*, 1903, Nos. 4, 5.

[3] *Arch. di Ottal.*, 1902, x. 79.

[4] *Ibid.*, 1902, ix. 401.

[5] Quoted by A. Leber, *loc. cit.*

THE ASIATIC SOCIETY OF BOMBAY LIBRARY

wounds. The difficulties which lie in the way when preparing an efficient serum, the theoretical grounds for its action, and the experience of its use, will be given in the chapter on the 'Cornea.'

Deutschmann (*Münch. Med. Woch.*, 1907, No. 22) has lately brought forward a serum which he considers very valuable for wound infections of varying nature; it is produced by the injection of *Hefæ* into animals. The cases yet published do not allow us to form a definite conclusion regarding it. Details of experiments on animals are not given, and further information must be waited for.

In those rare cases where **Tetanus**[1] has followed a wound of the eye or its appendages, which begin with that pecular clinical facial type of the disease, the *Bacillus* has been several times demonstrated by pure cultures, or by inoculations. With a splinter of wood removed from the orbit Michel obtained a typical infection in a mouse. Pes found *B. tetani* on fragments of rushes in an orbital exudation, and Ramsay found them in pus from a wound. Öller, on the contrary, could not find any organisms. Ulbrich rightly tried the result of an anaerobic bouillon culture of a portion of the tissue in such a case, injecting $\frac{2}{10}$ c.cm. of the bouillon, two days old, into a mouse. The animal died of tetanus, thus proving the case. Ulbrich has experimentally demonstrated that tetanus is not produced by a pure culture of *Bacillus tetani* in the vitreous or anterior chamber. An intentional mixture with *Subtilis*, which always had a positive result when injected subcutaneously, produced no tetanus. Only once did such occur by a chance contamination. In the eye itself the reaction was only slight, although the bacilli were present till the eighth day, and their spores for five weeks.

The antitoxic sera of Behring, Kitasato, and Pasteur can be used in treating tetanus. Their effects are uncertain when the disease has broken out. Kocher and E. Levy, therefore, advocate the use of these sera in injuries which have been infected with earth and dirt.

[1] Marx, Inaug. Dissert., Berlin, 1893. Fromaget, *Archives d'Ophth.*, 1894, xiv. 658 (see here the older literature). Chevalier, *Thèse de Bordeaux*, 1894. Keiper, *Ann. of Ophth.*, 1895, iv. 336. Santos Fernandez, *ibid.*, 1896, v. 335. Darier, *Ann. d'Ocul.*, 1897, cxvii. 444. Öller, *Arch. f. Augenh.*, 1905, li., S. 121. Ulbrich, *Verhandl. d. Ophth. Gesellsch. in Heidelberg*, 1905, S. 256. Wagenmann, *ibid.* Schmidt-Rimpler, Ophth. Kongr., Heidelberg, 1904. Genth, *Zeit. f. Augenh.*, 1903, ix., S. 55 (*cf.* here cases of Dahlhaus, Pollack, Schnitzler, Roberts). Axenfeld, 'Serumtherapie Infekt. Augenerkr.,' Freiburg, 1905, S. 28. Newman, Brit. Med. Jour., 1904, ii., S. 1519. Ramsay, A. M., The Ophthalmoscope, 1905, iii. 537. Michel, *Berl. Ophth. Gesellsch.*, September, 1905, ref. *K. M. f. A.* Worms, *Thèse de Lyon*, 1905 (*cf.* here further literature). Gerok, Koenigshoefer, E. Levy, 'Vers. Württ. Augenärzte,' *K. M. f. A.*, January, 1907, Bd. i. Mayweg, *K. M. f. A.*, July, 1907, Bd. ii.

Endogenous Wound Infection.[1]

A trauma, such as an operation, can act as the cause which determines the settling down of circulating micro-organisms. In practice it is difficult thus to explain infections, as we must exclude their entrance through the wound. Ectogenous infection is most likely in wounds which show septic inflammation during the first few days. For those infections which only show after the wound has closed, and after an initial non-inflammatory stage, the possibility of an endogenous origin becomes more and more insistent the longer the time which elapses after the closure of the wound. We must in such cases note the following points:

1. Paths of infection may remain in apparently closed wounds, along shreds of capsule, iris inclusions, etc.

2. A certain latent period is possible in ectogenous wound infections.[2] The organisms introduced must reach a certain number, and their action a definite degree, before they become obvious. The ectogenous suppuration developing in the space left by a cataract operation for this reason first shows itself several days later.

In the case of purulent inflammations this latent period in the eye, especially after cataract operation, varies within very narrow limits, not only in the case of *Pneumococci*, which are usually the organisms under consideration, but also of the other pyogenic forms more rarely found. In dealing with these organisms it is very soon apparent whether the eye will overcome them, or whether they will find a good nidus therein. Resistant Bacteria, whose spores take several days to develop into the growing form and cause suppuration, have never been observed after operations. Only once has a late inflammation been observed in a case by Hess (*Pathologie der Linse, Handb. Graefe-Saemisch*, 2 Aufl., 1905), in which *Subtilis* was found. Suppuration due to *Subtilis* in splinter wounds has generally developed rapidly after the injury, and experimental infections by means of its spores have shown no latent period (Ulbrich, Stregulina).

We find, when we examine them further, that the cases to which *point 1* refers include the most of those eyes with adherent scars which are affected by an apparently spontaneous deep suppuration, generally leading to panophthalmitis. Leber and Wagenmann[3] have proved microscopically that in eyes where the adherent cicatrices seemed quite unaffected the infection none the less had passed

[1] *Cf.* section on 'Endogenous Infection.'

[2] Terrien's experiments show that latent miliary abscesses may remain for days in the regenerated epithelium, and cause late infection (*Arch. d'Oph.*, 1905, xxv., p. 360).

[3] *A. f. O.*, 1891.

along them into the deeper parts, having arisen in an epithelial lesion which possibly had rapidly healed again. Terson[1] and others have recorded further examples of this, and in several cases I have been convinced that this was the case. It cannot be denied that circulating organisms can settle in such eyes as a *locus minoris resistentiæ*.[2] Such a mode of infection, which has been emphasized by E. Meyer, is certainly very rare. These late infections of adherent scars have mostly been due to chain-forming cocci and *Pneumococci*. Experimental inoculations into adherent scars in the rabbit's cornea have been made by Dolganow and Sokolow (*A. f. A.*, 1903, xlix., p. 361).

All these circumstances must be taken into account when discussing endogenous infection in any wounded or perforated eye, and we must not presume that any individual case is endogenous without very strong evidence, especially if there be no indication of any disease predisposing to metastasis.

Cases which were probably endogenous complications of a wound, are recorded by Axenfeld[3] (in the case of a woman who some days previously had had a pleuro-pneumonia, with splenic enlargement; on the twelfth day, after a cataract operation, a deep suppuration occurred); by Hjort (two cases of suppuration during influenza); by Panas and Weeks (deep suppuration after a pure contusion); Stock (twenty days after healing of an operation wound, deep pneumococcal suppuration during influenza—*K. M. f. A.*, 1906, ii., p. 431); and Wopfner (pneumobacillary metastasis in a case of cataract extraction—*K. M. f. A.*, 1906, xliv., p. 386). In the literature of cataract occasional cases are recorded.

This factor must only be considered as very occasional, and wound infection must generally be attributed to ectogenous infection.

Endogenous wound suppuration has been experimentally produced by Panas (Soc. franç. d'Oph., 1897), Tornatola (*Ann. di Ottal.*, 1899, xix., p. 480), and von Koratkow (*Wratsch*, 1903, No. 50; *Ann. d'Ocul.*, 1904, cxxxii., p. 152). They induced a septic pyæmic condition in animals (Panas with *Bac. coli* and Tornatola with pyogenic cocci), and then subjected the eye to a trauma (Panas by an injection of nicotine, Tornatola by a perforating wound). Suppuration occurred on the injured side. Moll (*Zent. f. A.*, August and December, 1899) obtained the same result with *Pyocyaneus*.

The researches of Stock (*K. M. f. A.*, 1903, xli., 1, p. 81), Selenkowski and Woizechowski (*A. f. A.*, 1903, xlvii., p. 299) have shown that metastases in the eye, usually double-sided, very readily occur in rabbits whose blood has been infected with virulent organisms. In the case of Selenkowski and Woizechowski, who worked with subvirulent organisms, the localizing influence of an

[1] *Ann. d'Ocul.*, 1898, cix. 116. [2] *A. f. O.*, 1894, xl. 2, p. 113.
[3] *Ibid.*, xl. 3.

irritant or foreign body was very obvious. Koratkow states that an operation wound only acts as a localizing site for endogenous infections during the first few hours; later there is no difference between the operated and the normal eye. Experimental endogenous wound infection results in the uvea either from embolism or from the cut vessels. Koratkow ascribes a favouring influence to post-operative detachment of the choroid. (For human eyes this latter statement is doubtful.) The possibility, therefore, of an irritant as a localizer is experimentally demonstrated.

There is also the possibility that endogenous tuberculosis, syphilis, and other processes, can become localized in a wounded eye. This question is now being freely discussed in regard to keratitis parenchymatosa, but there has not yet been any bacteriological research on the subject.

The experiments by which Tornatola[1] sought to prove that a toxic wound suppuration could occur in the eye must be considered to have failed. Shimamura[2] conducted many experiments in my laboratory, and proved that, on subcutaneous or intravenous injection of the toxins of *Staph. aureus*, *Streptococcus*, or *B. coli*, suppuration or inflammation of an injured eye never results, provided that the most scrupulous care be exercised regarding asepsis at the site of injury, and the prevention of secondary infection. Valenti[3] has lately described an endogenous toxic inflammation artificially occurring in the conjunctiva after subcutaneous injections of the toxins of *B. coli*. There was no change in the eyeball. His whole work, and especially the question whether any wound inflammation can thus be caused experimentally, requires further investigation.

The cases described by Tornatola, Lagrange,[4] Gasparrini,[5] and Rothenpieler[6] as toxic metastases will not stand criticism, and cannot be taken as proof that purulent inflammation can occur in wounds from endogenous toxic infection. **Whenever suppuration occurs in a wounded eye we must consider, with our present knowledge, that organisms are there present.**

The more chronic forms of inflammation, especially those of a seroplastic nature, are possibly due to endogenous toxic causes, for in the pathology of other organs we have analogous local inflammations due to circulating poisons. Such an endogenous toxic inflammation of a wound has never yet been demonstrated, and in any individual case

[1] 'Le Inflammazione Postoperatoria in Oculistica,' 1900 (Messina).
[2] *K. M. f. A.*, 1902, xl. 1, pp. 229, 273.
[3] *Arch. di Ottal.*, 1900, viii. 20.
[4] Congrès de la Soc. Franç. d'Ophth., 1896, p. 370.
[5] *Ann. di Ottal.*, 1895, xxiv. 343.
[6] *Zent. f. A.*, 1897, p. 304.

it would be very difficult to do so and exclude an insidious ectogenous infection.

In the literature many accounts of such non-bacterial inflammations of wounds are found: Vignes (*Ann. d'Ocul.*, 1896, cxvi., p. 376) and Rockliffe and Nettleship (T. O. S., xvi., p. 352) describe such cases. See also Wagenmann (*A. f. O.*, 1896). Similar changes are ascribed to diabetes.

Dolganow (*A. f. A.*, 1896, xxxii., p. 262) reported having experimentally demonstrated that the toxin of *Staph. aureus*, circulating in the blood after repeated injections, could cause an infiltration of the optic nerve and choroid. This, however, has not yet been confirmed. Certainly a slight infiltration of the choroid can occur in the human eye without any demonstrable metastatic deposition of organisms (Goh, *A. f. O.*, xliii., 1, p. 147, and preparations by Yamaguchi).

The effects on the eye produced by the toxins of the pyogenic organisms circulating in the blood, tend towards hæmorrhagic changes in the retina, and this is what is invariably found clinically.

In the case of insidious wound infection, especially in iridocyclitis traumatica, the possibility of the introduction from without of an organism of long latency must be very carefully considered. The causal agent in this condition is almost unknown; it is related to that of sympathetic ophthalmia, and in this respect somewhat resembles the organisms of the tubercle group, which have a latent period of some weeks after their inoculation, and the power of healing into the tissues, to cause recurrences later, which power is only very slightly possessed by the true pyogenic organisms.

The healing in of living pyogenic organisms into the eye, to cause renewed inflammation later on, has never been demonstrated. These organisms, it should be observed, can be demonstrated in the eyeball, even after panophthalmitis and perforation, for a longer time than that given by Deutschmann in his review of sympathetic ophthalmia. In Schmidt-Rimpler's case it was four weeks, in Schirmer's[1] three weeks, and in Axenfeld's[2] case five weeks.

Regarding sympathetic inflammation after wounds, both in the 'exciting' and the 'sympathizing' eye, *cf.* section on 'Endogenous Infection.'

In the experimental records concerning traumatic infection of the cornea or of the interior of the eye with *Aureus* (or a traumatic tuberculosis[3]), the question whether such should be treated by iodoform injections (Ostwald, Haab[4]), by sub-

[1] *A. f. O.*, 1892, xxxviii. 4, p. 95.
[2] *Ibid.*, 1894, xl. 1, p. 47.
[3] Traumatic tuberculosis of the eye in man is exceedingly rare (Schirmer).
[4] Concerning the literature of intra-ocular disinfection, especially with iodoform, see the detailed paper on the subject by Krauss (*Zeit. f. A.*, 1904, xii. 97). Römer states the view that iodoform treatment has a special effect on a staphylococcal infection, but not on *Subtilis*.

conjunctival injections (Darier, Mellinger,[1] Bach, etc.), by antiseptic irrigation with silver salts[2] (Krasowski, Hauenschild[3]), by ointments and compresses, or by general treatment (mercury by Schirmer and others), can be dismissed with very little notice.

[1] *Cf.* literature in *Zeit. f. A.*, 1899, i., p. 273.
[2] *Cf.* literature in my 'Ergebnisse,' 1894-1899 (Bergmann, Wiesbaden); also in Michel and Nagel's 'Jahresbericht, by Haab.
[3] Derby, Tr. Amer. O. S., 1906, p. 21.

CHAPTER V

CONJUNCTIVITIS

General.

The collection and preparation of bacteriological material is fully discussed in Chapter I.

Although the researches into the etiology of conjunctival inflammations have been,[1] and still are, numerous and full of interest, and as a result their scientific value is widely known, there are good grounds for the supposition that too little importance is generally attached to the practical results thus obtained.

I am firmly of opinion that the objections and doubts, which are now shared by so many, would more rapidly disappear were surgeons to obtain for themselves the necessary experience in this branch of ophthalmology, and to form their own opinion as to its utility by a free practical trial.

Those who, during their time as assistants, have had the opportunity of frequently examining secretions, without exception firmly believe in the value of such an examination, and would never be without it in their practice.

The examination of long series of cases is necessary before we can give a sound opinion on the bacteriological etiology of the conjunctival inflammations. We are not in a position to define all forms of conjunctivitis on an etiological basis, and a small number of cases is therefore less useful. Those who content themselves by only examining a few cases may perhaps be deceived and form wrong conclusions.

It is difficult, if not impossible, to come to a conclusion on this

[1] That epidemics of conjunctivitis occur among animals is shown by Guissart (conjunctivitis of goats, 'Progrès Vétérinaire,' 1898, p. 369), Penberthi (in cattle, Jour. of Comp. Anat. and Ther., 1897, x. 363), Hoppe (*Ophth. Klinik*, 1899, iii. 14), Liebrecht (*Zool. Garten*, 1902, p. 66), Hoppe, Bartels (in ducks, *K. M. f. A.*, 1904, xlii. 239, with literature); also by diphtheria in birds, concerning which full bacteriological researches have been made, *cf.* Streit (*Zeit. f. Hyg. u. Inf.*, 1904, xlvi. 407), and also the review by Schleich in Michel and Nagel's 'Jahresber.'

subject by studying the literature, for not only do we find work which is erroneous and confusing, but also the individual infective processes do not correspond to any absolute type of disease. Bacteriological investigation has found a different etiology for many conditions clinically identical, and has brought into one class others which differ clinically and were previously entirely separated.

The fact that it is impossible, from the bacterial findings alone, to come to a conclusion concerning every case, appears to many who have not studied the matter, nor themselves examined many secretions, to be conclusive evidence of the superfluity of such a proceeding, the more so as it is not possible for every oculist to be an expert bacteriologist.

We also find that the organisms proved to be pathogenic can sometimes be found on the healthy conjunctiva. How, then, can we convince ourselves of their significance there?

As a matter of fact, the clinical utility of bacteriological examination in conjunctival cases is very marked in many respects. *In many cases a simple smear preparation is more useful than a culture*, because many pathogenic organisms very obvious in the former only develop badly in the latter, and are overgrown by casual Bacteria of no importance.

I would first emphasize that anyone, although only possessing a limited general knowledge of bacteriology, can readily attain to such proficiency as will prove of practical utility; for the majority of authors[1] agree that the causal agent in the case of a catarrh generally is such an important object in the picture that it can be readily seen in smear preparations of the secretion, if suitable material be collected at a suitable stage in the condition. In many cases, too, the morphology and staining reaction with Gram are sufficient for diagnosis. How far this is the case and to what extent this statement must be modified will appear later.

If we ask, What is the *clinical* utility of examining the conjunctival secretion? the answer is: *Epidemics* can then be defined according to their cause, and prognosis, prophylaxis, and treatment decided definitely.

[1] Morax, Morax and Petit, Axenfeld, Uhthoff, L. Müller, Zur Nedden, Saemisch, Groenow, Gonin, Lundesgaard, Weeks, Difford, Junius, Gasparrini, Veasey and De Schweinitz, Bach and Neumann, L. Müller, Hoffmann, Bietti, Coppez, Gourfein, Randolph, D. Smith, Pollock, MacNab, Hanke, Fergus, Stirling, McKee, Tooke, G. S. Derby, Jameson, Evans, Cannas, Corsini, Griffith, Monthus and Opin, Gabriélidès, Schmidt Rimpler, A. Knapp, Kruckenberg, Greeff, Straub, Dalen, Brown-Pusey, Zia, Stoewer and Schmidt, Brewerton, Thomson, Duane and Hastings, Usher and Fraser, Butler, and others.

Similarly with *individual cases* of acute conjunctivitis. The identification of the most severe cases (blennorrhœa and diphtheria) is very important at their commencement, as well as at their height, and often renders a specific (serum) treatment possible.

Among cases of chronic conjunctivitis the demonstration of the *Diplobacillus* is very useful. The varying manifestations of this widespread and common infection, which often enough are quite overlooked, can be definitely counteracted by suitable treatment.

Many conditions which clinically appear unlike infections can be very infectious for others; this would be determined by an examination of the secretion. Both patient and surgeon, too, are often relieved to find that an apparently severe case, on examination of the secretion, is really of a mild character.

Important facts are obtained regarding operations.

It is important to note that almost the only organisms occurring in *acute epidemics* of catarrhal conjunctivitis are the Koch-Weeks bacillus (perhaps also influenza bacilli), and the *Pneumococcus* (in Egypt the *Gonococcus* also, rarely *Subtilis*). Other pathogenic conjunctival organisms only exceptionally occur.

Diagnosis from a simple film preparation is sufficiently accurate for clinical use in the following forms of conjunctival infection:

Gonorrhœal (with the signs of blennorrhœa), Koch-Weeks, diplobacillary, pneumococcal, influenzal, *Bac. coli*, staphylococcal, streptococcal,[1] *Bac. subtilis*, as well as mixed forms from these.

Cultures must be made: (1) when Gram-negative *Diplococci* are met with, either in a simple catarrh or on a normal conjunctiva, to decide between the *Gonococcus*, the *Micr. catarrhalis*, and the rare *Meningococcus*; (2) for the differential diagnosis of the diphtheria bacillus from the *Bacillus xerosis* in pseudo-membranous conjunctivitis.

When in either of these cases a culture cannot be made, we should treat as for the worst organism in the smear—that is, for a probable gonorrhœa or diphtheria.

The diagnosis of *Staphylococci* in the smear (with or without xerose bacilli) is of value, as showing that in a simple conjunctivitis we are dealing with a non-contagious process in which the infection is only of secondary importance (see 'Staphylococcal Conjunctivitis,' p. 236); it may be a casual occurrence in cases of indeterminate bacteriology in which these cocci have developed without any causal significance, such as trachoma or follicular conjunctivitis.

[1] In the great majority of cases (see p. 206).

Allied to these are the 'bacteria negative' cases, where either no organisms or only single cocci and xerose bacilli are found.

If, then, these 'bacteria negative' cases do occur, must we not ask, How can we be quite convinced that in other cases the bacteria are the cause of the secretion, and, if they are, to what extent? Cannot the cause be something quite different, as indeed, it must be, in the 'negative cases'? And may not the increase in organisms be quite accidental?

This point is cleared up for us by a comparative study of clinical experience and bacteriological research. The results of introducing pure cultures into the human conjunctiva, as has been voluntarily done by several people, are here of great importance. The organisms utilized were certainly the cause of the artificial catarrh produced. When we find them just the same in a secretion and associated with an analogous clinical picture, we are justified in considering that they are causal. By further observation, then, the clinical picture can be completed.

If, then, these inoculations with pure cultures of the Koch-Weeks bacillus or the Morax-Axenfeld bacillus almost invariably produce a conjunctivitis, and that too, in very varying people, it is strong evidence that any secretion in which these organisms are to be found has been caused by them. For obvious reasons, no considerable experience is available concerning the inoculation of pure cultures of the *Gonococcus*. The gonorrhœal etiology of purulent urethritis (with rare exceptions) has been absolutely proved by the inoculation of pure cultures on the human urethra. From this, and from the observed fact of transference of the infection from the urethra, as well as from the direct inoculations carried out by Biringer, it is clear that when this organism occurs on the conjunctiva in a case of blennorrhœa, it can be considered as pathognomonic, just as in the case of the other organisms already considered.

The organisms mentioned must be considered to be **highly infectious** for the conjunctiva, where they always produce a conjunctivitis when a secretion containing them is brought into close contact with it. The demonstration of a very small number of such organisms is sufficient to make the diagnosis very probable. When they occur in large numbers—which is usually the case—such a diagnosis can be made positively.

We can also form a definite opinion as to which organisms develop secondarily on the inflamed conjunctiva. In examining the bacterial flora of the conjunctiva in cases of iritis, or during the aseptic healing of

operation wounds, with the exception of a few organisms occasionally met with, *Staphylococci* and xerose bacilli are generally found, often in large numbers. Those other organisms which definitely do cause conjunctivitis—as for example, the *Pneumococcus*—do not occur, or are found in isolated cases, and in very small numbers.

According to my own experience, which agrees with that of Morax, when single examples of the **less infectious** and rather more **facultative** conjunctivitis organisms are found, especially *Pneumococci*, *Streptococci*, influenza bacilli, *Pneumobacilli*, *B. coli*, and *B. subtilis*, a definite etiological diagnosis cannot be made. In such cases we should certainly take note of the condition, repeat the examination, and consider whether we have to do with an inflammation in the early developing or later regressive stage, when the actual causal agent might not yet have reached, or have already passed, its greatest profusion. From the mere presence of an organism we should not venture on a positive diagnosis. When really pathogenic, at a suitable stage they will be found in large numbers. When we find them numerous, their etiological significance is so very probable that we can give a clinical diagnosis (*e.g.*, pneumococcal conjunctivitis); for then the possibility of an error—that is to say, that the organisms are purely saprophytic—though not absolutely excluded, is certainly very small. It is only very rarely that I have found numbers of *Pneumococci* without well-marked inflammatory reaction, and then only in the stagnant secretion of an everted punctum, after extirpation of the sac or a commencing ectropion, etc., when *Staphylococci*, xerose bacilli, and sometimes *Mic. catarrhalis*, could also be found in enormous numbers.

Staphylococci certainly can be present in large numbers without producing any result, and the same may be said of the *Bacillus xerosis* When either of these two organisms occurs along with other infections —*e.g.*, Koch-Weeks, *Pneumococcus*, etc.—they are not generally to be considered as ' mixed infections,' but simply as accompanying bacteria which have no definite influence upon the disease.[1] Taking this view, it cannot be said that ' mixed infections,' in the full sense of the term, are common in simple catarrh, though they are in pseudo-membranous forms; they often accompany trachoma and secondary follicular catarrh. In the most profuse mixtures of organisms which I have ever found in the stagnant secretion of ectropion, etc., the impression was given of a saprophytic overgrowth, and the bacteria were often only casually present.

[1] *Cf.* 'Symbiosis,' p. 43.

Regarding the question of the clinical value of such examinations, it is necessary not merely to know which organism is at work, what clinical signs it produces, and to what extent it can cause epidemics; but each surgeon must determine, by the study of serial records, the importance of the various infections in his particular district, as there are great epidemiological and local variations in these infectious diseases.

A large number of records from various countries[1] show to what extent and with what limitations a true etiological definition can now be applied to conjunctivitis. A few data[2] will be taken from the many papers ranging through the whole subject of conjunctivitis. The frequency and character of the various infections will first be dealt with, and then the details regarding these various forms will be treated of in a separate chapter.

The secretions of 900 cases[3] of acute and chronic conjunctivitis (out of 12,000 patients) were examined in the Freiburg Polyclinic in the years 1902-1905 inclusive, in which were found:

519	containing	*Diplobacilli.*
41	,,	Koch-Weeks bacilli.
34	,,	*Pneumococci.*
12	,,	*Gonococci.*
6	,,	Löffler's *Bacillus diphtheriæ.*
5	,,	*Streptococci* causing diphtheria.
2	,,	*Pneumobacilli.*
3	,,	Pfeiffer's (influenza) bacillus.

In the 278 cases remaining the ordinary *Staphylococci* and xerose bacilli were very often found; in 9 of them *Micr. catarrhalis* occurred, but without any certain causal significance. In some of the cases *Staphylococci* were more numerous, and these might have been classified as staphylococcal conjunctivitis. Even when we take the last group as doubtful, we have a useful slide diagnosis, on a causal basis, in something over two-thirds of the cases. In this list those organisms are given which in the individual case appeared either pure, or, on account of their overwhelming numbers, to be the most important. Mixed infections are not quoted separately; regarding their frequency see the individual chapters.

Genin published statistics of 365 cases, which occurred in a definite period of time, and from which only traumatic and phlyctenular conjunctivitis were excluded. His results were as follows:

(*a*) 13 cases of **pseudo-membranous conjunctivitis**:

7	containing	Löffler's bacillus.
4	,,	*Staphylococcus.*
1	,,	*Pneumococcus.*
1	,,	Koch-Weeks bacillus.

[1] Records from Southern climates are scanty. Egypt, Argentina (Demaria), Paraguay (Elmassian), and Palestine (Butler), alone are available.

[2] For this purpose I have taken only the later papers.

[3] *Cf.* the dissertation of Geis (Freiburg, 1907).

(*b*) 42 cases of **purulent conjunctivitis**:

24	containing	*Gonococcus.*
8	„	Koch-Weeks bacillus.
1	„	*Staphylococcus.*
1	„	*Streptococcus.*
2	„	various indeterminate organisms.
2	„	none.

(*c*) 310 cases of **catarrhal conjunctivitis**:

185	containing	*Diplobacilli.*
10	„	Koch-Weeks.
10	„	*Pneumococcus.*
5	„	*Streptococcus.*
83	„	*Staphylococcus.*
6	„	various bacilli.
11	„	none.

(*d*) 33 cases of **conjunctivitis neonatorum**:

22	containing	*Gonococci.*
4	„	*Pneumococci.*
3	„	Koch-Weeks.
2	„	various bacteria.
2	„	nothing.

Examination of a secretion smear—which, indeed, determines the utility of bacteriological examination in practice—gave a positive and useful result 245 times in the 365 cases; 15 times the result was quite negative, and 100 times individual organisms were seen (especially *Staphylococci*), but the result was indeterminate. From these results Gonin rightly affirms that such an examination is valuable in practice.

The table given above further shows that diplobacillary conjunctivitis is very frequent in Lausanne, the other forms being less important.

With regard to the classification of conjunctivitis, Gonin agrees with Morax in the view that, respecting conjunctivitis due to Koch-Weeks bacilli, to *Gonococci*, and to *Diplobacilli*, the bacteriological designation is correct and unassailable, for these organisms, as a rule, are alone the causes of the disease. For the others, in which disposition, etc., is of more importance, a clinical designation must be combined with the bacteriological.

Pollock examined 236 cases of **acute muco-purulent catarrh**, and found:

177	containing	Koch-Weeks.
9	„	Morax *Diplobacillus.*
6	„	*Pneumococci.*
2	„	*Gonococci.*
1	„	*Gonococci* + Koch-Weeks.
6	„	*Staphylococci.*
4	„	indeterminate organisms.
28	negative.	

69 cases of **subacute catarrh**:

7	containing	Koch-Weeks.
51	„	*Diplobacilli.*
3	indeterminate.	
8	negative.	

10 cases of **purulent catarrh**:

3 containing Koch-Weeks.
1 „ Koch-Weeks + *Subtilis.*
1 „ *Pneumococci.*
5 „ *Gonococci.*

18 cases of **ophthalmia neonatorum**:

2 containing Koch-Weeks.
7 „ *Pneumococci.*
10 „ *Gonococci* (pure).
1 „ *Gonococci* + *Streptococci.*
1 „ *Gonococci* + Koch-Weeks.
1 „ *Gonococci* + *Pneumococci.*
1 negative.

2 cases of **membranous conjunctivitis** contained *Staphylococci.*

16 cases of **phlyctenular conjunctivitis** were negative.

10 cases of **catarrh** were **complicated with blepharitis**, of which

2 contained *Diplobacilli.*
5 „ *Staphylococci.*
2 „ *Staphylococci* + *Streptococci.*
1 was negative.

The aggregate of 361 cases of **conjunctivitis** was:

189 Koch-Weeks.
62 *Diplobacilli* (Morax-Axenfeld).
9 *Pneumococci.*
3 *Pneumococci* + *Diplobacilli.*
17 *Gonococci* (pure).
4 *Gonococci* + others.
13 *Staphylococci.*
2 *Staphylococci* + *Streptococci.*
1 Koch-Weeks + *Subtilis.*

299 positive results, in contrast with 62 indeterminate or negative.

Pollock's statistics also show clearly that many infections (Koch-Weeks, *Diplobacilli*) present a definite clinical appearance in the great majority of cases; and if the relative numbers in his lists are compared with my own from Freiburg, we see how the frequency of the different infections varies in different localities.

C. Usher and H. Fraser[1] investigated a series of 820 cases (in Aberdeen).

In 310 cases (exclusively townsfolk) infected with the Koch-Weeks bacillus, 36 of whom had the *Diplobacillus* also present, a probable diagnosis was given in 242 (86·4 per cent.); 235 of the cases were children under fourteen years old.

In 274 cases with *Diplobacilli* (clinically probable in 176), and mostly country folk, only about one-fifth were children; 88 per cent. of the 'angular' conjunctivitis cases were due to *Diplobacilli.*

In 24 pure pneumococcal cases the symptoms varied.

In 18 cases *Gonococci* were found.

In 1 case diphtheria bacilli were found.

In 114 doubtful cases (72 unilateral) 37 showed *Staphylococcus pyogenes albus* and *Streptococci.*

In Usher and Fraser's series there was an increase in the frequency of conjunctivitis among the town-people in spring and autumn, the first chiefly due to an increase in diplobacillary cases and the latter to the prevalence of Koch-Weeks conjunctivitis.

[1] *Loc. cit.*, reviewed Ophth. Rev., 1907.

In Egypt, generally in double-sided trachoma, Meyerhof found in 304 cases of **acute purulent conjunctivitis**:

157	containing	Koch-Weeks.
80	,,	*Gonococci.*
37	,,	*Diplobacilli.*
10	,,	*Pneumococci.*
4	,,	*Streptococci.*
2	,,	influenza (L. Müller's bacillus).
1	,,	*Pneumobacilli.*
7	negative cases.	

Duane and Hastings in 132 cases of **catarrhal conjunctivitis** found:

1	containing	*Gonococci.*
45	,,	Koch-Weeks bacilli (10 pure, 8 + xerose bacilli, 17 + xerose bacilli + *Staph. albus*, 4 + *Staph. aureus*, 2 + *Micr. catarrhalis*, 1 + *Pneumobacilli*).
23	,	*Staph. albus* (18 pure, 5 + *Micr. catarrhalis*).
3	,,	*Staph. citreus.*
6	,,	*Staph. aureus.*
2	,,	*Streptococci.*
22	,,	*Pneumococci* (All more or less mixed with other organisms).
5	,,	*Diplobacilli.*
2	,,	Diphtheria bacilli (pseudo-membranous cases).
30	,,	'infection with xerose bacilli.'
22	negative.	

The 30 cases with xerose bacilli should be considered as indeterminate, and recorded with the negative ones; we then have (considering the *Staphylococci* as positive), 80 positive results, and 52 negative or of no value.

Duane and Hastings insist that a mixture of several organisms is found in slight cases of conjunctivitis, giving the impression that the bacteria hindered each other's activity.

Duane and Hastings go too far when they conclude that from the clinical aspect of the case no evidence can be gained as to the causal organism. I do not agree with them in considering the simultaneous presence of xerose bacilli, and in many cases the white *Staphylococci*, as indicating a mixed infection in the true sense of the word, seeing that we cannot attribute to these organisms any definite agency in the production of an inflammation, and at the very most they have only a symbiotic function (*cf.* 'Normal Conjunctiva'), or else are purely secondary. True mixed infection—*i.e.*, the simultaneous pathogenic activity of different organisms on the conjunctiva—is by no means so frequent. When the margins and angles of the lids are avoided in collecting the secretion, pure cultures are very often obtained. Those cases should not be considered as mixed infections in which a few stray facultative pathogenic organisms occur amongst large numbers of the causal one.

In the acute secretion of a trachomatous conjunctiva Duane and Hastings generally found a secondary infection (Koch-Weeks bacillus alone, or with *Staph. Pneumococcus* or *Micr. catarrhalis*, or else the last alone or mixed). Besides these, they found in three cases only *Staph. albus*, and in one case a negative result.

They attribute a special power of causing a complicating keratitis to the *Staphylococci*, especially *Staph. aureus*, when thus present. There is no proof that such is the case. They very definitely assert that when it becomes virulent the white

Staphylococcus often produces an inflammatory reaction in the conjunctiva and cornea. They refer to the observations of Gifford and Bossalino on this point.

Oliver considers the infections of the conjunctiva as mixed ones, in which one or other organism becomes more and more prominent, and determines the subsequent course of the condition. He considers the corneal complications as essentially due to the action of the pyogenic organisms, for whose activity the others only prepare the way.

Morax, who had several times previously summarized the position, has lately given his statistics in the paper by R. Augé on 692 cases of conjunctivitis :

175 Koch-Weeks bacilli (14 negative).
258 *Diplobacilli.*
121 *Gonococci.*
18 *Pneumococci.*
6 influenza bacilli.
2 Löffler's diphtheria bacilli.
6 *Staphylococci.*
10 indeterminate bacilli or cocci.
96 '*amicrobiennes,*' of which 8 had many xerose bacilli.

He gives the remarkable statistical record that, amongst 165 cases of ophthalmia neonatorum, 70 were gonorrhœal and 95 non-gonorrhœal, of which latter no fewer than 77 were '*amicrobienne.*'

Bach and Neumann in 110 cases found :

35 containing *Diplobacilli* (5 pure, 4 + xerose bacilli, 22 + *Staph.*, 1 + *Pneumococci*, 1 + *Pneumobacilli*, 2 + *Streptococci*).
15 „ *Pneumococci.* (6 pure, 7 + *Staphylococci*, 2 + *Streptococci*, *Staphylococci* and xerose bacilli).
53 „ *Staphylococci* in large numbers, but with them xerose bacilli, and often *Sarcinæ* (quite a large proportion of this group must be considered as of doubtful etiology).

Veasey in 64 cases of **acute catarrhal conjunctivitis** found :

3 containing Koch-Weeks bacilli.
53 „ *Pneumococci* (10 times mixed with others).
6 „ *Staphylococci.*

This is an enormous preponderance of *Pneumococci.*

Lundsgaard obtained a positive result 68 times in 107 cases, of which :

38 contained *Diplobacilli.*
15 „ *Pneumococci.*
5 „ *Gonococci.*
5 „ *Staphylococci.*
1 „ diphtheria bacilli.
1 „ *B. coli communis.*
3 „ Koch-Weeks bacilli.

In 381 cases Scholtz and Verner (Budapest) found :

178 containing *Diplobacilli.*
65 „ Koch-Weeks bacilli.
11 „ *Pneumococci.*

In the 178 cases of diplobacillary conjunctivitis, 140 were chronic, 31 subacute, 7 acute. Of the 65 cases of Koch-Weeks conjunctivitis, 50 were acute, 15 subacute. Of the pneumococcal cases, 4 were acute, 3 subacute, 4 chronic.

LITERATURE.

AUGÉ, R., Recherches statistiques sur la proportion des affections contagieuses observées dans une consultation ophthalmologique. Thèse de Paris, 1906.

AXENFELD Bakteriologie des Auges, 1894-1900, in 'Ergebnissen der pathol. Anatomie' LUBARSCH and OSTERTAG (*cf.* here literature).

BACH, Z. f. A., 1904, XI, S. 1.

BACH and NEUMANN, A. f. A., 1898, XXXVII, S. 93.

BIETTI, K. M. f. A., 1903, Festschr. f. Manz.

BREWERTON, The bacteriology of conjunctivitis. Lancet, April, 1903.

BUTLER, The clinical features, bacteriology, and, treatment of acute ophthalmia in the East. R.L.O.H. Reps., XVII, p. 115, 1907.

CORSINI, Batteriologia della congiuntiva. Policlinico, Suppl., 1900.

DALÉN, Om konjunktiviternas bakteriologi, 1899, Hygiea, p. 329-330.

DOYNE, R. W., Septic conjunctivitis. Lancet, 1903, Vol. II, p. 1299.

DUANE and HASTINGS, Bacteriological types of acute conjunctivitis. N. Y. Med. Journ., May 26, 1906.

EVANS, Ophthalmoscope, April to June, 1905.

FEILCHENFELD, Epidemische Augenentzündungen in Schulen. Zeitschr. f. Schulgesundheitspflege, 1903, XVI, S. 677.

FERNANDEZ, SANTOS, Las oftalmias en Cuba. Arch. de oft., 1904, p. 141.

FERGUS, F., Some practical aspects of conj. bact. Brit. Med. Journ., 1905, p. 522.

VAN FLEET, Ophthalmology, 1905, p. 472.

GABRIÉLIDÈS, Ophthalmologie mikrobiologique, I. Conjonctive. Konstantinopel, 1906.

GIFFORD, Arch. of ophth., 1898, XXVII, 6.

GONIN, De la nature microbienne des conjonctivites. Revue méd. de la Suisse Romande, February and March, 1899.

GRIFFITH, Thompson Yates Lab. Rep., Liverpool, 1901.

HIROTA, Inaug. Dissert., Halle, 1903.

KIBBE, A. f. A., 1899, XXXVIII, S. 273.

KRUKENBERG, Zeitschr. f. Krankenpflege, 1901, XXIII, Nr. 6.

LEWIN and GUILLERY, Bd. II. Berlin, 1904 (Hirschwald).

LOBANOW, Luftinfektion und Auge. A. f. O., 1900, LI, S. 431.

LUNDSGAARD, Bakteriologiske Studier over Konjunktivitis. Copenhagen, 1900.

MCKEE, The bacteriology of conjunctivitis, Amer. Jour. of Med. Soc., June, 1906.

MINNE, La bactériologie dans la pratique ophthalmologique. Gand, 1900.

MEYERHOF, K. M. f. A., 1905, XLIII, 9.

MONTHUS et OPIN, Paris, 1902 (Steinheil).

MORAX, Recherches sur l'étiologie des conjonctivites aiguës. Thèse de Paris, 1894.

MORAX et PETIT, Annales d'ocul., 1898, CXX, p. 161.

OLIVER, Jour. of the Amer. Med. Assoc., 1905, XLIII, p. 420.

POLLOCK, W. B. J., The bacteriology of conjunctivitis. T.O.S., 1905, XXV.

POULARD, Adénopathie dans les infect. conjonct. Ann. d'ocul. CXXX, p. 318.

PUSEY, BROWN, Ophth. Record, 1903, p. 290.

RANDOLPH, Jour. of the Amer. Med. Assoc., 1903, XL, p. 821.

ROCHAT, Oogheelkund. Bijdragen, 1905, Nr. 46.

SCHMIDT, Über das Vork. infektiöser äusserer Augenentzündungen im westfälischen Industriebezirk. A. f. A., 1902, XLV, S. 79.

SCHOLTZ and VERMES, Szemeszet, 1907, and K. M. f. A., 1908.
SHUMWAY, E. A., The pathogenic bacteria of the conjunctiva. Amer. ophth. Congress, 1906. Jour. of the Amer. Med. Assoc., 1906.
SMITH, D., Arch. of ophth., 1905, XXXIV, p. 481; 1906, XXXV, p. 356.
SMITH, 100 cases with bacter. exam. Journ. of eye, ear, etc., 1904, p. 98.
STIRLING, Montreal Med. Journ. October, 1905 (Ophthalmology, January, 1906).
UHTHOFF, Über den gegenwärtigen Stand der Bindehaut- und Hornhautentzündungen. Samml. zwangl. Abhandl. von Vossius (Halle, Marhold, 1899).
USHER, C. H., and FRASER, H., R.L.O.H. Rep., 1906, p. 430.
VEASEY, Bacteriology of acute conjunctivitis. Ophth. Review, 1899, p. 354.
DE SCHWEINITZ and VEASEY, Ophth. Record, 1899, p. 80 and 87.
VALENTI, Sulla azione di alcune sostanze tossiche sulla congiuntiva oculare. Archivio di Ottalmol., 1900, VIII, p. 20.
ZIA, Inaug. Dissert., Marburg, 1903.
ZUR NEDDEN, 'Ergebnisse' (LUBARSCH-OSTERTAG), 1900-1905.

The articles mentioned and the other analogous records, taken in conjunction with those which will be mentioned in the special chapters later, show that **there is no absolutely typical clinical picture corresponding to the individual forms of infection.** We would, however, emphatically state that relatively characteristic appearances are presented—in the sense, for example, that diplobacillary conjunctivitis undoubtedly produces the appearance known as 'ophthalmia angularis,' and that pneumococcal conjunctivitis tends, in very many cases, to assume the characteristic appearance first described clinically by the author. Similarly a relative preponderance of certain features obtains in gonorrhœa, in diphtheria, and for the Koch-Weeks infection. After considering reports chiefly dealing with variations, we should not conclude that no causal provisional diagnosis can be made. That is not the case. Regarding contagiousness, complications, and predisposing factors, well marked points of difference can be established. The final conclusion is—and this is stated on all sides—that **clinical diagnosis and microscopical examination must supplement each other,** and a variable but greater degree of certainty will then ensue with regard to etiology, prognosis, prevention, and treatment. A glance at the work on epidemic pneumococcal conjunctivitis shows this very clearly. The chapters which follow will give further details on this point.

The possibility of giving a provisional diagnosis from the clinical appearances varies in different localities. In places where both pneumococcal conjunctivitis and Koch-Weeks infection frequently occur considerable restraint must be exercised in thus diagnosing cases of acute catarrh; for there are cases which cannot so be clinically differentiated, although even in them, if the whole course and all the details of the infection be considered, the experienced observer may

note many differentiating points. In many localities, on the other hand, only one or the other of these infections occurs, and then the probable diagnosis is similarly restricted. For example, in Rostock, Breslau, and Marburg I have almost invariably been able to confirm the provisional diagnosis of pneumococcal conjunctivitis; but in Freiburg, where Koch-Weeks conjunctivitis is common, such uniformity does not occur.[1]

The signs and symptoms of a conjunctivitis depend not only on the pathogenic power of the Bacteria, but also on the condition of the nidus, for the latter has a very varying disposition towards different Bacteria. I do not mean by this the variable opportunity for infection, which depends on chance external conditions[2]—hygiene, indolent habits, etc.—but the actual variation in susceptibility.

Disposition is a factor of very varying influence in infectious diseases; but, after extreme views have had time to subside, pure bacteriological interpretations always succeed in obtaining recognition of their value. That disposition plays an important part in many eye infections is self-evident.

This point, however, deserves special consideration, because many surgeons have quite recently raised the objection that the same organisms—*e.g.*, diphtheria bacilli and *Pneumococci*—are met with in diseases which are clinically different; they also occasionally occur on the healthy conjunctiva.

The sharp differentiation previously made between pathogenic and non-pathogenic saprophytic organisms has gradually been toned down by bacteriologists, as in each natural family many transitional forms, obviously developed from the same origin, became known. Many Bacteria considered as non-pathogenic and purely saprophytic have been shown to cause disease occasionally; and the pathogenic forms can lose their virulence to such a degree that they become neutral, just as the other morphological and biological properties of the Bacteria can vary.

Many groups or families have thus been evolved, into which the allied varieties are collected, and the problem to decide is, What relation do their various members bear to each other? In ophthalmic bacteriology we have problems of this kind to solve. The group of the septate Bacteria—*i.e.*, the diphtheria group, the *Staphylococcus* group,

[1] *Cf.* Usher and Fraser's provisional diagnosis in 86·4 per cent. of Koch-Weeks cases in Aberdeen, where pneumococcal conjunctivitis is very rare.—TRANSLATOR.

[2] O. Rosenthal, under direction of von Michel, has experimentally shown how far spectacles protect against contamination by dust or moisture (they have practically no action), and how far infected spectacles carry infection (they do so freely).

the Gram-negative *Diplococci*, the chain-forming cocci (*Ketten-bildner*), the Hæmophiles (Koch-Weeks and influenza)—all present this difficulty, and I feel that I must explain what facts are available and what questions are still open regarding these particular points.

When in healthy persons we find organisms otherwise considered as pathogenic, we must have either a defective pathogenic power in the bacteria or a refractory condition of the nidus, or a combination of both in varying proportions.

To what degree these factors are of importance in the various forms of conjunctivitis will be shown in the chapters dealing with them in particular. I will, however, give here a general review of the question.

The presence of any bacterium in a healthy tissue does not render doubtful its pathogenic significance under favourable circumstances, provided that there is otherwise certain evidence of such pathogenicity. Just as in a cholera epidemic every one who is attacked by the virus does not necessarily become ill, so in the case of conjunctival infections. There are refractory individuals and those who only react slightly. And as there are infectious diseases which are at one time very infectious and at another less so, as there are abortive and severe cases, and persons who are immune after a single attack, we must not lay down any hard-and-fast rules when dealing with the conjunctiva.

Gonococci and **Koch-Weeks bacilli** evidently lose their power of causing a conjunctivitis, very slowly indeed, and are very independent of any disposition. The same is true for the **Morax-Axenfeld Diplobacillus**, but not to the same high degree.

These organisms, which previously were with exaggeration called 'unconditionally infectious,' are, as a rule, so pathogenic for the conjunctiva, that even when only a few individuals are found in the secretion, the probability is very great that they are causal; for, on account of their great virulence and the marked susceptibility to them, a very small number suffices.

Occasionally, however, scattered individuals—certainly not large numbers—of these organisms may be found on the conjunctiva without producing any effect. That every infection with these organisms does not produce the disease is obvious in the case of gonorrhœa, from its not infrequent one-sided character.[1] It is well to note that the secretion very often does not come into actual contact with the other conjunctiva because of the flushing action of the tears; and, further, that

[1] *Cf.* section on 'Blennorrhœa.'

it is to some extent due to variation in susceptibility and immunity[1] that the contagion does not always result.

In the case of the Koch-Weeks bacillus and the *Diplobacillus*, though there is less secretion, still the catarrh almost always affects the other side. There may, perhaps, be a difference in the disposition of the two eyes in the same individual.

Groenouw and Meyerhof state that after a gonorrhœa has subsided the conjunctiva is immune to the *Gonococcus* for some time. (This requires further confirmation, the other Gram-negative *Diplococci* being also considered.)

Plaut and Zelewski have found the *Diplobacillus* a few times on the healthy conjunctiva after the sac has been excised. Erdmann and Rymowicz found it, too, in normal people.

Only in very rare cases has the Koch-Weeks bacillus been found in normal cases (Plaut and v. Zelewski). Meyerhof reports that it can remain dormant in trachomatous cases without causing a catarrh. This and the fact that cases of very mild, hardly recognizable Koch-Weeks conjunctivitis do occur, and may produce a virulent infection in others, make it not unlikely that this organism may occasionally be benign. The actual pathogenic nature of this bacillus is, however, definitely established by many positive inoculations, and is naturally not controverted by these facts.

In the case of the *Gonococcus*, Koch-Weeks bacillus, and *Diplobacillus*, we must assume that they have been introduced by infection from without shortly before the affection shows itself, and that only exceptionally an organism, though present, may be latent, and then, becoming virulent, cause the disease. In dealing with the other facultative producers of conjunctivitis, however, this last possibility occurs to a far greater extent. In the case of *Pneumococci* there is certainly the possibility of contagion; we have the evidence of definite inoculations, and the occurrence of epidemics to prove this. But, as the author first showed, along with this we must also bear in mind that, as the result of increased susceptibility or raised virulence, a form of self-infection may occur, due to saprophytic *Pneumococci* previously present, and these are common on the normal conjunctiva. This is probably the explanation of sporadic cases.

The same may occur with influenza bacilli and *Streptococci*. It is still disputed whether a self-infection can occur in the case of the diphtheria bacillus, in the sense that the *Bacillus xerosis*, that constant saprophyte, can change into virulent Löffler's bacilli. When *Staphylococci* are the cause of a conjunctivitis, it is not the method of infection from without, but that of self-infection, which is of importance.

[1] Panas and Randolph insist that one-sided gonorrhœa in adults is more often right-sided, and is due to the eye being rubbed with the right hand. The disposition here consists in the mechanical injury. Von Michel and Bach emphasize the importance of this rubbing of the eyes.

Infection of the conjunctiva from without is caused by direct or indirect contact [transference by flies can occur (Welander)], or by air transmission. The last method is comparatively rare. The most important method of air transmission is by spraying. The causal agent, after passing down the nasal duct with the secretion into the nose and mouth, or being already there, is scattered into the air by speaking, coughing, or sneezing. This possibility was first advanced by Lobanow (*A. f. O.*, 1900, li., p. 431). Rapid and widespread epidemics may be due to this method.

The possibility of an air transmission of organisms, either dried or adhering to fine particles of dust, depends on the resisting power to dryness (desiccation) of the organism in question. The literature on this question is collected in the paper by Lobanow already mentioned. The results obtained by Germano and M. Neisser show that, amongst the pathogenic organisms in ophthalmology, the *Gonococcus* has a very low resistance to drought; *Streptococcus* and *Pneumococcus* resist better, though different stems vary in this respect, the diphtheria organism longer, and *Staphylococcus* still longer. The spore-forming organisms, amongst which is *Subtilis*, are the most resistant. Gourfein states that this last organism is transmitted in dust or earth. Some variation occurs in the individual bacteria, according to the method of drying: organisms dried up in secretions retain their vitality longer than when dried in pure culture, as is well known in the case of *Pneumococci*. We must also differentiate between drying in a very fine desiccation, such as could be wafted about in the air of a room, and drying up of larger particles which could only be moved about by a strong draught. The xerose bacilli, when tested by Lobanow by desiccation in the air of a room, were shown not to be able to resist such drying, and therefore the term *Luft-stäbchen* so often used is not quite applicable. Further investigation of this subject is required, especially with regard to organisms which produce conjunctivitis. [This has been done in the case of the *Diplobacillus* by Macnab and Paul.]

In general, however, air transmission, as a cause of epidemic conjunctivitis, does not play so important a part as does direct or indirect contact.

Under these circumstances the varying influence of pathogenicity and disposition is a factor of great importance, especially in the case of the facultative producers of conjunctivitis.

A very interesting example is pneumococcal infection of the conjunctiva, with its peculiar ending, often by a crisis. Many persons have a conjunctiva immune to

this organism, though in other people by contact transference it certainly acts as the cause of conjunctivitis. On the one hand, a whole series of positive contact infections of the human subject can be quoted, and, on the other hand, are my own numerous negative inoculations; yet these two sets of results are not contradictory. (In this peculiar infectious disease—and also in pneumonia—climatic disturbances very probably have an influence; the 'chill,' which at one time seemed to be disappearing from the medical vocabulary as unmodern, appears to again obtain its rights.)

The predisposing factors in the case of the diphtheria bacillus are fully considered by Sourdille and Uhthoff, and all the later investigators agree with them. Proved inoculations of this organism on man are not available, but Morax and Elmassian have obtained a typical membranous conjunctivitis in rabbits by continued instillations of diphtheria toxin. It cannot be denied that toxic action is of great importance in the production of the clinical appearances in many cases of diphtheria, nor, in view of these experiments, that of itself it can produce a diphtheria. These experiments are important because, using the bacilli themselves, analogous processes can only rarely be obtained in animals (Henke, Papers from the 'Path. Institut,' Tübingen, ii., p. 321). A single dose of the bacteria does not cause sufficient development of toxin. The finding of virulent diphtheria bacilli on the healthy or simple catarrhal conjunctiva (Pichler, A. von Hippel, Pes, McKee, Vossius and Wagner, Mathiew) does not contradict this, and the last-named authors themselves did not consider such findings as negativing pathogenicity.

In spite of the fact that inoculations on the human subject have not been made, we must consider the *Streptococci* as certainly having the power of producing a conjunctivitis in many persons, seeing that, just as in the throat, a necrotic process immediately follows their presence on the mucous membrane, and also because of the very serious results in such cases. The experimental inflammation produced by Bardelli with pure streptococcal infiltrated tissue is denied by Coppez; the organisms themselves and their endotoxins appear essential.

The enormous frequency of *Staphylococci* on the normal conjunctiva, as well as in inflammatory conditions with which they have nothing to do, leaves the pathogenic nature of the less virulent members of this group, at any rate, improved. We cannot, however, exclude the possibility that, where they occur in large numbers, are virulent, and circumstances are favourable to them, they may occasionally cause a conjunctivitis, especially of the pseudo-membranous form. In this case, too, caution is necessary, for when large numbers of virulent cocci have been inoculated (Leber, Sattler, and others), no catarrh of any consequence was ever obtained.

We still have only very little experience about *B. coli*. There have been no definite inoculations, but its occasional action as a cause of catarrh is made probable by the cases recorded by Taylor, Axenfeld, Bietti, Groenouw, and Cramer, and also by analogies from other mucous membranes.

There is no definite proof of the power of the influenza bacillus to produce conjunctivitis; according to Giarrè and Picchi, and Rymowicz, it occurs on the normal conjunctiva. Inoculations on the human conjunctiva had no result (Luerssen, Axenfeld). Seeing, however, that it occurs in large numbers, and without any other organism, in the secretions from many conjunctival inflammations, the term 'influenza bacillus conjunctivitis' is justifiable, especially as it very probably can cause an inflammatory reaction upon other mucous membranes, particularly in the air passages.

The same is the case with the *Pneumobacilli*. We infer that they can produce a catarrh from their severe pathogenic action in other tissues, in the lungs, and in the accessory nasal cavities.

Similarly it is very likely, from the most recent work of Michalski and Gourfein,

that *B. subtilis* can occasionally cause a conjunctivitis, although in this case we have no analogies from the other mucous membranes. Some original traumatism seems here necessary, such as the introduction of dust or earth.

The working of disposition is well shown by the fact that the conjunctival affections already mentioned, when occurring in scrofulous patients, can produce the clinical appearances known as 'conjunctivitis phlyctenulosa.' This fact, which will be more fully considered later, is here brought forward because the *Diplobacilli* often produce and maintain a typical phlyctenular conjunctivitis. The examination of the secretions in such cases is of especial value, as the zinc treatment of the *Diplobacilli* often terminates the inflammatory condition. In this fact, too, we have an important example of how an affected part may react in characteristically different ways to the same irritant.

Disposition, too, is concerned with the fact that different forms of conjunctivitis from an epidemiological standpoint are variously distributed over the earth's surface. Although the surrounding conditions have much to do with this, still there are many differences which cannot be referred to this factor. In the individual chapters this question of epidemiology will be further discussed.

It is doubtful whether race has any influence, and certainly there is no proof that such is the case; only with regard to trachoma is the question urged to any extent.

The condition of general health has an influence, as we see in the results of ophthalmia neonatorum.

How far we can allege an inherited specific immunity of the conjunctiva will also be discussed in the special chapters.

That the conjunctiva partakes in a general immunity is proved in the case of the antitoxic immunity for diphtheria. [We know that an analogous condition occurs in abrin immunity; there is also a pure local abrin immunity of the conjunctiva (Römer)]. The same may be presumed in the case of pneumococcal immunity, although it is difficult to prove on account of the uncertain action of *Pneumococci* on the conjunctivæ of non-immunized animals.

Protective bodies for *Gonococci* can be produced experimentally in animals, but we cannot judge how far a similar state of affairs can occur in the human conjunctiva.

We cannot even discuss the question with regard to such organisms as Koch-Weeks bacilli or the *Diplobacilli*, which are exclusively pathogenic for the conjunctiva.

Persons who are unaffected by the other pathogenic organisms are but slightly indebted to general immunity for their escape; in those

who are affected, however, a more important determining factor is the influence of some other local irritation, or a lowered tissue resistance due to injury.

Cramer, having extensive material, showed how a pure mechanical lesion of the lids at birth had an influence in determining an ophthalmia neonatorum.

Lobanow infected the conjunctivæ of rabbits, under various conditions, with *Staphylococcus pyogenes aureus*, *Streptococci*, and *Pneumococci*, and demonstrated that a more severe inflammation resulted if the lid movements were prevented; the same occurred if the canaliculi were closed or the palpebral fissure narrowed. An increase in the secretion of tears had no influence, so that an actual bactericidal action of the tears could be excluded. If the epithelium was removed from the conjunctiva, then a purulent keratitis resulted.

Römer proved that the action of various sterile forms of dust (coal dust, grinders' dust, dust from wool, from wood, from tobacco, street dust) increased the flora of the conjunctiva to a very great degree. From its mechanical, and in the case of tobacco its chemical action, the dust produced a hyperæmia and secretion; twice in 100 cases a purulent conjunctivitis resulted, probably owing to the particles wounding the epithelium, so that an infection with *Staphylococci* could occur.

To decide what conditions were necessary for this dust infection, Römer introduced anthrax bacilli, with spores and dust mixed, into the conjunctival sac. Only a few animals contracted an inflammation and general infection. If, however, after introducing the material, he rubbed the eye a few times through the closed lids, then infection occurred more often. This shows that the conjunctiva can be the point of entrance for anthrax. Anthrax spores, when introduced with dust into the conjunctival sac, can after seven days be still found there in a virulent condition; it must therefore be presumed that when bacteria are mixed with dust particles they are not always washed down the nose, but remain for a considerable time in the conjunctival sac.

These experiments of Römer's with dust bring out some points of importance in the incidence of conjunctivitis in man; they show how very slight injuries and chemical irritation make the conjunctiva susceptible.

In many cases an irritated condition of the surrounding parts predisposes to the occurrence of an infection. Acute and chronic inflammations of the nose and surrounding parts must here be considered, partly because they cause a hyperæmia, with obstruction to the tears, and also because the conjunctiva can be infected from the nose (*cf.* the chapter on 'Diplobacillary Conjunctivitis,' 'Scrofulous Inflammations,' 'Trachoma,' 'Sac Affections,' etc.; also the article by Gutmann, *Deutsche Med. Woch.*, 1907, S. 845).

How does infection occur in the human conjunctiva when there is no such irritation—*e.g.*, when it is inoculated from a bouillon culture? Does the lid pressure drive the bacteria in? Are the pathogenic organisms alone taken up by the conjunctiva, which they damage, on account of special affinity, or are the others taken up also, but have no action? How do the epithelial cells manage to take up the

Bacteria? Does their transport occur by the leucocytes? Where are the organisms during the period of incubation? In connexion with this last query is an interesting and peculiar fact: After the infection of the human conjunctiva with *Diplobacilli* the organisms first disappear—or, at any rate, are not demonstrable (Morax, Axenfeld)—and again show up on the third or fourth day, with the onset of the inflammation. We know that during the inflammation the causal organisms lie partly in the epithelial cells. Perhaps this is also the case during the incubation. The reactions of the rabbit's conjunctiva, which is notoriously very seldom the site of an inflammation, will presumably never throw light on this question.

When an infection occurs, and the organisms obtain a hold, they develop their toxins. The researches of Morax and Elmassian, which have a special theoretical interest, show that the toxins have an influence on the special type of conjunctivitis which then develops.

They continuously instilled dead and filtered cultures of organisms for hours into the conjunctival sacs of rabbits. As *Gonococci*, Koch-Weeks bacilli, and *Diplobacilli* do not grow on the conjunctiva of animals, this method appeared the only way of obtaining in animals results similar to those in man.

With *Gonococcus* toxin, instilled every two minutes for four to five hours, they obtained in twelve hours a severe inflammation, which subsided after twenty-four hours. The intensity of the reaction varied with the virulence of the culture. The toxin retained this action when heated to 58° C., but rapidly lost it at any higher temperature. Similar, but shorter, instillations in men had the same effect.

Morax and Elmassian then tried whether any curative action on trachoma was possessed by this toxin; they found none.

Dead filtered cultures of *Diplobacilli* and Koch-Weeks bacilli had much less action, and in their case, too, the irritation began several hours after the instillations had ceased.

The toxin of highly virulent *Staphylococci* acted like that of the *Gonococcus*.

Diphtheria toxin produced the most violent reaction. The first irritation showed ten to eighteen hours after an instillation of from six to eight hours; after about twenty-four hours of severe inflammatory swelling, the first signs of a pseudo-membrane occurred. The intensity of the process increased for forty-eight hours, when the typical appearance of a diphtheria was presented; then gradual subsidence occurred, and healing in four to five days. A stronger concentration of the toxin does not shorten the incubation period or the course of the inflammation; it only produces more severe general symptoms. When the epithelium is intact, the toxin passes in very slowly; when it is damaged, the passage is rapid, and a well-marked keratitis develops.

In contrast to these toxins, many other poisons act after single applications—*e.g.*, snake venom and abrin. The former acts at once, the abrin only after twelve hours' incubation.

Randolph,[1] on the contrary, denies that instillations of filtered cultures continued up to eight hours will produce an inflammation in the healthy conjunctiva (he tested cultures of *Gonococcus*, *Staphylococcus pyogenes aureus*, *Staphylococcus*

[1] 'Rôle of Toxins in Inflammations of the Eye,' Bull. Johns Hopkins Hospital, Baltimore, 1903, xiv. 47.

albus epidermidis, *B. coli*, *B. diphtheriæ*, *B. xerosis*, *Streptococcus pyogenes*); injections into the conjunctiva or anterior chamber, however, will produce a reaction. But if an epithelial defect occurs, then the reaction occurs with simple instillations. He considered injection under the conjunctiva as a delicate test of toxic action.

We should not, however, be justified in attributing the positive results of Morax and Elmassian to unintentional injuries. More recent investigation by Tschirkowski in my laboratory has confirmed Morax and Elmassian's results completely.

Valenti[1] made the remarkable observations concerning *coli* toxin: that a conjunctivitis followed its subcutaneous injection away from the eye; eight to ten hours after the injection the excretion of the poison from the blood began in the conjunctiva; the organisms previously present on the conjunctiva became more virulent under the action of the toxin, and took part in producing a conjunctivitis. Tschirkowski was only able to confirm Valenti's results in part (*A. f. O.*, 1908).

The interesting work of Coppez shows to what extent toxins from the conjunctival sac act upon the cornea.

According to him, diphtheria toxin, even without the action of pyogenic cocci, can produce an intense reaction, and destroy the corneal tissues wherever a defect in the epithelium occurs. It is also able gradually to loosen the intact corneal epithelium.

Streptococcal toxin has very little action upon the cornea, even if there be an epithelial defect. From his own results Coppez considered that the contradictory findings of Bardelli were due to the fact that he did not use a filtrate, but a bouillon culture, in which the cocci were killed by some added disinfectant.

Pneumococcal toxin had very little effect, even when there was an epithelial defect.

Coppez did not use staphylococcal toxin. He considered that Solowiew and Molodorowsky's results are in need of confirmation.

From these accounts we can readily appreciate to what extent corneal complications, in the various forms of conjunctival infection, are due to the action of the toxins alone. The actual entry of the bacilli, present as the cause of the conjunctivitis, is the most important factor; their development, however, is more or less assisted by the toxins. In this respect all the others are far behind the diphtheria toxin.

The statistical data which we have given show that there is still a considerable proportion of conjunctival inflammations which is *bacteriologically negative*, in which we find nothing, or only those organisms to which we cannot attribute any causal significance.[2] With such negative or negligible findings, we may ask whether a traumatic or chemico-physical factor may not be at work (such as malposition, inturned cilia, concrements, the action of dust,[3] steam,

[1] *Arch. di Ottal.*, 1900, viii. 20.

[2] To attribute a causal significance, as Randolph does, to the common *Staph. albus* and *Bacillus xerosis*, which are often found, is not justifiable.

[3] The action of grit or caterpillar's hair can produce a kind of conjunctivitis.

etc.); or whether an irritated condition of neighbouring parts—lids,[1] etc.—may not be reacting on the conjunctiva.

The following possibilities may occur:

1. The causal agent, even though the disease be due to microparasitic contagion, may not be demonstrable by any of our methods. This is till now the case in trachoma (conjunctivitis granulosa), as well as in a certain number of follicular cases of conjunctivitis which are definitely infectious.

The possibility of some still unknown Bacteria being the cause, occurs with greater or less likelihood in other conjunctival inflammations—*e.g.*, in spring catarrh (?), some of the scrofulous forms, and Parinaud's conjunctivitis.

But in negative cases, and especially in those numerous sporadic cases which are not contagious, or appear not to be, we must consider:

2. The possibility whether, and to what extent, there may be an endogenous irritation affecting the mucous membrane.

At first glance this possibility seems very remote. Can a catarrh of a mucous membrane be caused by some detrimental influence, which is brought to it by the blood-stream?

In bilateral affections, what can localize an infective *causa nocens* in the conjunctiva? Is not this mode of origin always very hypothetical and extremely unlikely; and should we not rather presume, in these negative cases, that the cause, though entering from without, is not to be detected by our present research methods?

Such considerations are very much to the point, and it would be quite wrong were we simply to say, in the cases still indeterminate bacteriologically, that they are endogenous, just as diseases were attributed formerly to a 'chill.'

On the other hand, we are obliged to admit, as many do, the possibility of endogenous conjunctival inflammations, seeing that we definitely know of several indubitable endogenous forms.[2]

The Danish surgeons Brandes,[3] Larsen,[4] and Bergh,[5] first drew attention to the fact that an endogenous gonorrhœal conjunctivitis

[1] Such a secondary conjunctivitis is recorded in a case of molluscum contagiosum of the lids (Peters, Elchnig).

[2] Endogenous infection of the conjunctiva in severe sepsis is very rare, and need not be considered with regard to acute conjunctivitis (Wagenmann, *A. f. O.*, 1888, xxxiv. 251; Axenfeld, *ibid.*, 1894, xvi. 4).

[3] 'De Ophthalmia Rheumatico-gonorrhoica et de Forma Arthropathiæ Gonorrhoica Chronica' (Hauniae, Dissertation, 1850). In this article we find a very good clinical description.

[4] 'Ugeskrift for Leeger,' 1851, S. 292.

[5] 'Bidrag tie Kundskaben om Gonorrœ,' Kjobenharn, 1860.

(Herr Lundsgaard in Copenhagen has called my attention to the articles in footnotes [3], [4], and [5], which appear to have been forgotten.)

occurs; Fournier[1] described it under the name of 'conjonctivite blennorrhagique spontanée.'

In this way he defined those cases where a conjunctivitis, usually bilateral, occurred simultaneously with the outbreak and recurrence of gonorrhœal rheumatism, where there were severe symptoms and very marked conjunctival injection, but not the severe purulent character of the common ectogenous gonorrhœa, and almost never corneal complications.[2]

Halenhoff[3] in 1887 published a series of further observations under the title of 'Conjonctivite blennorrhagique sans Inoculation,' and drew attention to the fact that such cases principally occur in men.

Van der Straeten[4] pointed out that they could be distinguished from the ectogenous blennorrhœa by the absence of the *Gonococcus* in the secretion.

Morax,[5] in his exact bacteriological research into these cases, confirmed this in general. He stated that scattered *Gonococci* may be found in such cases (the case of Nobbe is exceptional); Parinaud made the same observations (*cf.* Morax), and their results were later confirmed by Van Moll.

Naturally in a case with *Gonococci* present the objection can readily be taken that it is not a metastasis, but an ectogenous transference of infection.

In the cases of Morax and Van Moll the endogenous nature cannot be doubted, as the conjunctivitis was bilateral, began with the joint effusion, ended favourably, and recurred in the same way as did the rheumatism.

The recognition of the essential nature of these cases is not hindered by the fact that the contents of their secretions vary; they are generally negative (*Staphylococci* or xerose bacilli), but occasionally show *Gonococci*.[6]

As Morax and Axenfeld have stated, the absence of *Gonococci* can be explained in the same way as their frequent absence in gonorrhœal joint effusions. The *Gonococci* lie in the tissues and vessel walls of the conjunctiva, and can cause an inflammation of the mucous membrane without themselves occurring on the surface.[7] We must not

[1] *Gazette des Hôpitaux*, December, 1885.
[2] A further communication by Rückert followed (*K. M. f. A.*, 1886).
[3] *A. f. A.*, 1887.
[4] *Arch. Med. Belges*, July, 1891.
[5] 'Étiologie des Conjonctivites Aiguës' (*Thèse de Paris*, 1894, p. 69, and Internat. Ophth. Congress, Utrecht, 1899, discussion on Van Moll).
[6] Such occurrences of *Gonococci* will in future require a differential diagnosis from the other Gram-negative *Diplococci*.
[7] Noble, *Allg. Wien. Med. Zeit.*, 1895, No. 33.

therefore certainly conclude, from a negative examination for *Gonococci*, that the inflammation is due to a pure toxin metastasis, and not to a metastasis of the organisms themselves (though this cannot definitely be excluded, certain proof, however, is not yet available).[1] Neither would it be correct to conclude when *Staphylococci* are found in the *Gonococci*-free cases that such are mixed infections, as *Staphylococci* are very common on the conjunctiva, without having any causal significance.

Further information on metastatic gonorrhœal conjunctivitis is given in the papers by Peters and Gieler.[2] They make the important statement that recurrences in the conjunctiva can take place without any joint changes. These authors consider that in cases of acute conjunctivitis of dubious etiology the possibility of an urethral origin should be borne in mind.

Scheffels and Burchardt stated that a choroido-retinitis could occur at the same time. Becker records a swelling of the pinna of the ear along with such a conjunctivitis.

Wicherkiewicz and Bahr record similar observations, and the latter states that he has seen the same thing occur in other joint diseases. Such confirmation of the occurrence of this endogenous conjunctivitis has been given in the last few years that there is now no doubt about its actual occurrence[3] (Kaldvovitz, Knapp, Lechner, Kurka, etc.).

Its frequency and pathogenesis are still, however, a subject of controversy (*cf.* discussion in the *Wien. Ophth. Ges.*, December 6, 1905, paper by Ullmann; *Z. f. A.*, xv., S. 92; also in the Ophth. Soc. of Philadelphia, November 20, 1906, paper by Campbell Posey; and Carroll, Amer. Med. Ass., 1907, Ophth. Sec., p. 121).

Endogenous disturbances (*Schädlichkeiten*) are in question in many *exanthemata* [scarlatina, measles, erythromelalgia (Hilbert), erythema exudativum (Chaillous, Steffens, Reis), and other diseases]. The variable non-characteristic findings in measles makes us think that probably an endogenous irritation occurs.

Giarré and Picchi reported having found influenza bacilli on the conjunctiva in measles, and once or twice M. Neisser, Morax, and Schottelius similarly found large quantities of *Streptococci*. In other cases of catarrh during measles the usual conjunctivitis organisms were present, probably as complications. The variety of organism which is present has naturally an influence on the course of the inflammation, but they are generally not its primary cause.

The further elucidation of these cases of conjunctivitis of obscure etiology must therefore take into account the possibility of endogenous factors. I have myself observed that many obscure conjunctivitis cases are either accompanied or followed

[1] A localized inflammation of the eye could not be induced in rabbits into which the toxins of *Staphylococcus* or *B. pyocyaneus* had been introduced, even when severe local irritation or injury was employed (*cf.* Shimamura). The contrary findings of Tornatola are due to experimental errors (*K. M. f. A.*, 1901; *cf.* also Valenti, *ibid.*, S. 117).

[2] Inaug. Dissert., Bonn, 1897.

[3] *Cf.* also Thorner and Greeff, *Charité Annalen*, 1904 and 1905, xxviii. and xxix.; also Burnett, Jour. Amer. Med. Assoc., December 23, 1905; Demaria, *Archivos de Oft. Hist. Amer.*, 1907, vii. 119. Metastatic gonorrhœal inflammations of the lacrymal gland are analogous (*cf.* p. 230).

by a mild iritis, so that at first we have the appearance of an acute conjunctivitis, and during its subsidence the iritis becomes evident. Such a combination suggests an endogenous irritant, although it is not a certain proof that such is present. One is reminded here of the conjunctival irritation of gouty persons. It is not at all clear why general infections other than gonorrhœal do not occasionally affect the conjunctiva, especially those which involve the joints (*cf.* Wagenmann, *A. f. O.*, 1897, xliii., 1, S. 83; Desmons, 'Conjonctivite Rhumatismale,' *Thèse de Lille*, 1905).

E. Cohn, in a paper under the direction of C. Fränkel (Halle), furnishes an interesting and important observation on the question of endogenous conjunctivitis and hæmatogenous affections of mucous membranes in general—'Examination of a New Form of Hefa Pathogenic for Animals' (*Hefa*, Klein, *Centralbl. f. Bakteriologie und Parasiten*, xxxi., 1, Gbt., 1902, No. 15; also *ibid.*, xxxvi., 1904, p. 369). The direct application of *Hefa* cells either to the nasal or conjunctival mucous membrane of rabbits produced no reaction, but after intravenous injection, in two to three weeks a bilateral conjunctivitis and rhinitis regularly occurred, which not infrequently became purulent.

Hefa cells were then found in the conjunctival secretion. In a pig eight days after intravenous injection an acute purulent conjunctivitis occurred without *Hefa* cells in the secretion (E. Cohn could not account for the failure to demonstrate them, though it quite corresponds with the state of matters which we have discussed in metastatic gonorrhœal conjunctivitis). In a dog conjunctivitis occurred with *Hefæ* in the secretion. The buccal membrane remained unaffected, but the stomach was often affected.

In guinea-pigs a conjunctivitis always resulted, but in them it occurred on direct inoculation also.

Stock obtained endogenous tuberculosis of the conjunctiva experimentally.

An experimental endogenous conjunctivitis has recently been recorded as frequently occurring in a general infection of rats and mice with *Trypanosoma* (Stargardt[1]). The *Trypanosomæ* did not pass out into the conjunctival secretion, but occurred in large numbers in the tissues of the conjunctiva.

Finally we must remember Valenti's results (*vide supra*). He reports that he obtained endogenous toxic conjunctivitis, a record which was only in part confirmed by Tschirkowski; the excretion of poisons by the conjunctiva and the resulting catarrhal inflammation, however, are well-known phenomena (iodine catarrh,[2] etc.).

[1] *Berlin. Ophth. Ges.; K. M. f. A.*, 1906, ii.; and *Ber. der Heidel. Ophth. Ges.*, 1906.

[2] According to Muck, the combination of the iodine with the sulphur on the conjunctiva is the cause of the irritation (*Münch. Med. Woch.*, 1900, pp. 1168, 1732).

CHAPTER VI

THE SPECIAL FORMS OF CONJUNCTIVAL INFECTION

UNDER this heading the following sections will be considered:

SECTION 1.—**Conjunctivitis** due to the **Koch-Weeks Bacillus** and the **Influenza Bacillus.**

SECTION 2.—**Diplobacillary Conjunctivitis** (MORAX-AXENFELD). **Petit's Variety of the Diplobacillus.**

SECTION 3.—**Pneumococcal Conjunctivitis.**

SECTION 4.—**Pseudo-membranous Conjunctivitis. Diphtheria** and **Xerose Bacilli. Streptococci. Various Organisms.**

SECTION 5.—**Gonococci** and other **Gram-negative Diplococci** (**Meningococci, Micrococcus Catarrhalis**) occurring on the **Conjunctiva. Blennorrhœa** and **Ophthalmia Neonatorum.**

SECTION 6.—**Staphylococcal Conjunctivitis.**

SECTION 7.—**Rare Organisms.**

SECTION 8.—The so-called **Scrofulous Inflammations** (**Phlyctenular, Eczematous**).

SECTION 9.—**Trachoma. Follicular Affections.**

SECTION 1.—KOCH-WEEKS CONJUNCTIVITIS (INFLUENZA).

PLATE A, FIG 1.

Historical.

In the year 1883, during the cholera epidemic in Alexandria, R. Koch for the first time examined a series of cases of Egyptian ophthalmia. He found that two distinct diseases were referred to under this name. In the severe purulent form he found *Diplococci*, which he identified as very probably *Gonococci;* in the more catarrhal form he regularly found in the pus corpuscles small bacilli, which he compared to the fine bacilli of septicæmia in the mouse. He was unable to obtain cultivations.

In 1887 mutually independent papers by Weeks and Kartulis appeared.

In New York Weeks observed an acute conjunctivitis, varying in intensity—first in a small family epidemic, then in large epidemics—especially in spring and autumn, and in the interval in numerous sporadic cases. In the secretions he constantly found small, fine rods, which tended to lie in the pus cells or else free in small clusters. (His drawings agree exactly with later findings.) Their cultivation presented great difficulties, and Weeks only succeeded in obtaining a growth of the small bacilli along with a club-shaped bacillus (so-called *B. xerosis*) on 0·5 per cent. agar; the mixture could be cultivated to the sixteenth generation. He correctly distinguished the two forms of bacilli in the mixture, and gave corresponding drawings; a pure culture was not obtained. In this first paper Weeks' findings regarding the conditions of growth are therefore incomplete, and, to some extent, inaccurate. He demonstrated the great probability of the pathogenic significance of these small bacilli by inoculating on the human conjunctiva the club-shaped organism readily grown in pure culture on 1 per cent. agar, and also the mixture of the two bacilli. The mixture alone produced a conjunctivitis, which in five cases presented the clinical type, and had an incubation of thirty-six to forty-eight hours. The infection was always transferred from the inoculated eye to the other. He therefore rightly considered the club-shaped bacillus as a casual contamination of the conjunctiva.

Kartulis (Alexandria) found the small Koch bacilli. He definitely stated that this bacillary conjunctivitis had no essential connexion with trachoma, but was very often associated with it. Kartulis obviously did not obtain pure cultures, for his descriptions refer to the unavoidable xerosis. This is also the explanation why, in five out of six inoculations with his cultures, no result followed.

In 1890 Weeks reported at the International Congress in Berlin that he had now obtained pure cultures of the small bacilli and successful inoculations with them. He had obtained this bacillus in over 1,000 cases. In a further communication in the year 1895 Weeks again referred to these pure cultures, and concluded from the drawings that in every particular they were identical with the cultures which Morax had obtained in the interval.

In 1894 Morax furnished a very particular and exact description of the growth of the Koch-Weeks bacillus. From the clinical picture, which he had studied since 1891, he was aware that the intensity of the inflammation can vary. The little bacilli were absolutely non-pathogenic for animals, but, on the other hand, Morax produced on himself a typical acute conjunctivitis with one drop of a serum bouillon culture (third generation) after an incubation of forty-eight hours. In a later paper Morax states that the colonies are very like those of influenza; and in a still further communication Morax and Petit note that the name *Conjonctivite aiguë contagieuse* did not correspond merely to that conjunctivitis due to the Koch-Weeks bacillus; but, as Axenfeld and Gifford had shown, a pneumococcal conjunctivitis can also occur in an acute contagious form.

In the same year (1894) Wilbrand Saenger and Staehlin reported that they had found the bacillus in an extensive epidemic in Hamburg, freely mixed with *Diplococci* which resembled *Gonococci*, but were not decolorized by Gram's stain. In such cases there was a great development of follicles; this, however, did not occur in those cases which only contained the bacilli. With regard to their cultures, there were definite variations which made it doubtful whether these authors did really obtain pure cultures. A later communication from Wilbrand (discussion on Axenfeld's paper, *Heidel. Oph. Gesell.*, 1896) stated that since the great epidemic in Hamburg sporadic cases were continuously being observed.

Further comprehensive researches were communicated by Weichselbaum and Müller regarding a relatively slight epidemic in Ziersdorf (Lower Austria). The authors point out the want of agreement among, and even the contradictory statements of, the earliest workers on the Koch-Weeks bacillus, and attribute them to the

difficulty in obtaining pure cultures, also to some confusion of the organism with the *Bacillus xerosis* present along with it. (Weichselbaum and Müller, however, go too far in their criticism when they see a contradiction in the fact that Weeks never observed corneal complications, while Morax did. Such a variation in the same disease is quite possible.) Weichselbaum and Müller obtained cultures almost exclusively with human serum agar, most readily when at the same time a few xerose bacilli were present in the culture.

They obtained a positive inoculation on the human conjunctiva in ten cases, mostly with pure cultures, and thus demonstrated that from apparently mild cases a severe result can be produced in other people, and that a kind of latency may occur, during which the bacilli lie concealed for a considerable time in an apparently healthy person.

The further examinations made by L. Müller in Egypt are of very great interest, especially with regard to trachoma and his 'trachoma bacillus' (the influenza bacillus). He demonstrated anew the morphological similarity of the Koch-Weeks bacillus with his own and the influenza bacillus, and convinced himself of its 'pandemic occurrence.'

In the extensive epidemic observed by Kamen in 1899 at Czernowitz the bacilli, of which the author obtained excellent photographs, could be readily grown for many generations on media containing human blood. Kamen emphasized their close relationship to the influenza bacillus, with which they form a group.

A thorough investigation was made by Hofmann in the Greifswald clinic. The disease, introduced into that district by the Polish labourers, presented the peculiar clinical feature of a chronic course, associated with profuse development of follicles. Three inoculations of the human conjunctiva with a pure culture gave a positive result.

An extensive epidemic was observed by Markus in the elementary schools of Bitterfeld; five adults were also affected. The patients, to some extent, showed marked follicular overgrowth, and in the early stages phlyctenules regularly occurred, along with small hæmorrhages under the conjunctiva, especially the upper.

Rymowitsch (Kasan) is very definitely in favour of the complete identity of the Koch-Weeks and the influenza bacillus, an opinion also held by Jundell. The latter observed an acute conjunctivitis in children, with simultaneous bronchitis, and sometimes typical influenzal temperatures. The organisms in these cases agreed exactly with those of influenza, and, like them, grew well on blood media. Zur Nedden had previously found the influenza bacillus, which he rightly distinguished from the Koch-Weeks organism. Luerssen obtained a positive result on infecting his own conjunctiva with Koch-Weeks bacilli, obtained from a case of trachoma. He gave a full comparison with the influenza bacillus (Müller's bacillus), and proved their separate identity. He found the Koch-Weeks bacillus in the nose, but no inflammation occurred in that site.

Further less important contributions to the subject will be shortly noted later.

Geographical Distribution. Epidemiology.

The preceding historical account shows that Koch-Weeks conjunctivitis is very widespread over the earth.

It has been demonstrated in Egypt (Koch, Kartulis, L. Müller, Morax, Lakah and Kouri, Meyerhof); in Palestine (Butler); in North Italy (Gasparrini); in Siena (Giarré and Picchi, Corsini, Cannas); in Paris (Morax, Panas); in Amiens (Fage); Toulouse (Mallet); in French Switzerland (Gonin); in Brussels (Coppez, Wibo); in

Copenhagen (Lundsgaard); in Kasan (Rymowitsch); in Kiew (Gromakowski); in Czernowitz (Kamen); in Lemberg (Dudzinski, Dziennik, *Tyagda lekarzy* 1900, No. 3); in Budapest (Scholtz and Vernier); in Germany, Hamburg (Wilbrand, Saenger, Staehlin); in Greifswald (Hofmann); in Rostock (Axenfeld); in Halle (Markus); in Bonn and Cologne (Zur Nedden, Saemisch); in Freiburg (Axenfeld—here comparatively common); in Königsberg (Luerssen); in England (Sydney Stephenson, Mayou, Juler, Griffith, Thomson); in Scotland, Glasgow (Pollock); in Aberdeen (Usher and Fraser); in North America, New York (Weeks, Duane, Hastings); in Bridgeport (Dorland-Smith); in Chicago (Brown-Pusey); in Philadelphia (Veasey, De Schweinitz, Shumway); in Montreal (McKee); in Cuba (Santos Fernandez). We have the report of Elmassian that he found it very frequently in Paraguay. Subow found it in Transcaspian Asia; and, according to De Haan, it occurs also in Java; McDill and Berry found it in the Philippines, and Perry and Castellani in Ceylon.

There is no doubt that this infection would be found in many other places if carefully looked for; perhaps no land or climate is free from it.

It would, however, be a mistake to consider it as equally distributed everywhere.

There are many trustworthy observations available, in which, in spite of numerous and expert examinations[1] of large numbers of inflamed conjunctivæ, the Koch-Weeks bacillus, during long periods of time, was never found. Gifford (Nebraska, U.S.A.), who found pneumococcal conjunctivitis very often, definitely states that, in his district as opposed to New York, the Koch-Weeks bacillus did not occur. Brown-Pusey reports the same in Chicago. Veasey in Philadelphia found *Pneumococci* in abundance, and Koch-Weeks bacilli much more rarely. Lundsgaard reports similarly from Copenhagen. Axenfeld never found it in Marburg and Breslau, and only sporadically in Rostock in Polish immigrants, though pneumococcal conjunctivitis was common. Hanke only found it exceptionally in Vienna. Bach and Neumann similarly in Würzburg.

We see, then, that in the localities where Koch-Weeks conjunctivitis is observed its frequency varies very much; after a temporary epidemic period, in spite of its contagiousness, it can remain for a long time in abeyance (*e.g.*, in Hamburg), while in other localities it is endemic, with a constant even frequency (*e.g.*, in Freiburg, where it has never yet been epidemic). We must therefore conclude that its spread, like that of other infectious diseases, depends on particular climatic or other specially predisposing circumstances which have not yet been definitely determined.[2] There are also some striking differences recorded. In one place (*e.g.*, Freiburg) the Koch-Weeks bacillus only causes a very small proportion of the total number of acute conjunctivitis cases, while in other places they are so very commonly associated with this clinical appearance that they were at first designated as the cause of acute contagious conjunctivitis: such is the case in Paris and New York. In Glasgow (Pollock) in 236 cases of acute conjunctivitis 177 were due to Koch-Weeks bacillus. The same is the case in Aberdeen (Usher and Fraser).

[1] It should be noted that the Koch-Weeks bacillus is just one of those organisms which the beginner is liable to overlook if they are not plentiful and well stained in light cells. Diffusely stained preparations must be very carefully examined. Regarding the observers quoted above, we can conclude that they were familiar with the Koch-Weeks bacillus.

[2] See Axenfeld, 'Ergebnisse'; Lubarsch-Ostertag, 'Bakteriologie des Auges.'

According to the older accounts, the frequency of this catarrh in Egypt appears to increase in summer; the trachoma, which was very frequently also present, became more catarrhal. These exacerbations were associated with the high Nile. The large numbers of flies then present, perhaps, spread the infection more readily (L. Müller, Lakah, and Khouri). Lakah and Khouri decided that the maximum of the Koch-Weeks infection is in the months of May and June (for gonorrhœa of the conjunctiva from July to October). This has recently been confirmed by Meyerhof. The maximum, therefore, begins, in the case of Koch-Weeks, before the rise of the Nile. The increase especially affects children; therefore it is not merely due to the temperature. Perhaps the infective material may remain longer virulent in the warm air. L. Müller attributed the increase to the greater moistness of the air; there is some slight correspondence between the two conditions.

We cannot yet definitely say which of all these circumstances is determinative. The frequency of corneal complications in Koch-Weeks conjunctivitis was greatest in the months of May and June. Meyerhof recently stated that the actual temperature, not the moistness, sun, or dust, is the important factor, and that the Koch-Weeks conjunctivitis first becomes epidemic when the noonday temperature reaches 18° R. (72·5 F.).

Weeks records an increased frequency for New York in spring and autumn. Morax, after years of observation, could not find for Paris any seasonal variation. Chills which appear to favour a pneumococcal conjunctivitis appear to have no such influence on Koch-Weeks conjunctivitis. (There are no grounds for the assertion that the epidemic spread of this form of conjunctivitis runs parallel with the spread of epidemic influenza. The records of Koch-Weeks conjunctivitis in Egypt, which is widespread, and still unchanged in frequency, date from a time previous to the last wave of influenza. This is a fact opposed to the identity of the Koch-Weeks and influenza bacilli.)

Clinical Appearances.

Descriptions, especially those of experimental inoculations on the healthy human conjunctiva (Weeks, Morax, Weichselbaum, Müller, Hofmann, Luerssen), agree that the incubation period is relatively short. The time is given by Weeks and Morax as thirty-six to forty-eight hours; Weichselbaum and Müller generally observed the same interval; Hofmann found symptoms twelve hours after inoculation, and in twenty-four hours the full clinical phenomena; Luerssen found flakes of pus in four hours, and in twelve hours a profuse

thick purulent secretion. Within a few days after the inflammatory symptoms commence they reach their maximum.

The *lids* redden along their margins, are slightly swollen, and stick together in the morning; but, except rarely in very severe cases,[1] they can be spontaneously opened. A muco-purulent secretion collects on the margins and angles of the lids, and is profusely discharged, mixed with tears. The secretion of the meibomian glands is often markedly increased (Bishop Harman, Pollock). There is often photophobia; the eyes are hot and painful. In bad cases severe circumorbital pain and headache may occur. In the early stages of very severe cases Morax observed pain in the upper jaw, and a painful swelling of the pre-auricular gland. There is well-marked redness of the *conjunctiva palpebrarum*, which is distinctly swollen, and generally appears smooth and shiny. Not infrequently slight pseudo-membranes form (when they occur in the '*forme suraiguë*' they may be well marked). The development of follicles does not occur in inoculation cases. When follicles are found in large numbers a mixed infection may be presumed (Wilbrand, Saenger, Staehlin, Pollock). Markus and Gromakowski consider that in cases which begin subacutely, or continue chronically, the follicles are partly caused by the Koch-Weeks bacillus. In Egypt and in trachomatous countries we often find a granular conjunctivitis along with the Koch-Weeks catarrh (Kartulis, Müller, Morax, Luerssen, etc.). In the same way scars are seen.

The *conjunctiva bulbi* is very red; in severe cases this redness is intense, sometimes with a bluish tint, and at the height of the disease there is slight chemosis. Müller states that the conjunctiva bulbi is mainly affected, and has a characteristic bluish tint. Sometimes (in Markus' epidemic very often) we find small hæmorrhages in it: these are commonest in the upper part; according to Stephenson, more often in adults than in children. Morax considers these hæmorrhages characteristic, but they can occur in pneumococcal conjunctivitis. At the limbus conjunctivæ small cloudy vesicles often form. Morax distinguishes these from true phlyctenules in that they are true vesicles filled with fluid, and not nodules of leucocytes, like true phlyctenules. In Egypt L. Müller saw phlyctenules only in scrofulous children.

In the several members of a family infected from the same source the symptoms may vary considerably in severity, and in children especially they are often much milder than in adults. I have often found, for example, the father with a very severe conjunctivitis and the children with a mild catarrh, but all showing large numbers of Koch-Weeks bacilli.

Infiltrates sometimes form in the cornea, near the margin or else centrally, and not infrequently more severe ulceration may develop (Morax and Petit, Shumway, Meyerhof, Terlinck). Severe corneal complications are relatively more common in adults than in children (Morax, Meyerhof). They occur in the first few days of the disease.

The acute cases of moderate severity usually last two to four weeks; it is rare for the appearance of a severe conjunctivitis to remain for months. The duration depends very much on the treatment. Untreated, the condition can be so prolonged that, as Hofmann and Markus have recorded, a considerable papillary hypertrophy of the conjunctiva remains, especially in the upper fornix, in the crevices of which the bacilli seem to linger. After a long continuance the discharge and the inflammatory reaction abate, and the appearance of a moderate chronic conjunctivitis develops; these cases are liable to recurrence, and are capable of infecting other

[1] L. Müller considers the cases called '*conjonctivites suraiguës*' by Sameh as belonging to this class. There is, however, no bacteriological evidence yet available of their identity with Koch-Weeks conjunctivitis.

people. Recurrences very often do take place and at short intervals (Morax, Usher and Fraser, Meyerhof).

Although slight cases often heal rapidly, their duration is not necessarily less than that of the severe ones.

According to L. Müller, there is a tendency in Egypt for the catarrh to be less acute in those adults who have trachoma scars (Meyerhof contends that such is not the case when gonorrhœa is superimposed on trachoma). In adults generally the catarrh is milder in type. Sydney Stephenson states that in adults there is a tendency for the conjunctiva bulbi to be more involved, and to be hæmorrhagic. In very severe cases at first the appearance is very like that of a blennorrhœa, although no *Gonoccocci* are present; the cornea, however, is rarely involved to a severe extent. The conjunctiva may become covered with a pseudo-membrane, and the pre-auricular gland be greatly swollen. Peripheral corneal infiltrates occur in the severe but infrequent membranous cases, and it is in this class that L. Müller would put the Egyptian '*conjonctivite suraiguë*.' The corneal complications are not necessarily due to mixed infections, as Weeks formerly thought, but can be caused by the Koch-Weeks bacillus. Morax once recorded the simultaneous outbreak of a *herpes zoster frontalis*.

The disease first affects one eye, but almost always becomes double-sided, unless prevented by treatment.

The general health is only disturbed in very severe cases from pain and sleeplessness. Fever symptoms and such-like have not been described. A slight cold in the head occurs during the affection, but the deeper parts of the naso-pharynx are not affected (Morax).

The Examination of the Secretions.

The very fine, slender bacilli are found, often in large numbers, during the onset and at the maximum of the affection; they can be seen, too, in the chronic cases. The organisms lie in and between the leucocytes. Of these latter, the large polynuclear predominate, in contrast with the rarer large or small mononuclear, and the very rare eosinophile and basophile cells (Mayou). When the bacilli are free they tend to lie in clusters, but are also commonly found singly. The phagocytes generally occur in large numbers, and we often see in each field numerous cells which are packed full of bacilli.

The bacilli resemble those of mouse septicæmia, and to some extent too, those of influenza. They are, however, longer and thinner than the latter. Their length varies: some are not much more than 0·5 to 1 μ long; others are longer, up to 2 μ. The latter resemble long filaments. The short bacilli tend to occur in pairs, and even form short chains; sometimes there is a suspicion of polar staining. The ends of the rods are slightly rounded. The breadth of the bacilli is very constant; they are extremely slender. Their relative positions with regard to each other vary.

The bacilli completely and rapidly decolorize in Gram's stain. They stain best with very dilute carbol fuchsin (ten minutes), Nicolle's

carbol thionin, or warm Löffler's methylene blue, but as a general rule do not take up any stain very intensely. With safranin, which is often used as a counter-stain, they only stain feebly.

FIG. 11.—SECRETION PREPARATION (FREIBURG). × 1,000.

In a smear preparation as a rule only Koch-Weeks bacilli are seen, or at most a few cocci or other bacilli (especially xerosis) also. Of course, it is presumed that material is not taken during the subsidence of the disease, when the saprophytes again become prominent.

The apparent contradiction between the absence of *B. xerosis* in the smear and its almost invariable presence in the cultures, not infrequently with some *Staphylococci* also, is due to the fact that, although in small numbers, it grows much more rapidly, and so becomes prominent in the cultures.

FIG. 12.—SECRETION, PARIS EPIDEMIC (MORAX). × 1,000.
Some of the bacilli are represented rather too thick.

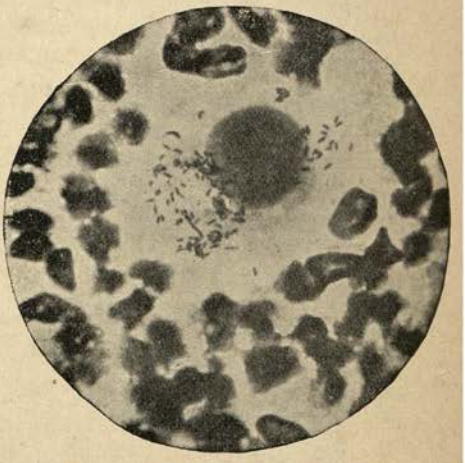

FIG. 13.—SECRETION, CZERNOWITZ EPIDEMIC (KAMEN). × 1,000.

Mixed infections due to the Koch-Weeks bacillus, with *Gonococci Pneumococci*, or *Diplobacilli*, are not common according to general experience. No specially characteristic clinical features have been noted in such cases, except in the case of the complication with gonorrhœa observed so often in Egypt. Meyerhof on one occasion found diphtheria bacilli along with them, and after the Koch-Weeks bacillus had disappeared these others caused the formation of a slight pseudo-membrane. Morax reports a Koch-Weeks infection as superadded to the exanthematous irritation of the conjunctiva in an epidemic of measles. The Koch-Weeks bacillus has a great tendency to occur in trachomatous cases, when it presents the deceptive clinical appearances of acute trachoma. In the epidemic recorded by Wilbrand, Saenger, and Staehlin, the Koch-Weeks bacillus had often associated with it *Pseudo-gonococci*—*i.e.*, *Diplococci* belonging to the group of the *Staphylococci*. These are the very cases which various authors state to be associated with follicle formation, and they call to mind the follicular epidemic of Michel and Sattler.

When the secretion diminishes, the specific bacilli rapidly disappear. They may, however, remain latent for a long-time when the powers of resistance are low (Morax, Hofmann, Meyerhof).

Concerning the vitality of the bacilli in the secretion, see under heading ' Contagion,' p. 145.

Cultures.

The Koch-Weeks bacillus will only grow at brood temperature. Of all the ordinary media the only one which is even occasionally successful is very moist peptone agar (0·5 per cent.) of low alkalinity, and then only when plenty of the secretion is taken. Only very few investigators have thus succeeded in obtaining one generation (Morax once obtained three), and prolonged cultivation is quite impossible. Morax definitely states that cultures are only successful when very virulent organisms are obtained from severe inflammations. Weichselbaum and Müller did not allow of the identity of the organisms which they had cultivated with those of Morax, because they could not obtain growth on simple agar; but Morax correctly pointed out that their cases had been much milder.

Generally speaking, some specially prepared medium is necessary.

Morax, Weichselbaum, and Müller found Wertheim's serum agar best (addition of ascitic, ovarial cystic, or hydrocele fluid, etc.). On such media Morax obtained 100 generations; Usher and Fisher obtained 50. Hofmann found Wassermann's pig's serum nutrose agar useful; later, he used a mixture of 2 parts weak glycerine

peptone agar[1] and 1 part of ascitic fluid, containing sheep's or human blood in the proportion of 1 to 2. Hofmann could not obtain cultures on simple agar with human blood added.

Kamen and Markus obtained very good results with Pfeiffer's blood media (human blood), on which they were able to grow the bacilli with certainty and for many generations. They did not use pure serum agar.

Weichselbaum and Müller at first stated that the Koch-Weeks bacillus would only grow on serum agar; later they obtained cultures on blood media from a few cases.

The different epidemics seem to vary somewhat in regard to culture peculiarities. Kamen's and Markus's cases were very acute and severe, considerably more so than those of the epidemic observed by Weichselbaum and Müller, or Hofmann's cases. The media and the blood used are not always the same. Considering all the records together, we find that the Koch-Weeks bacillus grows best on serum agar or in serum bouillon, but that it can be grown on blood media, though this method is not so certain in all epidemics. Regarding its relationship to the influenza bacillus, it should be noted that human (not pigeon's) blood only should be used.

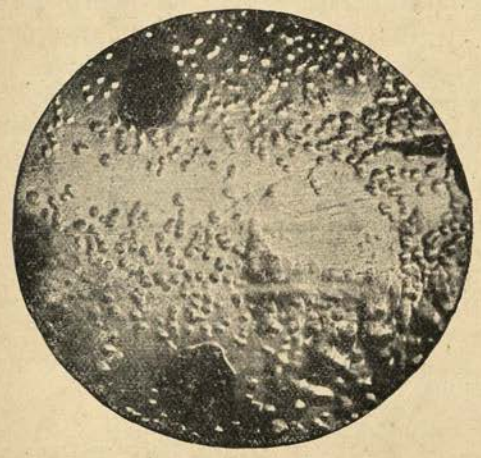

FIG. 14.—KOCH-WEEKS CULTURE ON BLOOD AGAR (KAMEN).

The large colonies are *Staphylococci*.

Luerssen reported, however, that he had succeeded in growing a strain of Koch-Weeks beyond the fiftieth generation on pigeon's-blood agar, and that without any assisting organism being present. He considered the Koch-Weeks bacillus as one of the Hæmophile group, and put it in the same class with the influenza bacillus, although quite distinct from that organism. Zur Nedden considers that the human serum which is obtained with the blood makes the cultures possible.

The bacilli are rarely obtained in pure culture; they are generally accompanied by xerose bacilli, and often by a few *Staphylococci*. As has been stated by Rymowitsch, Usher and Fraser, and as I have myself determined, the simultaneous presence in the cultures of xerose bacilli, of diphtheria bacilli, or of *Staphylococci*, favours the growth of the Koch-Weeks bacillus.[2] Weichselbaum and Müller stated that the same was true for the so-called 'Luft-keime' (following the view of Grassberger in so naming the staphylococcal group). Usher and Fraser found that growth was favoured by the presence of the *Diplobacillus*, and that stems of the Koch-Weeks, which could not be further

[1] Kamen could not get any growth on this.

[2] In a similar way the xerose bacilli favour the growth of the influenza bacillus (M. Neisser), with which the Rymowitsch bacillus should be considered as identical.

cultivated directly, could be grown in symbiosis with suitable organisms, and then might even continue to grow alone.

It is not absolutely necessary, in order to obtain cultures, that such other organisms be present; for, in case of severe infections with very vigorous bacilli, pure cultures can readily be grown and propagated.

FIG. 15.—KOCH-WEEKS BACILLUS ASCITES AGAR CULTURE. × 1,000.
The large dark bacilli are *B. xerosis*.

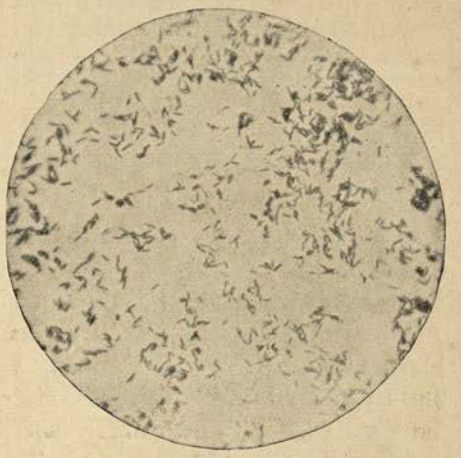

FIG. 16.—CULTURE OF KOCH-WEEKS BACILLUS (KAMEN). × 1,000.

After twenty-four to forty-eight hours, the colonies of Koch-Weeks bacilli can be recognized as moist, transparent, refractile points or drops. When their surface is focussed under a low magnification, they look like small air-bubbles; when their margins are sharply focussed, they appear round. They lie loosely on the surface of the medium, and can readily be removed. At first they resemble colonies of influenza; like these, they appear regular in contour and homogeneous in consistency when under the loupe. Under greater magnification (× 80) a fine stippling, reaching out to the margin,[1]

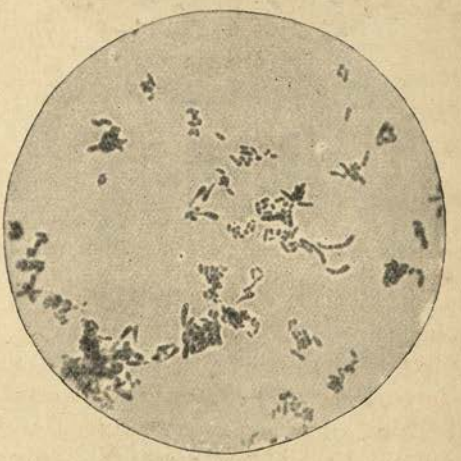

FIG. 17.—XEROSE BACILLI FROM CASE OF KOCH-WEEKS CONJUNCTIVITIS (KAMEN).

[1] According to L. Müller, this fine granulation is a point of differentiation from his, or rather the influenza, bacillus. Luerssen states that such is not always the case, as the influenza colonies may sometimes show finely granular colonies.

can be seen in the colonies. They have no great tendency to coalesce. According to Zur Nedden, they are not so sharply bordered as are the influenza colonies, and more rapidly become lost to sight on the medium. When isolated colonies occur, especially if such be near to any of the other organisms we have mentioned, their contour may be slightly wavy and their appearance more opaque and granular; a yellowish colour may sometimes be noticed.

In serum bouillon, and also blood bouillon, a faint diffuse cloudiness occurs, which later sinks as a deposit to the bottom of the tube.

Morphology.—The bacilli in cultures, as in the secretion, appear to be very slender and of varying length. Long filaments are often seen, sometimes long, coiled, involution forms, of somewhat greater thickness.

Morax recorded these; Hofmann found them very plentifully in old colonies; Weichselbaum, Müller, and Kamen also describe them; and I have often seen them myself. The ends of the long forms are sometimes slightly thickened; these, however, should not be confused with the xerose bacilli, which are much thicker, and besides, are stained positively by Gram (see Figs. 15, 16, 17).

The bacilli are non-motile; they decolorize rapidly with Gram; they are aerobic.

Resistance of Cultures.—The bacilli rapidly die in cultures; after five days, and often much less, they can no longer be propagated. Growth ceases at 20° C., but, if kept moist, they remain alive for sixty hours. After heating for ten minutes to 50° C., some of the bacilli still remain alive, but they can only withstand a temperature of 60° C. for one to two minutes. Weichselbaum and Müller found their cultures dead after fifteen minutes at 60° C.

Hofmann satisfied himself that the bacilli were not killed by an hour and a half at 70° C. He considered it possible that, under favourable circumstances, the organisms could remain alive for a longer time outside the body. In liquid human serum at brood temperatures they live for six days.

Half an hour's exposure to the sun's rays did not kill the bacilli in culture when kept at 43° C., but after two and a half hours they were no longer alive.

Contagion. Prophylaxis.

Wilbrand, Saenger, and Staehlin considered that transference by the air must be presumed to explain the extraordinarily rapid spread of the epidemic which they studied.

The researches of Weichselbaum and Müller do not favour the view that the Koch-Weeks bacillus is transferred in the dried condition. These authors introduced flakes of secretion into dry Petri dishes. In six and a half hours the secretion could no longer be cultivated. The secretion from a newly-affected child, after being dried for eight hours, produced no infection when introduced into the healthy human conjunctiva, though the fresh moist secretion did so. Further experiment showed that no living bacilli could be found in the secretion when completely dried. Hofmann found that after three hours in a dry Petri dish at 20° C. the bacilli in the exudation masses were quite dead. Under these circumstances, therefore, Koch-Weeks bacilli must be held to be incapable of resisting dryness.

There is, however, another mode of contagion in which the air plays a part, which, however, has till now been neglected.[1] Infected material, in the case of such a catarrhal secretion, may pass down into the nose and also into the mouth; this more readily occurs through the nasal duct on account of the simultaneous cold in the head and lacrymation. It is not unlikely that a spray infection (*Tröpfchenverstäubung*, Flügge) may occur, and thus reach other eyes by means of the air.[1] I have found *Diplobacilli* in the angles of the mouth in diplobacillary conjunctivitis (see Lobanow, *A. f. O.*, li., 1898), and a similar condition would occur more readily in the Koch-Weeks catarrh, with its much more profuse discharge. (In connexion with the relationship of the Koch-Weeks to the influenza bacillus, it should be noticed that the latter also stands dryness very badly, but in a moist condition resists longer.)

Transference generally occurs by contact, by an immediate or mediate transference of the secretion. After fifteen minutes Müller and Weichselbaum could not obtain cultures from tap water into which a pure culture had been introduced, and similarly Hofmann showed that particles of secretion, after three hours in either distilled or tap water at 20° C., were no longer infectious. If kept in the incubator, even after this interval they were infectious; and living bacilli were found in normal saline at 20° C. after seven hours. When simply laid in a moist chamber, the bacilli in flakes of exudation remained alive for eighteen hours.

We must consider that water can act for a short time as the medium of contagion; on moist linen, etc., masses of secretion can remain infectious for a much longer time. In Egypt Koch em-

[1] C. Fränkel, in his work on 'Meningococcal Conjunctivitis,' mentions this possibility.

phasized the oft-repeated possibility that flies, which are very numerous there, may assist in the widespread infection.

As is shown by the work of Morax, Weichselbaum, Müller, and Hofmann, we must also emphasize that the chronic forms, with their slight and readily overlooked inflammatory symptoms, can serve to spread the affection for months. The subsidence and reappearance of epidemics can thus be explained.[1] Meyerhof similarly speaks of chronic infection with acute exacerbations.

Regarding the *pathological anatomy* of such cases, Morax and Mayou found widespread mucous degeneration of the epithelium and infiltration of the mucosa, at first with polynuclear cells especially, later with lymphocytes and plasma cells.

(*Prophylaxis* directed against the Koch-Weeks bacillus takes the form of cleanliness, and careful avoidance of direct or indirect contamination with the secretion. Severe cases should be isolated. Schools should be closed when they contain many severe cases. In all cases those affected should be excluded.

The most valuable *treatment* consists in the use of 1 to 2 per cent. argenti nitras solution. Zinc, which is so useful in other infections, especially the diplobacillary, is not much use in these cases.

Thorough treatment of cases tending to become chronic is important.)

Pathogenicity. Disposition.

Morax, Hofmann, Weichselbaum, and Müller carried out experimental inoculations, and found that the Koch-Weeks bacillus had no action on animals. Monkeys, dogs, rabbits, guinea-pigs, rats, mice, fowls, pigeons, calves, and young pigs proved refractory to all kinds of subcutaneous injections and conjunctival infections. Even after a condition of severe irritation had been produced in the conjunctiva, as was done by Morax with jequirity to supply a disposition, no bacterial action on the conjunctiva could be produced. At the site of infection no organisms could be found after twenty-four hours. Kamen alone once obtained a transient inflammation after inoculating a rabbit with some of the pus.

The bacilli, at any rate, cannot grow in the bodies of animals. Rymowitsch attributes to them a toxic power similar to that of influenza bacilli, which in large doses have a toxic action.

The human conjunctiva, on the contrary, is very susceptible to

[1] Note that the same occurs in the case of influenza. Bäumler, Pfeiffer, Wassermann, Clemens, Parsons, and others, have demonstrated this long persistence, and attribute fresh outbreaks of the epidemic to it.

them. The contagiousness is so very great that every one of the fifteen inoculations which have so far been made, and mostly with pure cultures, have caused the disease (Morax, Weeks, Weichselbaum, Müller, Hofmann, and Luerssen). Hofmann obtained this result with cultures 110 to 120 hours old. Only once did Müller fail to obtain a positive result on inoculating his own conjunctiva with an attenuated virus (how reduced was not stated). Even in Weeks' six inoculations with mixed cultures five were positive.

An almost invariable susceptibility therefore appears to exist. Koch-Weeks conjunctivitis is to be classed with the most contagious infectious diseases which we know of. The course of these artificially induced inflammations and the findings in their secretions quite correspond to those of the original affection from which the material was obtained. By continuous instillations for several hours of a sterilized (heated to 58° C.) or of a filtered culture, Morax and Elmassian obtained a transient catarrh of the human conjunctiva. The filtered cultures had less action. The toxin, therefore, mostly lies in the bacilli (the same is true for influenza bacilli—Kolle and Delius).

After an attack immunity only occurs to a limited extent. Morax and Petit, L. Müller, Usher, and Fraser have several times observed repeated attacks in the same individual within a short period of time. Weichselbaum and Müller inoculated an individual four weeks after recovery from a former inoculation conjunctivitis, and again got a positive result. In spite of this, we cannot exclude the possibility of some degree of immunity after an attack,[1] and, further, such a supposition most readily accounts for the subsidence of an epidemic. The continued presence of virulent organisms on a practically healthy conjunctiva for a long time after the inflammatory reaction has ceased also favours this view. L. Müller reported a case favouring the persistent presence of Koch-Weeks bacilli on the healthy conjunctiva after an inflammation had subsided, and several months of perfect health had ensued; no reinfection could have occurred in the case, and he considered it due to a relapse.

Müller also quotes that in himself an attenuated virus produced no conjunctivitis, but that it caused a conjunctivitis of only one day's duration in another individual.

That susceptibility varies is shown by the fact that a very slight

[1] For the related disease influenza such a condition is affirmed by many (Bäumler, Wassermann, Clemens, Parsons, etc.), although it cannot be produced in animals (Kolle and Doenitz).

conjunctivitis may be caused by infection from a very severe case, and *vice versa* (Morax, Morax and Petit, Weeks, Hofmann). Some of Morax and Petit's cases showed very slight clinical changes. It is, however, quite exceptional for virulent material of this kind to produce no conjunctivitis when inoculated on the conjunctiva.

In this connexion L. Müller's experience must be noted: a cicatricial conjunctiva often reacts less intensely to the Koch-Weeks bacillus.

Meyerhof has made the same statement to me in a letter. In winter he found the bacilli in cases with a clinically normal conjunctiva, and when the weather became warmer these developed a typical conjunctivitis. In trachomatous patients who at the moment had no conjunctival catarrh, the condition more often remained as it was.

Differential Diagnosis.

The recent identification by Pes of the Koch-Weeks bacillus with the diphtheria group, and particularly the *Bacillus xerosis*, requires no refutation, as for anyone acquainted with the two organisms a single glance at the peculiarities of the Koch-Weeks organism is sufficient to show that such an identification is quite erroneous. The peculiarity that the *Bacillus xerosis*, belonging to the diphtheria group, has a special predilection for growth in culture with the Koch-Weeks bacillus, is responsible for this mistake, as it was for the inability of the earlier investigators to obtain pure cultures. To-day the two forms can be separated with ease and certainty. In a smear preparation such a confusion is impossible, especially when Gram's stain is used.

Kruse ('Die Mikroorganismen,' — Flügge, 1896, ii. 441) reported that Kartulis had cultivated from the conjunctiva a bacillus of similar morphological characters, but of more profuse and yellow growth. This organism at first liquefied gelatine; later, however, on stab culture, gave the 'nail' growth. It also grew on potatoes. Kruse named it *Bacillus pseudo-conjunctivitidis*. In Kruse's *Hygien. Institut* Ibrahim and Fuad obtained cultures of two similar organisms from the air; these they named *Bacillus aëris minutissimus* and *Bacillus aureus minutissimus*. All three decolorized with Gram's stain.

These are quite isolated findings, which have never occurred in the enormous number of examinations which have been made of the secretions in Koch-Weeks conjunctivitis; they are, therefore, of no practical importance in differential diagnosis. Nor will the Koch-Weeks bacillus be confused with any other organism causing con-

junctivitis in man by anyone who has experience with it[1] (*re B. influenzæ, vide infra*).

Its appearance, combined with its reaction to Gram's stain, is quite characteristic, and Jundell is incorrect in warning against giving a diagnosis from the smear preparation. He did so because in several cases where such an appearance was presented no such Bacteria could be found in a blood-agar culture, *Bacillus xerosis* and cocci resembling *Pneumococci* alone growing. He was incorrect, because the use of Gram's stain would have absolutely excluded any confusion with these organisms in the smear. The literature also teaches us that the Koch-Weeks bacilli often fail to grow on media made from animals' blood. The smear preparation in these cases often gives more information than the cultures. The one and only organism with which there is a similarity is the influenza bacillus, and the morphologically and biologically similar L. Müller's bacillus.

What is the relation, then, of the Koch-Weeks bacillus to the influenza bacillus (Pfeiffer), and with the Müller's bacillus which is practically identical?

Is it identical with them, so that the conjunctivitis can be called 'influenza bacillus conjunctivitis,' as has been lately proposed by Jundell, Smitt, Rymowitsch, Giarré, and Picchi?

In reviewing this question we must first establish that in fact there is a conjunctivitis with an organism present which in every particular agrees with Pfeiffer's bacillus.

The Bacillus Influenzæ (Pfeiffer).

(Plate I., Fig. 2, *a-d.*)

Morphology and Culture.—Very small rods, slender, with rounded ends, without spore formation, almost like cocci, and shorter than the Koch-Weeks bacillus which more resembles the bacillus of mouse septicæmia; they lie singly or in pairs, often like *Diplococci*. They are Gram-negative, often show distinct polar staining, and are obligate aerobes, only growing at temperatures above 26° C., and with certainty on media containing blood, especially pigeon's, which is so rich in hæmoglobin. Exceptionally they grow on serum media (due to an admixture of hæmoglobin), and occasionally on hæmoglobin-free media, in symbiosis with other organisms which favour their growth (various *Staphylococci*, but especially the *B. xerosis*). Grassberger and Gohn by prolonged cultivation have been able to make some strains grow on the ordinary media.

In the discharge the bacilli tend to occur in clusters (*cf.* Fig. 18), like shoals of fish. In cultures longer rods occur.

[1] The glanders bacillus and the Ducrey bacillus of soft sore are also Gram-negative, but they are larger, and almost never occur in acute conjunctivitis. The *Bacillus pyocyaneus* is of no importance in conjunctival inflammations, although it is often observed in the cornea.

The cultures are very toxic for rabbits, and, according to Cantani, a certain egree of bactericidal immunity can be produced in them. This, however, is denied by others (Delius and Kolle).

FIG. 18.—CONJUNCTIVAL SECRETION FROM A CASE OF DACRYOCYSTITIS WITH INFLUENZA AND XEROSE BACILLI.

The variety described by Pfeiffer as the pseudo-influenza bacillus, which sometimes forms long coiled threads in cultures, is considered by most authors to be the influenza bacillus. Similarly, the Gram-negative 'polbacteria' found in whooping-cough,[1] measles, and other infectious diseases, are very closely related, if, indeed, they are not identical; as are the other Bacteria with the characteristics of the influenza bacilli, which are so widespread in the nasal mucous membrane, and occasionally occur as saprophytes on other mucous surfaces.

Presence in the Eye.—In the purulent secretion of trachoma L. Müller found bacilli, which he showed to resemble influenza bacilli. These bacilli occurred frequently, though not constantly, in trachoma, but Müller did not identify them with Pfeiffer's bacillus. The individuals affected showed no definite symptoms of influenza. There was no epidemiological relationship either to influenza. L. Müller definitely stated that his bacillus only grew with certainty on blood media, especially those derived from pigeon's blood, and that it was especially luxuriant in symbiosis with certain *Staphylococci*. He made a careful study of the Koch-Weeks bacillus, and rightly distinguished his bacillus, and also the influenza bacillus, from that organism; for the latter (Koch-Weeks) generally requires a serum medium, and does not grow upon pigeon's blood, though this is not constant (*vide infra* Luerssen); it is also more slender and longer.

FIG. 19.—MICROPHOTO OF A SECRETION PREPARATION BY RYMOWITSCH AND MATSEHINSKY. × 1,000.

'Influenza.'

L. Müller and Weichselbaum state that the Koch-Weeks colonies on serum agar are rather smaller than those of the influenza bacillus, and that their margins when under × 80 magnification appear slightly crinkled, in contrast to the smooth uniform influenza colonies (according to Luerssen this is not a constant difference).

[1] *Cf.* Jochmann, *Zeit. f. Hyg.*, 1903, xliv. 498; Auerbach, *Zeit. f. Hyg. u. Infekt.*, Bd. xlvii.; Klieneberger, *Deutsche Med. Woch.*, 1906, p. 1580.

Zur Nedden found the same results in a case of non-gonorrhœal blennorrhœa neonatorum and in other cases of acute conjunctivitis of variable intensity. In two cases the conjunctivitis was very slight. At first he named them pseudo-influenza bacilli, on account of their long and convoluted involution forms; but on account of the results which Grasberger subsequently announced, he altered their designation to influenza bacilli.[1] In these cases, and also in others which he has reported more recently, catarrhal influenzal symptoms were present in the air passages. Otitis media and blennorrhœa of the sac have also been observed (Saemisch). These occurred when an influenzal epidemic broke out in Bonn, ceased with it, and fresh cases occurred with a new epidemic. In thirteen cases, mostly of children, the conjunctiva alone was affected in only five. Zur Nedden therefore considers this conjunctivitis as serious. He has recorded a case of severe purulent keratitis with only influenza bacilli in the ulcer. He almost invariably found the influenza bacillus in pure culture, only occasionally was it mixed with *Pneumococci* and *Streptococci*. Zur Nedden rightly emphasizes that, as distinguished from the Koch-Weeks bacilli, the influenza bacilli are neither so slender nor so long, and that hæmoglobin is essential for them. He agrees with L. Müller regarding their free growth on pigeon's blood, which does not as a rule occur with Koch-Weeks bacilli (Luerssen records some exceptional cases). According to him, the influenza colonies on blood-agar retain their homogeneous condition and their hemispherical prominence, while the colonies of the Koch-Weeks bacilli, which are much more difficult to cultivate, soon become indistinguishable on the surface of the medium.[2] Bacilli with the appearance of Koch-Weeks bacilli have never yet been found in the bronchial secretions.

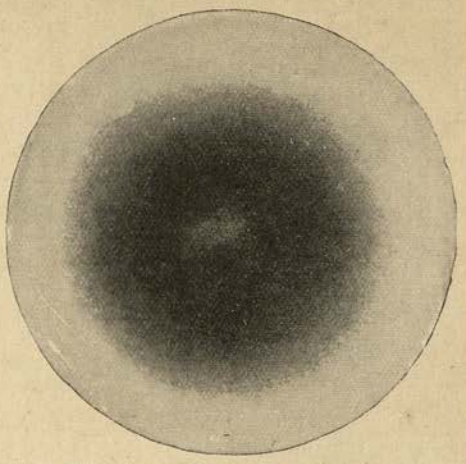

FIG. 20.—SHAKE PREPARATION (RYMOWITSCH OF A TWENTY-FOUR HOUR HÆMOGLOBIN AGAR CULTURE. × 270.

'Influenza.'

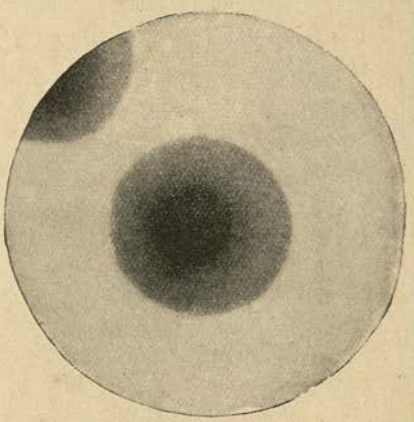

FIG. 21.—THE SAME CULTURE AS FIG. 20. × 90.

'Influenza.'

[1] Quite recently Luerssen has issued a paper from Pfeiffer's Institute in which he distinguishes between influenza and pseudo-influenza bacilli. The difference, however, is limited to morphological peculiarities of definite cultures.

[2] Luerssen brings forward another differentiating characteristic—the Koch-Weeks bacillus is agglutinated by certain normal sera, while the strains of influenza and Müller's bacillus which he examined were not. The Koch-Weeks bacillus, too, will not diffuse into normal saline solution unless first rubbed up in distilled water.

Zur Nedden therefore puts aside Jundell's identification, and, after examining and comparing many examples, I thoroughly agree with him in doing so. I must also insist that Koch-Weeks and influenza bacilli can with certainty be differentiated in secretions by their appearance. Zur Nedden considers that experience of both organisms justifies such a diagnosis. Regarding this point, it is worthy of note that Morax, who is both a highly skilled expert on Koch-Weeks bacilli, and has also often examined cases of influenzal conjunctivitis, opposes the identity of these two organisms on the same grounds as does Zur Nedden. He also states that he often found the Koch-Weeks bacillus in Egypt, but never L. Müller's bacillus. On the other hand, Meyerhof found Müller's (*i.e.*, the influenza) bacillus frequently on non-trachomatous conjunctivæ in Egypt, and considered it to be a harmless parasite. A. Knapp holds the same view.

Difficulties arise when both occur mixed together; it is then quite possible that only the more tractable influenza bacilli will grow on a blood medium, and thus the idea of their identity would be confirmed (Plate I., Fig. *II.*, *a* and *c*). In cultures the differentiation is more difficult, as many strains of influenza grow in a somewhat longer form. Luerssen also notes these occasional difficulties.

In the discharges of forty trachoma cases A. Knapp found these bacilli four times, and in the contents of the follicles of eighty cases also four times. He also found the same organism (the influenza bacillus) in a very severe case of pseudo-membranous conjunctivitis in a newly-born infant, in which one cornea was destroyed.[1] All these bacilli were obligate Hæmophiles (Hæmoglobinophiles) and otherwise typical in morphology and in culture peculiarities. Brown-Pusey has often found them in acute conjunctivitis.

Jundell appears only to have examined cases in which the conjunctiva became affected during typical febrile influenza. In young people thus affected he found many cases of conjunctivitis of varying severity, with large numbers of typical influenza bacilli. He did not consider growth on serum a distinctive feature of the Koch-Weeks bacillus, for the same might occur with the influenza bacillus, though far less freely than when ascites and the like were used. Zur Nedden opposes this, and states that it might quite well be the trace of hæmoglobin occurring in many human sera which makes such media occasionally able to grow the influenza bacillus; and, *vice versa*, when the Koch-Weeks bacillus has grown on blood, it has been on human blood whose proportion of serum had rendered the growth possible.

Rymowitsch reported that certain bacilli (see Fig. 19, p. 150) which he termed Koch-Weeks bacilli were identical with influenza bacilli in every respect, even with regard to animal inoculation (toxicity in large doses). The bacilli were, however, actually the true influenza organisms. Smitt, Giarré, and Picchi express the same opinion. Morax, Demaria, and M. Neisser recently described influenza conjunctivitis. These authors, as also A. Mayer, Klieneberger, and Tedesco, found influenza bacilli in the conjunctival secretions of patients with measles, though not as a constant condition.

During 1896 in a small house epidemic of mild follicular conjunctivitis, which completely subsided spontaneously, I demonstrated and cultivated influenza bacilli (Plate I., Fig. *II.*, *b*).

The more carefully I have examined for them since, and the more exact the methods used, the more frequently have I met with them. In my experience they are fairly frequent in the lacrymal sac, though

[1] Doetsch had already found the influenza bacillus three times in purulent keratitis in adults; this finding has been lately repeated in one case by Zur Nedden. It is rare.

rarely indeed in such large numbers as are shown in Fig. 18, which is drawn from a secretion specimen. Such cases of dacryocystitis have nothing to do with trachoma, as Müller alleged; the frequency of the bacilli in the sac makes this obvious. After the work of Rymowitsch and Giarré, we have no doubt that individual organisms are by no means rare on the healthy conjunctiva. These last writers state that they found the '*Bacillo hæmofilo*' in 5·8 per cent. of healthy conjunctivæ, in 90 per cent. of acute epidemic catarrhal conjunctivitis (Koch-Weeks is here taken along with the influenza bacillus), in 83 per cent. of cases of measles (in such Morax met them once and Meyer often), in 66 per cent. of cases of influenza, and in a trachoma they never found them—a striking contrast to the results of others.[1]

The foregoing facts regarding the Koch-Weeks bacillus show generally that this organism does not need to rely on the presence of hæmoglobin for its growth to the same extent as does Pfeiffer's bacillus (*vide supra*).

While Pfeiffer's influenza bacillus has a definite pathogenicity for animals, especially apes, rabbits, and guinea-pigs (peritoneum!), in which it produces a toxic disease, generally without any multiplication of the bacilli,[2] inoculation of animals with Koch-Weeks bacillus has always given a negative result. Rymowitsch alone attributes to the bacillus which he found the same toxic characters as the influenza bacillus. Rymowitsch's bacillus was simply not the Koch-Weeks organism. His own photographs, which are here given (Fig. 19) show influenza bacilli. It appears to me desirable that further experiment should be made with the Koch-Weeks bacillus on animals, as the inoculation of large doses appears never yet to have been made. On account of the failure of all efforts to produce in animals an immunity to the influenza bacillus, no tests relying on specific immunity can be employed to identify these organisms.

Clinically, too, a complete identification of the Koch-Weeks with the influenza bacillus would be quite opposed to the fact that when the Koch-Weeks organism has produced its inflammation, especially in widespread epidemics, no disturbances of the general health have occurred which could at all be considered as symptoms of influenza (we except a slight discomfort and cold in the head at the height of the attack). The conjunctival attacks, too, do not occur parallel with

[1] Note that Siegrist found influenza bacilli in an orbital abscess. Duclos found them with *Pneumococci* in the pus from a post-operative panophthalmitis; I once found the same, and also obtained them once in the orbital pus from a frontal sinus. Morax obtained influenza bacilli from an infected conjunctival cyst; Von Krüdener in purulent dacryoadenitis; Panja, Dianoux, and Casali in metastatic influenzal ophthalmitis.

[2] See Kolle and Delius, *Zeit. f. Hyg. u. Infekt.*, Bd. xxiv.

the spread of influenza. The records by Koch, Kartulis, Weeks, and also Jundell, date from before the last pandemic, and have just as little to do with influenza as have the later records. On the other hand, it must be admitted that Müller found his bacillus, which we cannot differentiate from the influenza bacillus, without any other signs of influenza present. Zur Nedden, A. Knapp, and Luerssen saw a few similar cases, as also have I. If we identify L. Müller's bacillus with the influenza bacillus, it must be admitted that an exclusive affection of the conjunctiva by Pfeiffer's bacillus can occur without the association of the usual influenzal symptoms. In most cases of this form of conjunctivitis, however, the usual symptoms of influenza are well marked.

That on some occasions local conjunctival symptoms should be specially prominent, and that on others general influenzal symptoms should be most important, is not without analogy. The same is noticed in other conditions. An infection of the conjunctiva, with its limited superficial extent, has less disturbing influence on the general health than an infection localized in the respiratory tract. Such is the case in diphtheria, and especially so in pneumococcal conjunctivitis, where general symptoms are only exceptionally present. This latter example is a proof that specific localized affections of the conjunctiva can dispense with the general manifestations of the organismal irritant usually observed. Pneumococcal conjunctivitis associated with pneumonia is extremely rare.

It would be of great interest, with regard to the action of Pfeiffer's influenza bacillus, if a positive inoculation of the human conjunctiva with a pure culture obtained from a bronchial secretion could be compared with an inoculation of the Koch-Weeks bacillus (*vide* p. 147 *et seq.*). Such an experiment, however, can hardly be recommended.

Luerssen, working with Kuhnt, has lately inoculated Müller's bacillus (*i.e.*, influenza) three times on the human conjunctiva. He calls the results negative. The resulting conjunctival irritation and discharge were certainly extremely slight, though on one occasion the conjunctiva was inoculated on three successive days, and two days after the last inoculation the bacilli could be demonstrated in the conjunctiva and in the nose (and that without any influenza !). This is a very different result from inoculation with Koch-Weeks bacillus. I can give an instance bearing on the question. While attempting to syringe a case of muco-purulent dacryocystitis, pus from the sac, containing enormous numbers of influenza bacilli, squirted into my own eye. Although the eye was not cleansed, as I did not wish to

interrupt the operation (extirpation), I suffered from no subsequent trouble.

We must therefore conclude that these bacilli are, at any rate, far less contagious than the Koch-Weeks bacilli.

L. Müller declared that no causal significance had been proved for the influenza bacillus on the conjunctiva. This is so far correct, as no positive proof by inoculation is available; none the less, I consider it extremely probable that influenza bacilli can occasionally produce a conjunctivitis. These organisms are obviously adapted to a saprophytic growth, but under circumstances not yet understood they may produce an inflammatory reaction.

LITERATURE[1]

OF THE KOCH-WEEKS AND PFEIFFER'S (INFLUENZA) BACILLI (L. MÜLLER'S BACILLUS).

AUGÉ, R., Affect. contag. dans une consultation ophth. Thèse de Paris, 1906.

AXENFELD, 'Ergebnisse,' von LUBARSCH-OSTERTAG, Bakteriologie des Auges, 1895-99.

BIETTI, K. M. f. A., 1903, Beilageheft. Festschr. f. Manz.

BREWERTON, Lancet, 1903, p. 1036.

BROWN-PUSEY, Chicago ophth. Soc., 1906 (*cf.* K. M. f. A., September, 1906, Bd. II.).

BUTLER, Bact. of acute conj. in the East. R. L. O. H. Reports, 1907, XVII, p. 175.

COPPEZ, Arch. d'ophth., 1899, t. 19, p. 11.

CASALI, Ann. di Ottalm., 1907, XXXVI, S. 128.

DEMARIA, Conj. por Influenza. Rev. de la Univ. de Buenos Ayres, 1906, II.

DUANE and HASTINGS, Bacter. types of acute conjunctivitis. Journ. of Amer. Med. Assoc. (Boston), 1906.

ELMASSIAN, Ann. d'oculist., 1900.

EVANS, Bacterial diseases of the conjunctiva. The Ophthalmoscope, April, 1904.

FAGE, La Clinique ophthalmol., 1900, p. 5.

FERGUS, B. M. J., 1905, p. 523.

GASPARRINI, Batteriologia delle congiuntiviti acute. Annali d'ottalmologia, 1895, supplement.—*Ibid.*, Annali d'ottalm., vol. 25, 1896.

GIARRÉ and PICCHI, Lo Sperimentale, 1903, Fasc. 5 (Ricerche batt. nelle congiuntivite catarrale acute, nell morbillo e nell' influenza). Ref. C. Bl. f. B., 1905, XXXVII, p. 239.

GIFFORD, Arch. of ophth., 1898, XXVII, and Ophth. Record, 1905, XIV, p. 51.

GONIN, Revue médicale de la Suisse Romande, February and March, 1899.

GRASSBERGER, Zeitschr. f. Hyg. u. Inf., 1897, Bd. 25.—*Ibid.*, Zentralbl. f. Bakt., 1898, Bd. 28, S. 353.

GROMAKOWSKI, A. f. A., 1900, Bd. 41, S. 197.

DE HAAN (Batavia), Janus, December, 1905, V.

HARMAN, BISHOP, The conjunctiva in health and disease, 1905 (quoted by Pollock)

HOFMANN, Zeitschr. f. Hyg. u. Inf., 1900, Bd. 33, S. 109.

JULER, B. M. J., September 15, 1894.

[1] *Cf.* papers quoted on p. 118.

JUNDELL, Influenzaconjunctivitis bei Säuglingen. Mitteilungen aus der Augenklinik des Karolinischen med. chirurg. Instituts in Stockholm (Widmark) (bei Fischer, Jena), 1902, Bd. 3, S. 11.

KAMEN, Zentralbl. f. Bakt., 1899, Bd. 25, S. 401.

KARTULIS, Zentralbl. f. Bakt., 1883, Bd. 1.

KLIENEBERGER, C., Über hämophile Bazillen. Deutsche med. Woch., 1905, Nr. 15.

KNAPP, A., A bacteriological study of trachoma, with remarks on the occurrence of the influenza group of bacteria in conjunctivitis. Archives of ophthalmol., 1904, XXXIII, Nr. 5; also *ibid.*, Nr. 4.

KOCH, R., Arbeiten aus dem Kaiserlichen Gesundheitsamt, Bd. 3, S. 19.

KOLLE und DELIUS, Zeitschr. f. Hyg. u. Inf., Bd. 24.

KRUSE, *cf.* FLÜGGE, Die Mikroorganismen, 1896, Bd. 2, S. 441.

LAKAH and KHOURI, Annales d'ocul., 1902, t. 128, p. 420.

LUERSSEN, A., Bakteriologische Untersuchungen bei Trachom. Zentralbl. f. Bakt., XXXIX, Orig., S. 678.

MARKUS, Münch. med. Woch., 1901, S. 2137; Ann. d'ocul., November, 1906, CXXXVI.

MEYERHOF, K. M. f. A., 1905, XLIII, II, S. 225.

MCDILL and BERRY (Manila), B. M. J., 1904, 2260.

MCKEE, Montreal Med. Jour., February, 1907.

MORAX, Sur l'étiologie des Conjonctivites aiguës. Thèse de Paris, 1894.—Annales d'ocul., 1903, t. 129, p. 156.

MORAX and BEACH, A. f. A., Bd. 33, 1896.

MORAX and ELMASSIAN, Ann. d'ocul., 1899, t. 121. Verhandl. des internat. ophth. Kongresses Utrecht, 1899, S. 465.—Ann. de l'inst. Pasteur, 1898, p. 210.

MORAX and PETIT, Ann. d'oculist., 1898, t. 120, p. 161.

MORAX, Maladies de la conjonctive. Encyclopédie franç. d'ophth., 1905; also Kyste infecté de la conj. bulb. Soc. d'opht. de Paris, November 6, 1906 (K. M. f. A., January, 1907, I).

MÜLLER, L., A. f. A., 1900, Bd. 40, S. 13.

ZUR NEDDEN, K. M. f. A., January, 1900.—*Ibid.*, K. M. f. A., Bd. 38, S. 173.—*Ibid.*, Über Influenzabazillenconjunctivitis, K. M. f. A., March, 1903, Bd. 41.—*Ibid.*, Über einige seltene Infektionskrankheiten der Hornhaut, K. M. f. A., June, 1906, I.—*Ibid.*, Über den MÜLLERschen Trachombacillus und die Influenzabazillenconjunctivitis, K. M. f. A., 1904, XLII, Bd. I, S. 47.

NEISSER, M., Über die Symbiose des Influenzabacillus. D. med. Woch., 1903, Nr. 26.

POLLOCK, T. O. S., 1905, XXV.

RANDOLPH, Journ. of the Amer. Med. Ass., 1903, p. 821.

RYMOWITSCH, Wratsch., 1900 and 1901, t. 20, p. 638.

SANTOS-FERNANDEZ, Arch. de oft. hispano-amer., 1904, S. 141.

SAEMISCH, Krankheiten der Bindehaut, 1905, 2nd edition of Handbook.

DE SCHWEINITZ, Ophth. Record, 1899, pp. 80, 87.

SHUMWAY, Journal of Amer. med. Assoc. (Boston), 1906.

SMITT, Tijdschrift v. Geneeskunde, 1900, Nr. 26. Rev. Michel-Nagel.

SMITH, Yale Med. Journ., May, 1904 (rev. Duane), and Archives of ophth., 1905, XXXIV, p. 481.

STEPHENSON-SIDNEY, Zentralbl. f. A., 1896, S. 729.

SUBOW, Wratsch, 1896, XVII, S. 479 *ff* (rev. Saemisch).

TEDESCO, Centr. f. Bakt., Orig., 1907, XLIII, S. 444.

TERLINCK, Ulcère à hypopyon à bacilles de WEEKS. La clinique, 1905, Nr. 45.

TERRY and CASTELLANI (Ceylon), Jour. of Tropical Med., 1906, IX (rev. Rev. générale d'oph., 1907, p. 112).

USHER, C. H., and FRASER, U., R. L. O. H. Reports, 1904, p. 444.
VEASY (Philadelphia), Ophth. Review, 1899, S. 354.—*Ibid.*, Archives of ophthalmology, 1900, vol. 28, 3-5.
WEEKS, Arch. f. Augen., 1887, Bd. 17, S. 318.—*Ibid.*, New York eye and ear infirmary Report, 1895.
WEICHSELBAUM and MÜLLER, A. f. O., 1899, Bd. 47, S. 108.
WILBRAND, SAENGER, STAEHLIN, Jahrb. d. Hamburger Staatskrankenanstalten, 1894.
WIBO, Presse méd. Belge, May, 1905.
WYNEKOOP, A further study of the Influenza Bacillus. (Amer. med. Assoc., 53.) Jour. Amer. med. Assoc., February 28, 1903. Rev. Zentralbl. f. Bakt., 1904, XXXIV, S. 376.

SECTION 2.—DIPLOBACILLARY CONJUNCTIVITIS (MORAX, AXENFELD).

Petit's Variety of the Diplobacillus.

Cf. PLATE I., FIGS. *III.* AND *VI.*; PLATE III., FIG. *II.*

Historical.

We have to thank Morax for the discovery of this peculiar infectious disease, which, so far as our knowledge goes, though very frequent, is exclusively an affection of the human conjunctiva. In July, 1896, he published a short paper, in which he recorded all the essential points in the exact description of the clinical features and organismal cause of a disease which he termed 'conjonctivite subaiguë.' He there definitely stated that the inoculation of pure cultures on the human conjunctiva produced the typical disease, but the bacillus was in no way pathogenic for animals.

Immediately thereafter, at the Heidelberg Ophthalmological Conference (August, 1896), Axenfeld demonstrated preparations of the same bacillus, which he had independently grown on Löffler's blood-serum in Marburg. In a more detailed account he corroborated Morax's findings in every particular, and elaborated the clinical appearances in this and a later communication from a material consisting of fifty-one cases. On account of its pre-eminently chronic character, he proposed the name 'chronic diplobacillary conjunctivitis.' Axenfeld recorded positive inoculations of the human conjunctiva.

Following on these publications came confirmatory statements from all sides, showing that the disease is spread over the world in extraordinary profusion, to such an extent that I consider it to be the most widespread infectious disease which exists, and showing also that a characteristic clinical appearance is presented by the majority of cases.

Peters reported many cases in Bonn. Gifford (Omaha, Nebraska)

had previously obtained the bacillus in pure culture on agar. Peters repeated this, but provisionally hesitated to accept the pathogenic function attributed to it by Morax and Axenfeld, because he found the organism without any marked irritation being present. He soon, however, became convinced on this point, and emphasized its special prevalence in the Rhine Valley. A large number of further communications followed; these will be noticed more particularly under the heading 'Epidemiology.'

It is strange that this condition, perhaps the most common of conjunctival affections, and one of great importance, especially for the cornea, should have been discovered comparatively so late. The explanation lies in the fact that up till then bacteriological interest had been applied almost exclusively to the acute forms; and, further, because cultivation of the *Diplobacilli* is generally only successful on blood media.

Geographical Distribution and Epidemiology.

Diplobacillary conjunctivitis has already been demonstrated:

In America: Cuba (Santos-Fernandez); Philadelphia (Sweet, de Schweinitz, Veasy, and Clothier); St. Louis (Alt); Omaha (Gifford); Chicago (Brown-Pusey); Boston (G. S. Derby,[1] jun.); Montreal (Tooke, McKee); New York (Duane, Hastings); Milwaukee (Black); Illinois (Brown-Pusey); and probably in other parts (Smith, Brewerton, Randolph).

In Paraguay (Elmassian).

In Africa: Egypt (L. Müller, Morax, Lakah, and Khouri, Meyerhof).

In Europe: Glasgow (Pollock); Aberdeen (Usher and Fraser); London (Eyre, MacNab, Parsons); Copenhagen (Lundsgaard); Berne (O. Simon, Pflüger); Lausanne (Gonin); Paris (Morax and Petit); Toulouse (Mallet); Clermont-Ferrand (Biard); Padua (Bietti); Naples (De Lietro-Vollaro); Turin (Pes); Parma (Corsini); Breslau, Rostock, Marburg, Freiburg (Axenfeld and Bietti); Westphalia (Schmidt); Bonn (Peters, Zur Nedden, Saemisch); Kiel (Christensen); Greifswald (Hoffmann); Würzburg (Bach and Neumann); Nüremberg (Alexander); Vienna (L. Müller); Buda-Pesth (v. Grosz, Scholtz, and Vermes); Kasan (Rymowitsch); Holland (Nicolai, Rochat, Schoute).

In Asia: Java (Haan); Japan (Hotta); Palestine (Butler).

In Egypt (Müller, Lakah and Khouri, Meyerhof).

[1] Personal communication.

Many surgeons who have studied this subject in my clinic have told me that they have found the *Diplobacillus* very frequently in their own practices.

It is therefore quite certain that the Morax *Diplobacillus* is very widespread over the globe. This can readily be understood when we consider the extraordinary contagiousness, as shown by inoculation (Morax, Axenfeld, Hoffmann, Gifford, Erdmann), and the chronicity of diplobacillary conjunctivitis; the more so as, according to the findings of Erdmann and Biard, it can persist for a long time in the nose. Plaut and von Zelewski have proved in my laboratory that it can occasionally be found there without any inflammation of the conjunctiva being perceptible; Rymowitsch and Erdmann have found it here and there in normal persons.

We must not, however, speak of an even distribution of this disease. Junius definitely asserts that up till 1900 he had never met it in Königsberg. Statements vary regarding Egypt. L. Müller found it comparatively seldom; Lakah and Khouri have bacteriologically examined 966 cases of conjunctivitis there, and found the *Diplobacillus* only fifteen times, contrasted with the Koch-Weeks bacillus 523 times, and *Gonococcus* 257 times. Meyerhof, on the contrary, found it much more frequently—in about 50 per cent. of trachoma cases. The *Diplobacillus* is freely associated with trachoma (Peters, Hoffmann).

How exceedingly frequent diplobacillary conjunctivitis can be in other places is seen by the fact that Eyre found it in about 2½ per cent. of all the cases in Brailey's clinic. During six months in 351 consecutive cases of conjunctivitis Gonin (Lausanne) found the diplobacillary infection no less than 180 times. According to Pflüger and Simon, it forms about 10 per cent. of all the patients in Berne. It is just as common in Rostock (Erdmann had 342 cases in five years), Freiburg (we had 529 cases in four years), and Greifswald; in the University Eye Clinic in Bonn over 500 cases were observed in one year. Acute epidemics of moderate dimensions have also been observed in these towns, though the infection has but slight tendency to be epidemic. It occurs more in an endemic and comparatively uniform manner, especially within the limits of families and in sporadic cases. Stoewer and Erdmann are of the opinion that diplobacillary infection of the cornea has recently become more frequent in their district. That is quite possible. In many places, however, where this infection has not been recognized it is found to be frequent when more carefully looked for. I have often heard surgeons say that diplobacillary infections did not occur with them, although

numerous cases could be shown them in the hospitals of their immediate neighbourhood; they had simply overlooked the very plentiful slight cases.

People of every age are affected, even new-born babies (Andrad, Callomb)—adults most commonly. In negroes Brown-Pusey observed severe acute conjunctivitis, almost like a blennorrhœa. No special personal disposition has been observed. A seasonal variation has so far been observed in that it is more plentiful during the hot and dusty seasons of the year (Gonin). This can be seen in my own material. Infection occurs by direct or indirect transference of the secretion. According to Biard and Erdmann, the nasal mucus of apparently healthy people can contain the bacilli and act as a means of infection.

Clinical Appearances.

Morax gave the affection the name of 'conjonctivite subaiguë.' At first I called it 'chronic diplobacillary conjunctivitis,' as the untreated disease appeared to last for years. When later I observed acute cases, the name 'diplobacillary conjunctivitis' seemed generally more preferable. Since then the name 'diplobacillary conjunctivitis' of Morax or of Morax-Axenfeld has generally been used.

As in the case of the other infectious forms of conjunctivitis, so here: it is generally agreed that there is a marked tendency towards a characteristic clinical appearance—a blepharo-conjunctivitis.

Putting aside the rare cases of acute onset,[1] diplobacillary conjunctivitis commences with a slight catarrh, and almost always affects both eyes, though not necessarily at the same time; the second eye is often less severely affected. During the night especially a moderately profuse greyish-yellow and rather sticky secretion collects, mostly at the inner canthus. The lid margins become red, very obviously so at the angles, especially the inner. This redness of the inner angle, in comparison to the mild character of the conjunctival changes, often appears very marked; in cases with a profuse secretion it takes the form of a large round patch surrounding the caruncle. The reddened skin is as a rule moist, slightly macerated, and often covered with a white scum like an intertrigo. According to the old symptomatic classification this was called by many 'ophthalmia angularis.'

The mucous membrane of the lids generally shows a very slight swelling, with a hyperæmia chiefly affecting the parts adjacent to the lid margins and the fornix; the bulbar portion appears less affected; the superficial vessels are slightly injected in the region of the canthi. Phlyctenules are rare, and only occur when scrofulous persons are affected, especially children. For such scrofulous subjects treatment by zinc is often especially valuable, preventing recurrences which otherwise defy treatment. Corneal complications first develop in the form of small superficial marginal infiltrates of the so-called 'catarrhal' type. Morax, Biard, and Peters observed single cases, and Petit studied them more fully. He often found the *Diplobacillus* in the

[1] *Cf.* Tooke, Brown-Pusey, Duane, Pollock, Zur Nedden, McKee.

infiltrations, and emphasized the important clinical fact that the original conjunctival inflammation was often but slight and easily overlooked, but that the corneal condition also healed rapidly with zinc. Hoffmann, Zur Nedden, McKee, and Pflüger corroborate this fully. The latter always found a mixed infection with *Pneumococci* when an ulcus serpens occurred in a diplobacillary conjunctivitis.

This, however, is not always corroborated. Gifford described a severe ulcerative keratitis, and Uhthoff and Axenfeld found the *Diplobacilli* in a hypopyon-keratitis which greatly resembled an ulcus serpens. Further cases are described by Paul, Erdmann, Stoewer, Schmidt, McKee, and Doetsch. When we include the Petit type of the *Diplobacillus*—and that can be done with slight reserve—the number of such cases is not small. In the course of years I have seen more than twenty cases of hypopyon-keratitis with *Diplobacilli* both of the Petit and the Morax-Axenfeld type. The latter form is capable of causing a hypopyon-keratitis (*cf.* papers by Paul, McKee, and Erdmann). It is important to note that this severe form also can be cured by the use of zinc sulphate. Further particulars are given in the chapter on 'Corneal Bacteriology.' The conjunctival signs in such cases may be quite obscured.

The clinical appearance of a blepharo-conjunctivitis should immediately arouse suspicion that the *Diplobacillus* is present.

It would be going too far, however, to give a positive diagnosis off-hand, for in such cases other findings occur or the examination may be quite negative. Examination of a slide or a culture alone will give a certain diagnosis. This marked affection of the angles may be absent in a case of diplobacillary conjunctivitis; and acute catarrhal cases from this cause have been described by Axenfeld, Hoffmann, Zur Nedden, Pflüger, Pollock, Usher, Fraser, and Brown-Pusey. Not infrequently the objective signs of inflammation are so slight that they may readily be overlooked, and patients, on account of a burning sensation in their eyes by artificial light, may be treated for asthenopia by means of glasses, etc., without result, although a course of zinc would rapidly remove all their trouble. The slightest secretion at the angles should be examined. In the very slightest 'almost normal' cases the bacilli are often very numerous. Lundsgaard states that occasionally only slight lacrymation may occur.

After a severe catarrh has occurred for a long time, ectropion districhiasis and eczema of the lids may result. Such cases are often wrongly considered as the ordinary blepharitis.

In all cases, therefore, of blepharitis the secretion should be examined for *Diplobacilli*, as their demonstration is an indication for the usual routine zinc treatment. MacNab has very rightly emphasized this recently. Follicles are occasionally observed in the conjunctiva. When they are very plentiful and resist treatment, they are usually not due to the diplobacillary infection, but to a combination such as is not uncommon in the case of true trachoma.

The affection when untreated lasts, with occasional exacerbations, for a long time. It is not known whether the rarer acute cases resolve more rapidly, as all the cases observed so far have been cut short by treatment. We have no definite records of cases healing spontaneously. What the patients call healing is often only a transient improvement.

The conjunctivitis is sometimes accompanied by a nasal catarrh. In a family which suffered from a very free conjunctival discharge I found at the nasal orifice reddened and macerated areas, on which *Diplobacilli* occurred; in another patient the same condition occurred at the angles of the mouth (Lobanow). Whether, in such cases, we should speak of a diplobacillary rhinitis or stomatitis is still open to question. Meyerhof states that catarrh of the upper air passages often occurs in people who have diplobacillary conjunctivitis. I have not found it so myself.

Biard's statement that the *Diplobacillus* very often occurred in the nose, and from thence infected the conjunctiva, was not at first confirmed (Morax, Petit, Zur Nedden). The fuller researches of Erdmann have shown that the bacillus can be very often found in the nose, not only in persons who have a blepharo-conjunctivitis, but also in those whose conjunctiva is healthy. Seeing that the cultural and other characteristics of the bacillus obtained from the nose are identical with those of the organism from the conjunctiva, and inoculation on the human conjunctiva produces the same conjunctivitis, Erdmann's results cannot be doubted. In the nose he found typical *Diplobacilli* without capsules 64 times in 142 persons whose conjunctival secretion contained no *Diplobacilli*. In 26 of these cases cultures were made, and 18 of them showed the typical Morax-Axenfeld *Diplobacillus*. The fact established by Erdmann that, after a diplobacillary conjunctivitis has healed, the bacilli may be found for weeks in the nose is important regarding the question whether these organisms can have a pathogenic action in the nose, and there multiply and persist. Only a few of Erdmann's cases had a chronic rhinitis ; the majority had a healthy nasal mucous membrane. Erdmann introduced some of the secretion from one of these clinically healthy membranes—where the conjunctiva, too, was free from *Diplobacilli*—into the normal conjunctiva, and produced a typical conjunctivitis. Cultures showed also that in the dried nasal secretion the *Diplobacilli* were still living after seven days.

It is worthy of note that Treacher Collins found the *Diplobacillus* 125 times in the nasal secretions of 300 school-children who had a nasal discharge as well as a conjunctivitis. He considered that the eyes were often infected from the nose, and recommended that the nose should be examined and treated in school epidemics.

Many cases of diplobacillary conjunctivitis must result from infection with the nasal secretion, and the suggestion of Gifford and Collins that the nose should be treated is quite rational.

The subjective symptoms are comparatively slight, even in the acute cases. Peters states that headaches sometimes accompany this infection, and cease when the conjunctivitis is relieved.

The Secretion.

In slight cases the amount of secretion is so small that no actual flakes can be found ; in such cases a greyish slime occurs on the caruncle. Although this angular secretion is very freely contaminated with skin saprophytes, and should not be used for cultures, it gives the slide diagnosis with special clearness, because the *Diplobacilli* occur in it in great numbers, sometimes in enormous profusion.

They either appear free or else attached to cells, especially epithelial cells, which are numerous in such a secretion, and may appear absolutely covered with the organisms. A true phagocytosis is rarer in these cases than in Koch-Weeks or pneumococcal conjunctivitis. The secretion, in fact, consists more of fibrin, and is poor in leucocytes.

The bacilli mostly lie in pairs, but longer or shorter chains occur, the bacilli being then plumper and arranged in coils, though a tendency for each adjacent pair to lie closer together can be noted.

The individuals are, on an average, 2 to 3 μ long and 1 to 1·5 μ broad. The size varies, and much smaller ones are seen; these are probably younger. Larger forms also occur.

The bacilli are rounded off at their ends, like a truncated oblong; they are generally of even thickness. Sometimes the ends appear a little swollen, and then a slightly deeper staining occurs there; but polar staining is not general. The whole organism takes on the stain very intensely. The line of separation between the pairs is quite clear.

Decolorization by Gram is rapid and complete. Concerning the presence of a capsule, opinions vary. Morax calls the organism capsule-free; Axenfeld said that the capsule was not clearly seen. On the contrary, Birnbacher and Gifford state that the capsule is quite obvious; Hoffmann and Zur Nedden hold the same view.

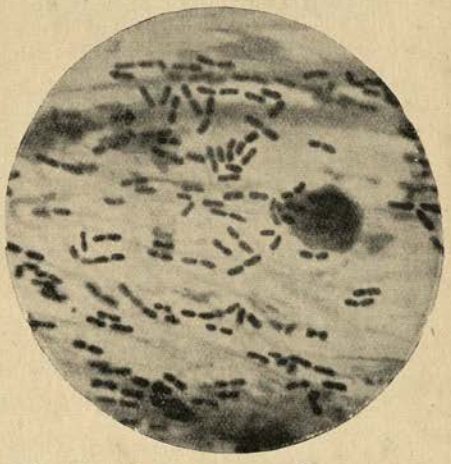

Fig. 22.—Diplobacillary Conjunctivitis Secretion (Rymowitsch and Matschinsky). × 1,000.

Capsule staining in my laboratory by Bietti and Agricola showed the presence of a narrow ectoplasm. Such methods show capsules on very many bacilli—*e.g.*, even on anthrax. In a secretion preparation we can say that the majority of the *Diplobacilli*, without special staining and with a wide aperture, show no definite capsule. This is especially the case with preparations stained by Gram's method, and counter-stained with safranin, such as are shown in Plate I., Fig. *III.*, exactly drawn from Nature. In these respects the *Diplococci* differ greatly from Friedländer's *Pneumobacillus* and the ozæna bacillus, which might otherwise be confused; and it is therefore correct to consider the capsule in the *Diplobacilli* unimportant. For other points refer to the remarks in Chapter I. on capsule staining.

Cultures.

The *Diplobacilli* of the Morax-Axenfeld type only grow at brood temperature, and then with certainty only on blood-serum, agar containing serum, or media which contain human body fluids.

On bullock's or sheep's *blood-serum*, prepared in *Löffler's* method, an unevenness of the surface develops in twenty-four hours, and takes the form of small, moist, slightly sunken, transparent areas, which slowly deepen, so that the medium is gradually liquefied, mostly without any change in its colour. With some strains the fluid material becomes brown. This has something to do with the serum, as in cooked serum it occurs much more rarely. If the milky and slightly viscous fluid mass be removed with a loop, the surface of the serum appears gouged out. When the colonies are widely separated, deep pits are formed, but when close together, they coalesce on the surface, and their viscous contents flow down into the condensed water; the peculiarly excavated surface is then very obvious. In about fourteen days almost the whole of the medium is liquefied down to the depths of the tube. The liquefaction, as a rule, is not complete, as the *Diplobacilli* die out, and generally hardly anything but involution forms is found in the liquefied mass. In cooked serum the liquefaction is neither so intense nor so rapid as it is in serum prepared by fractional sterilization.

This action is extremely characteristic of the *Diplobacillus*. Of all the pathogenic bacteria which are commonly found on the conjunctiva only the allied Petit type of *Diplobacillus* possesses this power. It should be noticed, by the way, that many sterile secretions have a certain power of dissolving or liquefying serum media. Every hollow on the surface of Löffler's serum should not, therefore, immediately be considered as a colony of *Diplobacilli;* a round excavation becoming progressively deeper, however, certainly indicates Bacteria. We must also remember that serum which has been imperfectly sterilized may contain the spores of liquefying organisms which may develop in the incubator.

On *serum agar* the *Diplobacillus* grows in the form of small, translucent, flat pale grey drops, resembling colonies of *Pneumococci*. Under higher magnification the colonies appear to be finely granulated, round in shape, with an even, slightly prominent margin, and show very little tendency to coalesce ; individually they are smaller than when grown on Löffler's blood-serum.

In *serum bouillon* a faint but quite marked cloudiness occurs in twenty-four to forty-eight hours ; a slight deposit sinks to the bottom, and can easily be shaken up.

On *agar*, free from serum, the *Diplobacilli* from the conjunctiva usually fail to grow, and when occasionally they do develop their growth is scanty, they die out readily, and cannot be propagated. In this they differ from the Petit type, which grows freely on ordinary agar. Growth on agar is quite exceptional. (I have recently grown one or two strains from conjunctivitis cases which at first showed a fair growth on agar, but on cultivation lost it. In gelatine stab cultures at room temperature slow growth and liquefaction occurred in these particular strains, just as in the Petit type. This was lost later.)

In *milk*, or *potatoes*, or sloped bullock's *blood*, and *blood media* they do not grow.

The media should always have an alkaline reaction; when neutral, the organisms grow badly, and acid media are unsuitable. This explains why the *Diplobacilli* in the presence of the *Staphylococcus pyogenes aureus* sometimes grow badly on serum, although they were present in excess in the secretion; indeed, the bacilli may not grow at all when the rapid growth of the cocci has produced an acid reaction in the medium. On the other hand, the *Diplobacilli* grow very well along with xerose bacilli, as these latter do not cause any change in alkalinity, but rather favour the growth of the former. They grow well with the ordinary white *Staphylococci* of the conjunctiva.

The *Diplobacilli* can often be obtained in pure culture from cases with profuse secretion, provided that the lid margins and angles are not touched.

White *Staphylococci* are fairly often mixed with them; generally they are of very low virulence, and in much smaller numbers than the *Diplobacilli*. *Pneumococci*, *Streptococci*, and Koch-Weeks bacilli are more rarely found (Hoffmann, Zia, Duane, Hastings, and others). Such cases are mixed infections, and may not show the peculiar clinical features of the disease. In the case of the last-mentioned an acute catarrh usually occurs.

If we take cultures daily, the admixed organisms are found to vary greatly in number, and may at times quite disappear. This shows the *Diplobacilli* to be the true pathogenic agents. If, however, the conjunctivitis, and with it the numbers of the *Diplobacilli*, subsides, the xerose bacilli and *Staphylococci* become more obvious.

Morphology of the Bacilli in Culture.

The colonies on Löffler's *blood-serum* only show for the first or second day *Diplobacilli* or *Streptobacilli* of varying size, such as are seen in the pus. A free degeneration of the organisms soon begins, with the formation of variable, sometimes grotesque, and very large involution forms. As soon as the liquefaction of the medium is well advanced, we only see amongst masses of unstained and dead organisms a few double forms, chains, or filaments of varying size. At this stage the outlines of the organisms stain more intensely than their centres (see Fig. 23).

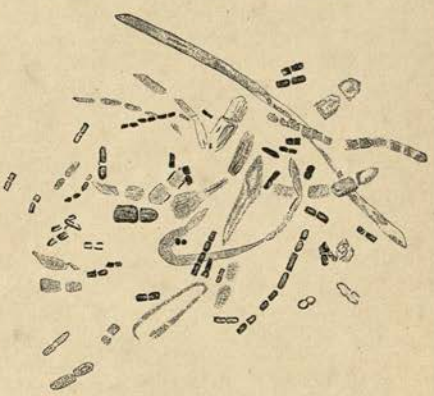

Fig. 23.—Forty-Eight-Hour Culture on Löffler's Blood-Serum—Involution Forms.

On *serum agar* and in *serum bouillon* their form and staining are retained longer.

Rapid decolorization occurs by Gram's stain. The organisms are non-motile, and do not form spores. The same is true of the Petit type.

Only once did MacNab obtain a slight hypopyon-keratitis with the Morax-Axenfeld bacillus.

Resistance.

The *Diplobacillus* dies out in a few days when on Löffler's serum in the incubator. In the liquefied medium only necrotic forms

are then found. It can best be recultivated when the fluid mass is poured out into ascites bouillon. An eight-day culture can no longer be propagated. These statements are generally agreed to, but exceptions do occur. MacNab made elaborate resistance tests in my laboratory, comparing the Morax-Axenfeld *Diplobacillus* with the *Diplobacillus liquefaciens* (Petit). He found that the *Diplobacillus liquefaciens* could be propagated from a sixty-days-old blood-serum culture. A strain of the Morax-Axenfeld *Diplobacillus* was similar. In

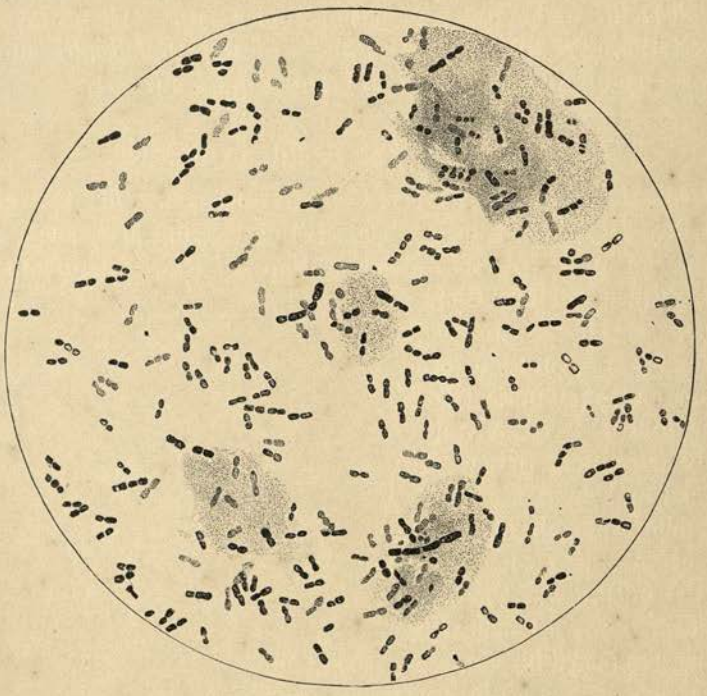

FIG. 24.—TWENTY-FOUR-HOUR CULTURE ON SERUM AGAR.

the water-bath both forms were killed when kept for five minutes at 55° C.; at 50° C. a growth still occurred.

When sterile splinters of wood were infected with *Diplobacilli* from an agar or serum-agar culture, and then dried in the oven for four days, media could still be inoculated with them; this was the case with both types of organism. From this I consider that the *Diplobacilli* could, under certain circumstances, remain a long time alive outside the body, and perhaps still cause infection. This is probably more often true for dried secretions than for dried cultures, as is the case

with the *Pneumococcus*. How far the *Diplobacilli* are 'drought-resisting' has still to be determined.

The reaction of pure cultures to zinc solutions of varying strengths is naturally of interest, considering the extraordinary beneficial influence which that salt has on the condition of the conjunctiva and the cornea when infected by *Diplobacilli*. Paul found that when a pure bouillon culture was dried in small reagent glasses, it could withstand the action of a $\frac{1}{2}$ to 1 per cent. zinc solution for a considerable time, even five minutes. It was really only after a half to one hour's action that any definite anti-bacterial effect could be demonstrated. As it is quite impossible for so strong a solution to remain for such a time in contact with the conjunctiva, Paul concluded that the action was not a simple disinfection.

Silva has further worked at this subject in my laboratory.

Silva first experimented to determine whether by continued instillations of weak solutions the zinc could pass into the anterior chamber. The curative action influences even deep purulent infiltrations, and it appeared that the zinc had penetrated into the tissues. No passage of zinc into the aqueous could be determined with the finest chemical tests, even after removal of the epithelium.

A $\frac{1}{2}$ per cent. zinc solution had very little lethal (disinfecting) action on cultures of *Diplobacilli*, but it did prevent development. Its curative action, according to Silva, was due to its power of restraining growth and preventing reinfection. With this assistance the conjunctiva and cornea were enabled to overcome the infection.

Conjunctival secretion dried on linen swabs for twenty-four days, retained living *Diplobacilli* which could be cultivated (Erdmann). Such a secretion twenty-five hours old still produced a typical diplobacillary conjunctivitis when introduced into the conjunctiva. When dried on glass rods, they grew on the medium after seven hours, but not later. At room temperature the time was longer than when they were in the incubator, as in the latter case complete dryness occurred sooner.

Diplobacille Liquéfiant of Petit.

(*Cf.* PLATE III., FIG. *II.*)

The previous description refers to the typical *Diplobacillus*, the cause of conjunctivitis, as first given by Morax and Axenfeld.

In 1898 Petit described a very closely allied bacillus, whose relationship to the Morax-Axenfeld organism will now be considered.

He found a Gram-negative *Diplobacillus* in three cases of superficial serpiginous hypopyon-keratitis with very slight pain (perhaps a case by Uhthoff and Axenfeld was of the same class). The organism

resembled that of Morax very closely in appearance, but was slightly smaller. Comparison of Petit's figures, which are here reproduced (Figs. 25 to 28), shows that the Morax-Axenfeld organism in cultures more often shows longer forms. These really are involution forms which occur more readily in the less resistant Morax-Axenfeld type, but do not constitute a constant differentiation. Much more commonly it is impossible to distinguish in fresh cultures between Petit's and the Morax-Axenfeld *Diplobacillus*. I have often been convinced of this. We can merely say that in the Petit type the double form is more constant and longer retained.

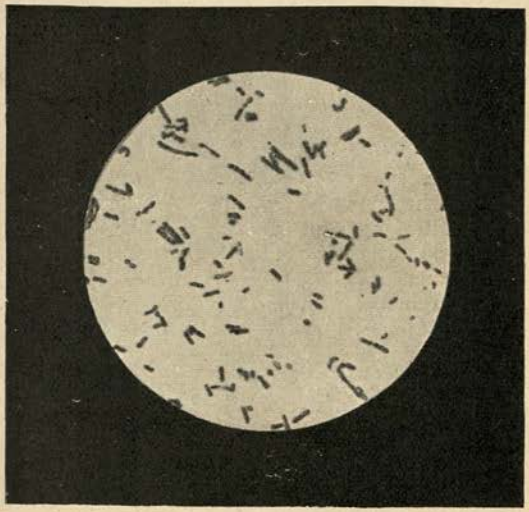

FIG. 25.—MORAX-AXENFELD DIPLOBACILLUS. × 800.

Serum-agar culture, showing many filaments.

A special characteristic of the Petit type is that it grows very readily on common media at 20° to 37° C.

Petit states that on agar thick, round, grey colonies develop, which are less prominent than those of the Morax-Axenfeld type, and have no central elevation. This latter differentiating point, which is shown in Petit's photographs here given (Figs. 27 and 28), has been shown by MacNab's investigations in my laboratory not to be constant. The central elevation may be absent entirely in the Morax-Axenfeld *Diplobacillus*, and can often be seen in the Petit type.

Coagulated serum is freely liquefied by the Petit type, as also is gelatine at 22° C. At 15° C. the liquefaction is slower. It grows rather badly in simple bouillon; milk is not coagulated; on potatoes a creamy, light yellow scum grows. It is an obligate aerobe. At 50° C. the bacillus remains alive for a quarter of an hour; at 55° C. it is killed in the same time. Kept at 12° C. it can still be propagated after ten days. For the usual laboratory animals it is not pathogenic. MacNab alone obtained a slight hypopyon-keratitis in rabbits.

Petit considered that the important distinctive characters of this type were its growth upon ordinary agar, and especially its power of

liquefying gelatine; he also only found it in cases of hypopyon-keratitis.

I have twice myself obtained such *Diplobacilli* from conjunctivitis cases which resembled clinically the ordinary diplobacillary conjunctivitis. I consider it established that the Petit type can also produce the conjunctivitis which has already been described, especially as Erdmann, by inoculating the human conjunctiva with *Diplobacilli* which grew freely on agar, has succeeded in producing a conjunctivitis.

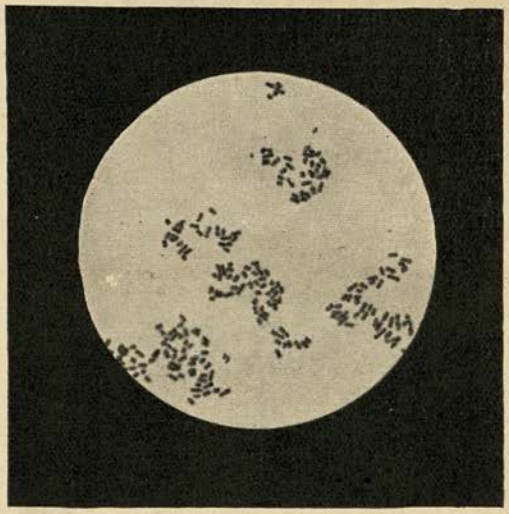

FIG. 26.—DIPLOBACILLE LIQUÉFIANT PETIT. SERUM AGAR. EXCLUSIVELY SHORT DIPLO-FORMS (PETIT). × 800.

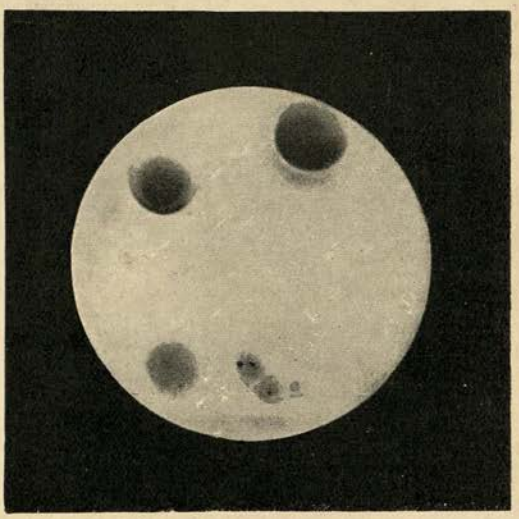

FIG. 27.—DIPLOBACILLE PETIT. SERUM AGAR COLONY (PETIT).

The power to liquefy gelatine and grow freely on agar, which was present at the outset in my two earliest examples of the Petit bacillus, was gradually lost in successive generations, so that they more nearly approached the Morax-Axenfeld type. MacNab conducted a further research under my direction to see whether, by continued growth under varying conditions, it might not be possible to transform the one type into the other. It was, however, not possible to develop in the Morax-Axenfeld bacillus the power of liquefying gelatine, nor could it be pro-

pagated from bouillon on to ordinary agar. The Petit type certainly lost its power of liquefying gelatine, but it could always be grown on simple media, and in any generation could be grown in bouillon, and from there again back on agar, which transference never was possible with the Morax-Axenfeld bacillus.

(In these experiments the Petit *Diplobacillus* was cultivated for two years on blood-serum.)

The Morax-Axenfeld *Diplobacillus*, too, can sometimes produce the same form of hypopyon-keratitis. This Petit had not had the opportunity of observing when he recorded his type. In my own material

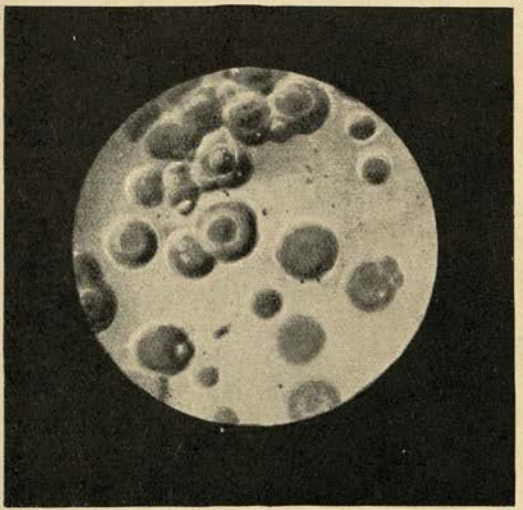

FIG. 28.—DIPLOBACILLE MORAX-AXENFELD. *Colonies 'Mammelonnées'* (PETIT).

Also occurs in Petit's type.



FIG. 29.—GELATINE STAB CULTURE OF PETIT'S BACILLUS.

Funnel-shaped excavation at 15° C.

consisting of twenty-three cases of diplobacillary keratitis, according to the analysis of Dr. Agricola, one-third were caused by the Morax-Axenfeld type, and an even higher proportion is recorded by Paul and by Erdmann. These two writers consider that the two types probably are identical. I am of the opinion that they are very closely related, but that they must be looked upon as variations of the same family so long as a complete transference of the one type into the other be accomplished. It may, perhaps, be possible. This point of view cannot is taken by Zur Nedden, who only found the Petit type in hypopyon-keratitis. It is very peculiar that the Petit variety is rare in conjunctivitis, but is fairly frequently found in the cornea in

hypopyon-keratitis, while the Morax-Axenfeld type is more prevalent by far in conjunctivitis. It is best to speak generally and collectively of diplobacillary conjunctivitis and diplobacillary keratitis, and to recognize that both the common Morax-Axenfeld and the rare Petit varieties can produce the same clinical appearances.

Pathogenicity.

Morax asserted that his *Diplobacillus* possessed no pathogenic powers for laboratory animals, either locally, subcutaneously, or intraperitoneally. Apes and birds were also quite refractory to it. All the later investigators came to the like conclusion. Rymowitsch alone stated that he had obtained a severe plastic iritis by injections into the anterior chamber; and this has been confirmed by Rupprecht in my laboratory. Injection into the vitreous produced an abscess. The Petit type has a greater action (MacNab), and occasionally produces a slight hypopyon-keratitis in rabbits.

Morax, by instilling a twenty-four-hours ascites bouillon culture into the conjunctiva of one of his colleagues produced a typical subacute conjunctivitis. This began after four days' incubation. Shortly after inoculation no *Diplobacilli* could be found in the conjunctiva, but when the discharge began they were numerous, and again completely disappeared when sulphate of zinc had produced a cure.

Axenfeld introduced into a healthy conjunctiva a loopful of a forty-eight-hour culture on bullock's blood-serum which had already begun to liquefy. The result was negative, perhaps because of the medium used for culture and the degeneration of the bacilli which had occurred. The inoculation of a fleck of secretion, which when first rubbed on serum produced a pure culture of *Diplobacilli*, resulted twice in a typical diplobacillary conjunctivitis, with four days' incubation, and a profuse pure culture of the *Diplobacilli* in the secretion. The conjunctivitis passed over into the other eye, and rapidly healed under zinc.

Hoffmann and also Gifford obtained similar positive results on inoculation. The course was a little different in Hoffmann's case, as the secretion commenced on the second day, though the discomfort was only felt on the fourth.

There is a widespread susceptibility to this disease, and exceptions are rare. The investigations of Plaut and von Zelewski in my laboratory have shown that such exceptions do occur, as they found the *Diplobacillus* twice on practically normal conjunctiva in cases of

lacrymal sac excision. Rymowitsch found the *Diplobacillus* six times in 100 normal cases. B. Harman found it on the normal conjunctiva, as did Erdmann, who agreed with Biard that the *Diplobacillus* can sometimes be met with in the noses of healthy persons,[1] without causing any disease there. When introduced with the conjunctiva, however, it causes an inflammation. Provided that the organisms found on the conjunctiva were pathogenic, a definite disposition can be presumed, though such is rarely of any marked degree; this is shown by the numerous family epidemics. There is usually a high degree of contagiousness and susceptibility.

As acute cases can occur, widespread acute epidemics cannot be excluded, though they have not yet been observed.

The *Diplobacilli* have no great tendency to infect wounds of the globe. I have seen severe perforating wounds heal cleanly even in the presence of profuse diplobacillary conjunctivitis. Our experience with diplobacillary hypopyon-keratitis teaches us, however, that this organism must be reckoned upon in wounds of the cornea. The variety *Diplobacille liquéfiant* of Petit appears to be especially dangerous, and as this organism cannot be distinguished in secretion from other *Diplobacilli*, before every operation and in every wound an examination for *Diplobacilli* should be made, and treatment adopted if necessary.

Immunity against the infection only occurs to a very slight degree and very rarely. This is shown by the great chronicity of the process, which rarely heals spontaneously; also by the frequency of recurrences, whether due to the fact that the *Diplobacilli* had not quite disappeared on treatment or due to reinfection.

Differential Diagnosis.

All other bacilli found in the conjunctiva (diphtheria and xerose bacilli, Koch-Weeks and its allies, *B. coli*, Friedländer's and Zur Nedden's) are radically different either in shape or staining.

Friedländer's *Pneumobacilli* are almost the same size, and decolorize in the same way with Gram; they do not, however, lie so regularly in pairs, and have a much more definite capsule than the *Diplobacilli*, in which the capsule is inconstant or invisible. The same may be said of the closely allied ozæna bacillus.

Their cultural peculiarities are quite different. The *Pneumobacillus* and ozæna bacillus flourish on ordinary media, and that, too, at room temperature. They are especially characterized by the 'nail' culture in gelatine, which does not occur with the *Diplobacillus*.

These two organisms have a well-marked pathogenicity for animals, which the *Diplobacillus* has not.

It is quite inexplicable how Pes, under these conditions, could consider the *Diplobacillus* as identical with the *Pneumobacillus*. That author has merely stated the opinion; he has furnished no proof.

The paired arrangement is inconstant in Zur Nedden's bacillus, which is also

[1] Harman's hypothesis that the *Diplobacillus* (apparently, too, the Koch-Weeks bacillus) occurs in the stomach, and is transferred by contact during vomiting, is quite without proof.

different in form and size. On close examination a differentiation may thus be established (*cf.* Plate C, Fig. *III.*). (The form of the Zur Nedden bacillus is more like that of the *Bacillus xerosis*, from which it is distinguished by being Gram-negative). In culture a difference is shown at once, as the Zur Nedden bacillus (like the *Bacillus coli*) grows freely, as a thick slime, on all ordinary media, does not liquefy blood-serum, and generally behaves quite differently.

Stock records the pathological examination of the lids in a case of diplobacillary conjunctivitis available for section at the height of the affection. He found considerable hypertrophy of the epithelium in the region of the lid margins and the macerated skin, with development of glandular ingrowths. In the conjunctiva was a widespread infiltration of the mucosa, with enormous numbers of goblet cells.

Attempts to stain the bacilli on the surface of the conjunctiva were only partly successful in sections. We cannot say how deeply they penetrate into the tissues; probably they are restricted to the surface of the epithelium. Mayou stated that in this condition it was only the less resistant plasma cells which were multiplied in the sub-epithelial tissues.

Morax and Petit anatomically examined a fresh ulcerated and perforated leucoma adherens, and found in the infiltrated margin numerous *Diplobacilli*, which stained best with Nicolle's carbol thionin.

Paul had the opportunity of examining a non-perforated diplobacillary hypopyon-keratitis. The corneal process affected an absolutely glaucomatous eye. The findings were analogous to those of an ulcus serpens, with a progressive border on the one side and epithelial growth on the other. The appearance was so far different from the commonest appearance of a pneumococcal ulcer, in that the floor of the ulcer was deeply infiltrated. Cultures showed the Morax-Axenfeld type of *Diplobacillus*, which, however, Paul could not find in the sections.

The treatment with sulphate of zinc (Morax), which has such a beneficial result in these cases, must be continued for weeks in order to obtain healing without recurrence. Several authors (Lundsgaard, Mallet) report that yellow oxide of mercury ointment is especially valuable in many cases. Morax recommended it for the further treatment of obstinate cases. It is remarkable how long a contact is necessary for the zinc to kill the Bacteria (Paul, Silva). A direct specific action therefore does not occur.

I have been able to demonstrate that diplobacillary hypopyon-keratitis is profoundly influenced by instillations of zinc. This is confirmed by Paul, Erdmann, and MacNab. The contradictory

results of Zur Nedden, who considered Saemisch's section necessary for most cases, perhaps are due to the use of other treatment than zinc. We instil zinc lotion on to the cornea ten or twelve times a day, and also bathe the eye for several minutes in it. It is important that this should be done late in the evening, and in severe cases even repeated several times during the night. The results amply justify the time and trouble taken. In over twenty cases, amongst which were several very severe ones, we have obtained healing with zinc alone. A paper by Agricola gives the fuller details of these cases. Paul obtained very good results by repeatedly syringeing the ulcer. He reports that a zinc encrustation once formed, and therefore advises that the use of the solution should not be continued for an unnecessarily long time.[1] We have never had such occur. Without going so far as to say that every case of diplobacillary infection of the cornea must heal with zinc, I personally have never seen it fail.

Erdmann reported two such failures, but it is not clear how often the zinc was used. A marked infiltration often occurs on the next day even in successful cases; this is not necessarily a sign of spread, but of a reaction. If advance is not arrested within twenty-four hours, surgical treatment should be adopted. Complications which may arise should be suitably treated.

Meyerhof states that when trachoma complicates diplobacillary infection (in Egypt), the cases do not react to zinc, and are better treated with silver nitrate.

LITERATURE.[2]

AGRICOLA, Über eitrige Diplobazillenkeratitis. K. M. f. A., 1906, Beilageheft.
ALT, Amer. journ. of ophth., 1898, p. 171.
ALEXANDER, Münch. med. Woch., 1903, S. 1236.
ANDRAD, Amer. journ. of med. sciences, 1902.
AXENFELD, Heidelberger Kongress, 1896. Zentralbl. f. Bakteriologie, 1897, Bd. 21, Nr. 1 and Berliner klin. Wochenschrift, 1897, p. 847.
BACH-NEUMANN, A. f. A., 1898, Bd. 37, S. 57.
BIARD, Étude sur la conjonctivite subaiguë. Thèse de Paris, 1897.
BIETTI, Annali d' ottalmologia, 1899.
BREWERTON, Lancet, 1903, p. 1036.
BROWN-PUSEY, Journal of the Amer. Med. Assoc., 1906.
BUTLER, R. L. O. H. Rep., XVII, 1, p. 115.
CHRISTENSEN, Ophth. Klinik, 1906, S. 171.
COLLINS, TREACHER, Report of the Metropol. Asyl. Board, 1906 (Ref. Münch. med. Woch., 1906, S. 2364).

[1] The translator has had very good results by both of these methods. In one case an increase in the strength of the zinc solution from ½ to 1 per cent. caused a spread of the ulceration, which subsided when the weaker solution was resumed.

[2] Also see literature on 'General Conjunctivitis.'

COLLOMB, Revue méd. de le Suisse Romande, December, 1899.
CORSINI, Supplemento al Policlinico, November, 1900.
DERBY, G. S., Bacteriology of the eyelids. Journ. of the Amer. med. Assoc., 1906.
DORLAND SMITH, Ophthalmology, July, 1905.
DUANE and HASTINGS, New York Med. Journ., May 26, 1906.
ERDMANN, Diplobazillengeschwüre der Cornea. K. M. f. A., 1905, LXIII, Bd. 1, S. 501.
EVANS, The Ophthalmoscope, April, 1904.
EYRE, Brit. Med. Journ., 1898, p. 1964.
GIARRÉ and PICCHI, La Settimana medica, 1898, Nr. 28, 1901, Nr. 8.
GIFFORD, Annales of ophthalmology, April, 1898. Ophth. Record, 1905, XIV, p. 511.
GONIN, Revue médicale de la Suisse Romande, February and March, 1899.
DE HAAN (Java), Janus, December, 1905.
HANKE, Wiener klin. Rundschau, 1906, Nrs. 25 and 26.
HOFFMANN, A. f. O., 1899, Bd. 48, S. 639.
HOTTA (Japan, Hiroshima), K. M. f. A., 1906, II, S. 3444.
LAKAH and KHOURI, Ann. d'ocul., 1902, t. 128, p. 420.
LOBANOW, Archiv f. Ophth., 1900, Bd. 51, 3, S. 433.
LUNDSGAARD, Bakteriol. Studien von Conjunctivitis, 1900. Kopenhagen u. Hospitalstidende, 1905, S. 249.
MALLET, Les conjonctivites catarrhales. Thèse de Toulouse, 1905.
MCKEE, S. H., Montreal Med. Jour., September, 1905; April, 1906; February, 1907. —*Ibid.*, Amer. Jour. of Med. Sc., June, 1906.—*Ibid.*, Ophth. Rec., April, 1907.
MCKEE, H., Montreal Med. Jour., March, 1907.
MACNAB, Diplobac. liquefac. und Diplobac. Morax-Axenfeld. K. M. f. A., 1904, XLII, Bd. 1, S. 54.—*Ibid.*, Blepharitis margin. R. L. O. H. Rep., 1905.—*Ibid.*, Ulceration of the Cornea, London, 1907.
MEYERHOF, K. M. f. A., XLIII, II, S. 230.
MORAX, J., Ann. de l'Inst. Pasteur, June, 1896, et Ann. d'oculist., January, 1897; Encyclopédie française d'ophthalmologie, Maladies de la conjonctive, 1905.
MÜLLER, L., A. f. A., 1899, Bd. 40, S. 13.
NICOLAI, Neederl. Tijdschr. v. Geneesk., 1904, p. 722.
OLIVER, Journ. of Amer. Med. Soc., 1904, p. 420.
PAUL, Hornhautulceration durch Diplobazillen. K. M. f. A., 1905, XLIII, Bd. 1, S. 154.
PETERS, K. M. f. A., 1897, S. 181.
PETIT, Recherches clin. et bact. sur les infections aiguës de la cornée, Paris, 1900.
PFLÜGER, E., Korrespondenzbl. f. Schweizer Arzte, 1902, S. 381.
POLLOCK, Ophthalmic Review, 1904, p. 381, and T. O. S., 1904, XXV.
RANDOLPH, Journ. of the Amer. Med. Ass., 1903, p. 821.
ROCHAT, Nederl. Tijdschr. v. Geneesk., 1904, p. 718.
RYMOWITSCH, Postemp okul., 1900, Nr. 9.
SANTOS-FERNANDEZ, Arch. hispano-amer. de oft., 1904, p. 141.
SAEMISCH, 2 Aufl. des Handbuchs, 'Bindehauterkrankungen,' 1905.
SCHMIDT, A. f. A., 1902, Bd. 45.
SCHOUTE, Berl. klin. Woch., 1898, Nr. 16.
SILVA, Experimentelle Untersuchungen über den Einflus des Zincum Sulphuricum auf die Diplobazillen. K. M. f. A., 1906, Beilageheft.
SMITH, D., Arch. of ophth., 1905, XXXIV, p. 481.
DE SCHWEINITZ and VEASY, Ophth. Record, 1899.
STOCK, W., Anatomische Untersuchung über Diplobazillenconjunctivitis. K. M. f. A., 1903, Bd. 42, Beilageheft (Festschr. f. Manz).

STOEWER, Diplobazillenkeratitis. K. M. f. A., 1905, XLII, Bd. 2, S. 142.
TOOKE, F., Ophthalmic Record, May, 1906.
USHER and FRASER, R. L. O. H. Rep., 1906, XVI, p. 434.
VALLAUDÉ, Thèse de Bordeaux, 1901, S. 78.
ZUR NEDDEN, K. M. f. A., January, 1902.
ZIA, Ätiologie der versch. Conjunctivitisformen. Inaug.-Diss., Marburg, 1903.

SECTION 3.—PNEUMOCOCCAL CONJUNCTIVITIS.

PLATE II., FIG. *II.*

Historical.

In 1893 Gasparrini found *Pneumococci* on the conjunctiva in cases of hypopyon-keratitis, and was able to produce a pneumococcal conjunctivitis in rabbits by the injection of *Pneumococci* under the conjunctiva, or their introduction on to the injured mucous membrane.

Morax and Parinaud (1894) give the first records of pneumococcal conjunctivitis as a definite disease in man. Parinaud described it in infants at birth as a unilateral, benign, but often chronic affection, which was associated with severe lacrymation and nasal catarrh, and in many cases with inflammation and stenosis of the nasal duct. Parinaud considered it possible that the whole infection arose from the nose, but that infection direct from the vagina was more probable. Morax, under whose direction this research was conducted, expressed doubts later concerning the causal significance of the *Pneumococci* in these cases, seeing that when examined daily they might for a time be quite absent. They have, at all events, only a secondary importance.

Morax' earliest cases were children under two years old. He stated that a slight pseudo-membrane formed, but that there was no lacrymal affection. The conjunctivitis subsided in a few days. Morax considered that it was not contagious, as he only observed single cases, which were limited to one eye.

The papers by Gasparrini and by Axenfeld appeared simultaneously in 1896. Both proved in numerous cases of varying ages that both eyes were almost invariably affected successively, and that frequently many people living together became affected one after the other. Axenfeld described two widespread epidemics. While Gasparrini concluded from his cases that pneumococcal conjunctivitis was always contagious, and to the same degree as Koch-Weeks conjunctivitis, Axenfeld was able to show that, in spite of the contagiousness of many cases, such was not constantly so for all persons. Both authors stated that the appearances varied in intensity. While Gasparrini

considered it impossible to distinguish the clinical appearances from those due to the Koch-Weeks bacillus, Axenfeld showed that the history and course of a pneumococcal conjunctivitis in many cases was characteristic.

The authors mentioned established its infectiousness from clinical considerations, but soon after Pichler (1896) and Gifford (1896) were able to furnish definite proof from actual inoculation on the healthy human conjunctiva. Veasy, Hauenschild, Baenziger and Silberschmidt also obtained positive results on inoculation.

Confirmatory records are furnished by the work of Adler, Weichselbaum, Gonin, Junius, Morax and Petit, Bach and Neumann, Hauenschild, Hallé, Denig, Hertel, Veasy and De Schweinitz, Brecht, Kibbe, Rymowitsch, Lundsgaard, Guignot, Pollock, Brown-Pusey, Duane and Hastings, D. Smith, Usher and Fraser, Augé.

Geographical Distribution and Occurrence.

Although the *Pneumococcus* is universally distributed and can be demonstrated in the buccal cavities of most people, pneumococcal conjunctivitis is not so evenly distributed.

For this reason the occurrence of extensive acute epidemics has not been very often described; we have only the records of Axenfeld (Marburg and environs), Adler and Weichselbaum (Sarasdorf, in Lower Austria), Junius (Königsberg, in Prussia), Hauenschild (Würtzburg), Gifford (Omaha, U.S.A.), and Consalvo (Milan). Some special conditions must be necessary to produce an epidemic, for the endemic occurrence of single cases and small family epidemics are very widespread, especially in Germany, Italy, U.S.A., Denmark (Lundsgaard), England, Switzerland, and certain parts of Russia (Rymowitsch, in Kasan); while in Egypt, for example, where acute Koch-Weeks catarrh is so universally prevalent, Morax, Lakah, and Khouri agree that pneumococcal conjunctivitis is very rare. Meyerhof found it rather more commonly in Egypt, and Butler records it as common in Palestine. Axenfeld saw it very frequently in Marburg, Breslau, and Rostock; in Freiburg, however, much less often. In the last-mentioned town Koch-Weeks bacilli were common, but were practically never seen in the other three places. Gasparrini, Gonin, and Rymowitsch alone have recorded an approximately equal prevalence of the two chief forms of acute conjunctivitis.

So far as we can form any conclusion from these epidemiological data which still need amplification, pneumococcal conjunctivitis

appears more prevalent in Northern countries, and especially in the colder months of the year (Axenfeld, Gifford, Rymowitsch). The history of a 'chill' is a common examplification of this.

It is very noticeable how seldom a pneumococcal conjunctivitis is associated with a pneumonia; we only know of very few cases (Rymowitsch, Stschegolew, Petit). It is quite rare for a severe bronchitis or an angina to accompany the conjunctival affection. The other pneumococcal affections of the body have no common association with pneumococcal conjunctivitis. Very often a cold in the head occurs immediately before or along with it.

Hertel had three severe cases following measles.

Clinical Appearances.

An acute catarrh develops very rapidly in both eyes successively. It varies in intensity and duration; there are very severe cases resembling blennorrhœa, with intense redness, swelling, and profuse secretion, and slight abortive cases, in which all the symptoms disappear in a few days. It is clear, therefore, that the appearances are not absolutely characteristic of the *Pneumococcus*, and that confusion with other infections may occur; nevertheless, when the whole course of the disease is considered, it presents relatively characteristic features. The disease in different places and at different times seems to vary somewhat. Gifford and Gasparrini have seen quite a large number of very severe cases in proportion to their infrequency in other places. Cases of medium severity, as a rule, present the following features: At first a pinkish œdema of the lid margins, especially the upper (held by Morax to be very characteristic); acute onset of the conjunctival congestion, with moderate swelling, and occasionally a superficial false membrane, so that within a short time the height of the affection is reached; and a profuse watery secretion, with a few white purulent flakes. The redness of the conjunctiva bulbi is very pronounced; frequently small phlyctenular nodules occur at the limbus corneæ, and very often small hæmorrhages, which tend to increase, especially in the upper part of the bulbar conjunctiva in the region covered by the upper lid. The hæmorrhages soon take on a pronounced yellowish-red colour, and rapidly disappear when the affection subsides. This subsidence often occurs with great suddenness; very soon after the most acute stage is reached there is a crisis: the *Pneumococci*, which have been very plentiful in the secretion, rapidly disappear, and during the final stages only *Bacillus*

xerosis and *Staphylococci* are to be found. This distinct critical termination, to which Axenfeld first called attention, comparing it with the crisis in pneumonia, is often well seen in ophthalmia neonatorum (*cf.* von Ammon, *Münch. Med. Woch.*, 1900, I., p. 12).

Although these catarrhal inflammatory symptoms can also occur in Koch-Weeks conjunctivitis, the peculiar critical termination, generally with rapid improvement and without any vigorous treatment of the conjunctiva, is very characteristic of pneumococcal conjunctivitis. The frequent occurrence of a severe 'cold in the head' is not to the same degree peculiar to the other forms of infection. The typical course of a pneumococcal conjunctivitis occurs more often in epidemics than in sporadic cases, and many authors (*e.g.*, Pollock) who have only seen single cases have never had the opportunity of observing this critical course.

In sporadic cases, however, it is often so obvious that Junius, Gifford, Gonin, and Hauenschild were able from it to establish a provisional diagnosis in the great majority of their cases. This is more often possible in districts where Koch-Weeks conjunctivitis does not occur; while in those districts in which both forms are plentiful greater caution must be observed, as of course an etiological diagnosis from purely clinical observation can only be called probable.

In my experience a chronic pneumococcal conjunctivitis is rare; in such cases we must carefully examine for a dacryocystitis or dacryostenosis, which is secondarily affecting the conjunctiva. Scholtz and Vernier report that they have found chronic cases rather more frequently. In connexion with this diagnosis, the facts given on p. 112 (the facultative producers of conjunctivitis) must be carefully considered.

I was able to demonstrate that a disposition for children occurs in many epidemics, as, for example, in one village very many children, but not a single adult, were affected, although the latter took no precautionary measures, and often came in contact with infected material. In this sense, therefore, pneumococcal conjunctivitis is a disease of children. This peculiarity does not, however, occur in all epidemics, and adults are sporadically affected no less frequently. Junius and Hauenschild confirm this. It is worth noting that no large epidemics have yet been described amongst adults, although such are often caused by the Koch-Weeks bacillus.

It appears not improbable that a definite conjunctival immunity to *Pneumococci* generally occurs amongst adults.

It is quite established that a very superficial false membrane can

occur; severe pseudo-membranous forms due to *Pneumococci* alone are rare. Croupous and diphtheritic forms have been described by Wagner, Pes, Gonin, Morax and Petit, Fruginelli, Kimpel, and Hertel. A lid abscess occurred in Fruginelli's case.

According to the observations of Bardelli, Axenfeld, and Rymowitsch, an iritis from absorption of toxins can be associated with a pneumococcal conjunctivitis, and that without any affection of the cornea. Gasparrini, who saw quite a large proportion of severe cases, states that the iritis frequently occurs at the beginning of the affection; Rymowitsch agrees in this. Those cases in which severe pain and swelling of the pre-auricular gland occur resemble the clinical appearances of the 'lacrymal streptococcal conjunctivitis' described by Parinaud and Morax. I can confirm the statement of Rymowitsch that the iritis can outlast the conjunctivitis.

Although a pneumococcal infection of the cornea (ulcus serpens) is very common after slight injuries, it is very rare in a true pneumococcal conjunctivitis. The experiments of Coppez show that pneumococcal toxin has very little or no influence on the intact corneal epithelium; in the absence of any casual injury, therefore, the opportunity for the organism to settle down can only rarely occur. Gasparrini, Gifford, and Junius often saw so-called catarrhal infiltrates and ulcers. Severe suppurations rarely occur (Gasparrini, Wagner, Hertel), Oertzen described a severe wound infection from an intercurrent conjunctivitis.

The great importance of pneumococcal infection of the conjunctiva in the new-born infant, previously asserted by Morax and Parinaud, is clearly shown in the works of Axenfeld, Groenouw, von Ammon, Lundsgaard, and Schmidt-Rimpler. These observers agree that this catarrh is considerably milder than that due to the *Gonococcus*. Severe cases of blennorrhœa neonatorum, due to *Pneumococci*, are certainly very rare (Gasparrini).

In trachomatous countries records by Gasparrini, Gifford, Junius, Lakah, Khouri, and Rymowitsch show that pneumococcal conjunctivitis may be associated with trachoma, making it acute or chronic. It is, however, peculiar that in a country (Egypt) where trachoma is so frequently combined with Koch-Weeks infection a mixed infection with *Pneumococci* is so rare. The preference of pneumococcal conjunctivitis for cold climates is also remarkable.

The formation of follicles in pneumococcal conjunctivitis has only rarely been observed (Axenfeld, Junius). When they occur in large numbers, as a rule they have existed previously, and the appearance

resembling trachoma is not due to the pneumococcal infection alone.

Gasparrini has stated that a trachoma is improved by the occurrence of a pneumococcal infection. Ferri recommends inoculating the conjunctiva with *Pneumococci* in the treatment of trachoma. Rymowitsch is of the same opinion; he hoped in this way to found a bacterial treatment of trachoma. We cannot yet say whether this expectation will be generally realized; Gifford and Junius, who often saw this combination, record no improvement from it. The *Pneumococcus* must have some special curative power on trachoma, for the other secondary infections, especially the common ones due to Koch-Weeks bacilli or *Gonococci*, cause no appreciable improvement in the granular condition. Augstein considered that there was an antagonism between trachoma and *Pneumococci*, to the extent that the trachomatous cornea is much more resistant to that organism.

Infection. Susceptibility.

Inoculation of pneumococcal conjunctivitis on animals is only rarely successful; Gasparrini reports positive results after scarification of the conjunctiva. Uhthoff and Axenfeld saw severe conjunctival inflammation develop on one or two occasions after corneal inoculation. In general the rabbit's conjunctiva is very slightly susceptible, as the negative results of Noeldeke's experiments show.

A pathogenic significance of the *Pneumococcus* for the human conjunctiva is, nevertheless, quite compatible with these findings.

Contagiousness can be inferred from the occurrence of epidemics characterized by the presence of large numbers of *Pneumococci* in the secretion. Definite proof is furnished by Gifford and by Pichler, who both obtained the same appearance in the human conjunctiva by inoculating with pure cultures; along with their results we have also those of Hauenschild and Veasy, and the four positive inoculations which Bänziger and Silberschmidt obtained with attenuated cultures. The last-mentioned authors produced in one case a typical conjunctivitis by the transference of secretion.

Pichler gives no details of his inoculations. At first Gifford obtained no results with aerobic cultures, but with anaerobic, as also with secretions, a conjunctivitis occurred (Hauenschild obtained similar results); the incubation period was forty-eight hours. According to Hallé, the incubation period sometimes appears to be longer than this. He observed the onset after seven days, in a doctor whose eye had been infected with empyæmic pus.

These positive inoculations are opposed to Axenfeld's results: in eight inoculations with secretion he obtained no reaction, as also in one case in a child. The fact is thus demonstrated that a definite personal variation for susceptibility occurs along with this contagiousness. The possibility that many secretions may not possess the power of producing an infection in other persons must always be remembered, as was shown by Gifford on his own conjunctiva, which was susceptible to infection, although an inoculation a short time previously with a secretion produced no result.

This variation in contagiousness is confirmed by the frequent occurrence of isolated sporadic cases, which do not spread in spite of the fact that they have a profuse secretion and abundant opportunity for contact. The exemption of adults in many epidemics is also due to this factor.

Many people have *Pneumococci* on their normal conjunctiva. A conjunctivitis, therefore, like a pneumonia, may result from an increase in the virulence of the organisms already present, or from a lowered resistance on the part of the patient. The 'chill' so often recorded in these cases may in this way have some determining influence.

We have, therefore, on the one side, the possibility that the disease is the result of a form of self-infection; on the other, the certainty that the secretion is definitely contagious for the conjunctiva, though not by any means so much so as that from cases of Koch-Weeks, gonococcal, or diplobacillary infections.

We cannot yet say to what extent a single attack of pneumococcal conjunctivitis will produce immunity. Gifford inoculated himself with a positive result, but after a few weeks was unable to repeat this. In his case, however, an inoculation previous to both of these had had no result, though then he must have been susceptible. A complete proof of immunity would have required a positive result to have been obtained in some other individual with the last used inoculation material. Such a test would have been of great interest.

Findings in the Secretions.

PLATE II., FIG. *II.*

Pneumococci can, as a rule, be found in enormous numbers during the progress of the disease to its height. They are typical in shape, and occur in pure culture, especially in the small flakes of pus; they tend to lie in the cells, but are also found free. They differ from those

found in pneumonic sputum in that the capsule is not so obvious. Although many of the *Diplococci* may be round and short, we never fail to find large numbers of the typical elongated forms, from which, in a Gram-stained slide, a certain diagnosis can be given, and a differentiation from other *Diplococci* (*Gonococci* and *Staphylococci*) readily made.

As soon as the inflammation begins to subside, the *Pneumococci*, which previously were often in pure culture, rapidly disappear; the xerose bacilli and *Staphylococci* become again more obvious, and as the secretion diminishes, may appear in enormous numbers.

Mixed infections with other organisms known to cause conjunctivitis are not common. When a pure conjunctival secretion is taken at the height of the disease, pure cultures are often obtained. Morax states that mixed infection with diphtheria bacilli is relatively common. Lundsgaard microscopically examined a piece of the conjunctiva which he had excised, and found a diffuse leucocytic infiltration. *Pneumococci* could also be found in the superficial layers of the submucosa.

In **cultures** the bacilli present a characteristic appearance; the tendency to the formation of chains is well marked (Kruse and Passini use the term '*Streptococcus* of the conjunctiva'). In cases where the secretion preparation is not typical the differential diagnosis from *Streptococcus pyogenes* may present difficulties; this has been emphasized by Lundsgaard.

Morphology and culture of the *Diplococcus pneumoniæ* (*Diplococcus lanceolatus*, Fränkel-Weichselbaum's *Diplococcus* or *Pneumococcus*, *Diplococcus* of sputum septicæmia).

The *Diplococci* are arranged in pairs, and generally elongated; the typical coccus is slightly pointed at its ends, forming a lancet shape. Every secretion preparation will show some such forms. We also find short, more rounded *Diplococci*, and here and there short straight chains of variously shaped members, sometimes also short bacilli, and occasionally single large involution forms. Their size is very variable. Where the *Pneumococci* are in large masses, which is especially the case in the tissues, the individual cocci do not lie so closely together as do *Staphylococci* or *Streptococci*, on account of their capsules, which keep them apart. The capsules, as a rule, are clearly seen when the preparation is stained with a simple aniline dye and examined in water; they are less well seen in a conjunctival secretion than in other secretions. When stained with Gram, with which they are positive, the capsules are less well seen, and in Canada balsam are practically invisible.

Pneumococci will only grow at a temperature over 22° C.; their optimum is 35° C. They require a faintly alkaline medium; different strains vary in their sensitiveness to acidity. The media must be moist and not too old. On agar and blood-serum the colonies are seen as fine, clear, round surface drops, faintly opalescent in transmitted light; sometimes they are

FIG. 30.—SECRETION FROM A PNEUMOCOCCAL CONJUNCTIVITIS.

FIG. 31.—PNEUMOCOCCAL PUS FROM A RABBIT'S INOCULATED CORNEA, SHOWING INVOLUTION FORMS.

minute elevations resembling colonies of *Streptococci*, but not so sharply marked. In a few days the colonies may become practically invisible. Single colonies of *Pneumococci* on moist media may be so slightly raised above the surface that their presence can only be demonstrated by examining the surface moisture which has been removed with a platinum

a *b* *c*

FIG. 32.—VARYING APPEARANCE OF PNEUMOCOCCI ON GLYCERINE AGAR (UHTHOFF AND AXENFELD).

c, Elongated bacillary forms.

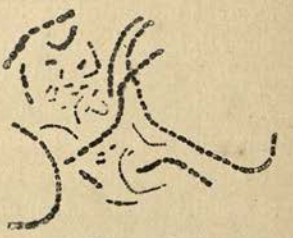

FIG. 33.—CHAIN FORMATION IN BOUILLON AND ON GLYCERINE AGAR (UHTHOFF AND AXENFELD).

loop. (In order to increase the bacterial contents of such material, Römer has recommended that it be first put into a mixture of fluid blood-serum of a young rabbit with one-third its volume of glycerine.) It often occurs that many agar media which are otherwise quite useful cannot be used for *Pneumococci*. When obtained from the conjunctiva

the organism appears to be more refractory in this respect than when it is obtained from pneumonic sputum; in the latter case more fluid of human origin is transferred to the medium. Carefully prepared serum agar (ascites, etc.) and blood-serum are very good media.

In the incubator cultures usually die out in a few days. Under anaerobic conditions they usually live longer, and retain their virulence rather better, though even then it rapidly diminishes. The same is true when the organism is kept in an ice-chamber. They live longest when in sputum or other organic material, even if it be dried. In bouillon only a very slight cloudiness forms, and this very rapidly clears again. In grape-sugar bouillon, growth is freer, with the formation of acid; it does not, however, last long.

The morphology in cultures corresponds to that in secretions; the variations are, however, more marked. Growth in chains occurs much more freely in some strains, especially if they are taken from bouillon or from the condensed water of solid media. In such cases the differentiation from *Streptococcus pyogenes* may be very difficult; hence the designation by Kruse and Passini, '*Streptococcus* of the conjunctiva.' Well-marked capsules are sometimes formed around the chains. The variety of *Streptococcus* described as *Streptococcus mucosus* is very closely related to such pneumococcal strains. The discussion on this question is not yet concluded (see *Zentr. f. Bakt.*, 1906, xxxviii., Ref., pp. 176 and 663, etc.). Some time ago I obtained a particularly marked example of this variety in a culture from an ulcus serpens (see Fig. 34).

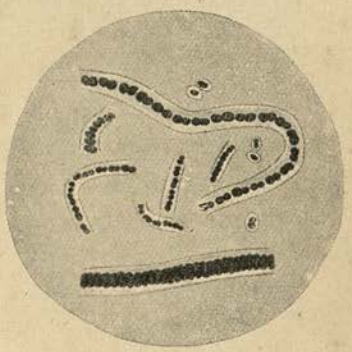

FIG. 34.—A STEM RESEMBLING STREPTOCOCCUS MUCOSUS (UHTHOFF AND AXENFELD).

Formation of capsules and capsulated chains on glycerine agar.

Wirtz[1] found an organism on the conjunctiva which showed all the peculiarities of the *Streptococcus mucosus* given by Schottmüller and Schuhmacher, but had no elongated forms. This organism was obtained from an old case of trachoma, which had peculiar glutinous masses of secretion, almost cell-free, and so adhesive that they could be drawn out into threads like elastic. The conjunctiva appeared to be in a state of very slight irritation; still, the secretion remained chronic, and the case became complicated by a very severe corneal ulcer. *Diplococci* were found in the secretion; they were round or slightly flattened at their points of

[1] *Re* 'Conjunctivitis with peculiar secretion caused by the *Streptococcus mucosus*,' see *K. M. f. A.*, October, 1906, Bd. ii., where the rest of the bacteriological literature will be found.

contact, and were never elongated. The cocci were Gram-positive, and had wide baggy capsules, which were easily stained by the methods of Klett or of Heim.

Cultures.—Bluish-grey colonies the size of a pin's head grow on gelatine at 25° C. without liquefaction. In bouillon a slight transient opacity, accompanied by a slight slimy deposit, occurs after twenty-four hours. Growth is better in grape-sugar bouillon; in blood bouillon the blood sinks in clumps to the bottom, with partial hæmolysis. On agar grey colonies grow to the size of a pin's head or larger; these, when they are closer together, form a slimy scum on the surface. Blood-agar clears in the vicinity of the individual colonies, and takes on a greenish colour. On blood-serum growth is analogous to that on agar, but is not so vigorous. The best growth is obtained on litmus-nutrose agar. Milk coagulates in four days. Litmus lactose becomes slightly red in forty-eight hours. On potatoes no growth. No gas formation. Anaerobic growth is good. Cultures kept moist retain their vitality for a long time. Pathogenicity for mice is very considerable: 0·1 c.cm. of grape-sugar bouillon killed a mouse in twelve hours, with serous effusions and enlargement of the spleen. In the blood and in the exudate capsulated *Diplococci* of varying size and cocci in short chains were found, but no lancet forms.

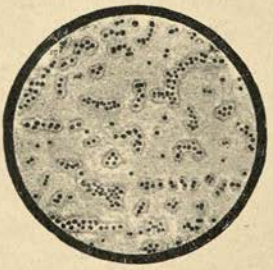

FIG. 35.—STREPTOCOCCUS MUCOSUS. AGAR CULTURE FROM THE CONJUNCTIVA.

A drawing from a preparation by Wirtz.

FIG. 36.—CONJUNCTIVAL SECRETION WITH STREPTOCOCCUS MUCOSUS.

Occasionally thick rods were seen; these Wirtz held to be cocci in close apposition, young forms in the act of dividing. In cultures the capsules were best shown by Giemsa's stain.

Wirtz states that in secretions and in the blood the absence of lancet forms differentiates this organism from the *Pneumococcus*. However, he rightly states that in cultures the distinction is more difficult on account of the tendency of many strains of *Pneumococci* to grow in chains. The *Streptococcus mucosus* grows best on grape-sugar bouillon and litmus-nutrose agar; it forms large colonies on agar and on serum of a clear gelatinous consistency (this occasionally occurs with the *Pneumococcus*). The method of differentiation by means of blood media, emphasized by Schottmüller, is of no use when dealing with this variety.

Seeing that the *Streptococcus mucosus* is considered as the pathogenic agent in many cases of inflammation of the lungs, sepsis, meningitis, and otitis media, and as it had considerable pathogenicity for animals in his case, Wirtz considered it to be the cause of the peculiar secretion, and recommended that this organism be looked for in all these cases. As the allied 'Leukonostoc' sugar became gelatinous, Wirtz considered whether a secretion particularly rich in carbohydrate might not be present in his case. Mucin was, however, only present in very small amount, and sugar tests were quite negative. The *Streptococcus mucosus* did not produce a slimy reaction when tried in various sugars. In the nose and in the throat of healthy individuals the *Streptococcus mucosus* is sometimes found.

Rupprecht[1] has lately recorded a double-sided case of conjunctivitis in my own clinic where a severe corneal suppuration occurred, the cultures being pure *Streptococci*. The cultures corresponded throughout to the Schottmüller type. In the secretion a differentiation from the *Pneumococcus* was not possible, as elongated *Diplococci* occurred with the round encapsulated cocci and chains, though on media which was quite suitable for the growth of *Pneumococci* only the *Streptococcus mucosus* grew. In the heart blood of a mouse inoculated with a pure culture of *Streptococcus mucosus* the elongated forms were not entirely absent.

Rupprecht has lately made the same observations in pus from a case of dacryocystitis, so that I can definitely assert that morphologically the so-called *Streptococcus mucosus* cannot be absolutely distinguished from the *Pneumococcus*.

I am strongly of the opinion that the *Streptococcus mucosus* should be merely considered as a variety of the *Pneumococcus*. The type is rare in the eye.

The view that the *Streptococcus mucosus* is really a *Pneumococcus* is increasing, and Levy (*Virchow's Archives*, 1897, Bd. clxxxvii., Heft 2) states that he prefers to use the term *Pneumococcus mucosus*, an opinion which I consider justifiable (*cf. Cent. f. Bakt.*, 1907, xxxix., p. 552: Duval and Lewis). The fact that after long cultivation Loncope, Beitske, and Rosenthal observed the development of the ordinary characteristics of the *Pneumococcus* in a mucosus strain, is strongly in favour of this view. In other cases this change could not be obtained (Schleuer, *Cent. f. Bakt.*, 1907, Orig., xliii., p. 332). Romer also records such transition.

It is noteworthy that fluid cultures of the *Streptococcus mucosus*, like the *Pneumococcus*, are cleared by bile or sodium taurocholate, while those of *Streptococcus pyogenes* are not.

When a strain shows the typical lancet-shaped *Diplococci* in a secretion or blood-film preparation, the fact that it grows in the form of chains does not affect the diagnosis of *Pneumococcus*. The most certain test is the inoculation of an animal, and finding in its blood the typical *Pneumococci*. Pathogenicity for mice is not a certain test, as it occasionally occurs in *Streptococci*.

When we have growth occurring on gelatine at room temperature, it will generally indicate a *Streptococcus*, but there are *Streptococci* which will not grow thus. It is only very rarely that *Pneumococcus* strains become adapted to growth at room temperature. Human serum not heated is almost always coagulated by the action of *Pneumococcus*.

Pneumococci in bouillon are dissolved by the addition of a few drops of taurocholate of soda; the liquid becomes clear. *Streptococci*, on the other hand, are not affected by it. This was first discovered by Neufeld, and has since been confirmed in my laboratory by Weekers. The method of differentiation by means of the fermentation of various sugar media (dextrose, maltose, lactose, saccharose, mannite, dextrine) is not absolutely certain.

Norris, Charles, and Papenheimer[2] state that fermentation of His'

[1] *K. M. f. A.*, 1907. For 'Metastatic Ophthalmia from *Streptococcus mucosus*,' see Pagenstecher, *K. M. f. A.*, 1906, ii.

[2] Jour. of Exper. Med., 1905, vol. vii., No. 5.

inulin-water (1 part 1 per cent. inulin-serum and 3 parts water) only occurs with *Pneumococci;* there are, however, *Diplococci* without capsules, with a tendency to the formation of chains, which can ferment inulin.

Many agree with Schottmüller that growth on blood-agar is decisive. On this medium the pneumococcal colonies are surrounded by a greenish area, while around *Streptococcus pyogenes* a clear area (hæmolysis) occurs.

In ophthalmic practice we generally examine a smear preparation, and the difficulties which we have mentioned rarely come into the question, unless, perchance, we have to deal with a mixture of *Streptococcus* and *Pneumococcus.*

The agglutination test does not furnish a specific differentiation between *Pneumococci* and *Streptococci,* for the individual strains of *Pneumococci* present considerable differences in this respect, and by no means always agglutinate each other. Fränkel and Kindborg[1] state that agglutination is only specific for the particular strain from which the serum has been derived. Although K. Scholtz did not find a very rigid specific difference for *Pneumococci* from ulcera serpentia, still he did find strains which either failed to agglutinate others or did so only very slightly. Experiments with active and passive immunity show similar results.

The virulence of *Pneumococci* is very inconstant[2] (*vide supra*). In cultures obtained from the eye it is, on the average, less than in those from sputum, and even in the first generation a fatal inoculation cannot be made on rabbits. The infected condensed water of a fresh culture (naturally a pure culture) appears to have the highest virulence. By passage through a mouse most strains can be exalted, though by this means they lose their pathogenicity for man (an important consideration in the preparation of sera).

Cultures of high virulence inoculated into rabbits and mice produce a rapid septicæmia, even when inoculated into the eye. Less virulent strains produce local suppuration. A typical ulcus serpens, by the inoculation of a corneal pocket, could only be produced in apes (Römer), not in any other animal.

LITERATURE.[3]

ADLER-WEICHSELBAUM, Das österreichische Sanitätswesen, 1897, Nr. 20.
VON AMMON, Münch. med. Wochenschr., 1900, Bd. 1, S. 12.

[1] Inaug. Diss., Halle, 1905, and *Zeit. f. Hyg. u. Inf.*
[2] Römer, Rep. Heidel. Conf., 1907.
[3] *Cf.* the general literature on 'Conjunctivitis,' p. 118.

AXENFELD, Vortrag im ärztl. Verein Marburg, 1895 (Berliner klin. Wochensch., 1896, Nr. 6); Verhandlungen der ophth. Gesellsch. Heidelberg, 1898; Deutsche med. Wochenschr., 1898, Nr. 1.
BACH and NEUMANN, l. c.
BAENZIGER et SILBERSCHMIDT, Epidémie familiale de conjonctivite à pneumocoque. Ann. d'ocul., 1903, T. 130, p. 376.
BRECHT, Charité-Annalen, 1899, Bd. 24.
BUTLER, R. L. O. H. Rep., 1907, XVII, p. 115.
CONSALVO, Gazette degli ospedali e delle cliniche. Milano, vol. 21, Nr. 117, p. 121.
COPPEZ, Verhandlungen des IX. internat. ophth. Kongresses in Utrecht, 1899, S. 71.
CORSINI, Arch. di Ottalm., 1902, X, p. 17.
CUÉNOD, Comptes rendus du congrès français d'ophth., 1895, p. 534.
DEMIVILLE, Rev. Med., 1907, 1.
DENIG, Zeitschr. f. A., 1900, S. 213.
DUANE and HASTINGS, l. c.
EVANS, l. c.
FERRI, Ann. d'ottalm., *1896, t. 25, p. 472.*
FRUGINELLI, *Gazetta internationale di medicina pratica, vol. 3, p. 286 (Lid-abscess).*
GASPARRINI, Ann. d'ottalm., *1893*, vol. 22, *6.—Ibid., Atti della R. Accademia dei* fisiocritici di Siena, *1894*, vol. *5.—Ibid.*, Ann. d'ottalm., *1896, t. 25, Fall 1.*
GIARRÉ and PICCHI, La settimama med., *1901*, Nr. 8.
GIFFORD, Arch. of ophth., 1896, vol. 25, p. 314.
GONIN, Revue méd. de la Suisse Romande, February and March, 1899.
GROENOUW, A. f. O., 1900, Bd. 50.
GUIGNOT, Pneumococces oculaires. Thèse de Bordeaux, 1904.
HALLÉ, Ann. d'ocul., 1900, t. 123, p. 200.
HAUENSCHILD, Z. f. A., 1900, Bd. 3, Nr. 1.
HERTEL, A. f. O., 1902, Bd. 53, 3, S. 502.
HIROTA, Inaug. Diss., Halle, 1901.
JUNIUS, Z. f. A., 1899, Bd. 1, S. 43.
KIBBE, A. f. A., 1899, Bd. 38, S. 273.
LAWSON, B. M. J., June 18, 1898.
LUNDSGAARD, Inaug. Dissert., Kopenhagen, 1900, S. 17.
MORAX, Recherches bacter. sur l'étiol. des conjonctivites aiguës. Thèse de Paris, 1894. Maladies de la conjonctive. Encyclopédie d'ophth., 1905, Bd. 5.
MORAX et PETIT, Ann. d'ocul., September, 1898.
NICOLAS, Thèse de Paris, 1901.
NOELDEKE, E., Inaug.-Dissert., Strassburg, 1899.
OERTZEN, K. M. f. A., 1899, and Inaug. Dissert., Rostock.
PARINAUD, Ann. d'ocul., December, 1894.
PETIT, Ann. d'ocul., 1901, t. 126, p. 186.
PICHLER, Beitr. z. A., 1896, Bd. 24, S. 19.
POLLOCK, l. c.
RÖMER, A. f. O., 1903, A. f. A., 1905.
RUPPRECHT, *Streptococcus mucosus.* K. M. f. A., September, 1907.
RYMOWITSCH, Russki Wratsch, 1902, Nr. 33, p. 177 (Ref. Ophth. Klinik, 1903, 1).
SAEMISCH, 2 Aufl. des Handbuches, 'Bindehauterkrankungen,' 1905, S. 47.
SCHOLZ, A. f. A., 1906.
STSCHEGOLEW, Med. Obosrenije, 1900, vol. 54, p. 559 (Ref. Michel-Nagel).
UHTHOFF and AXENFELD, A. f. O., 1896, Bd. 42.
USHER and FRASER, l. c.
VEASY, Arch. of Ophth., vol. 28, 3-5.
VEASY and DE SCHWEINITZ, Ophth. Review, 1899, p. 354.

SECTION 4.—PSEUDO-MEMBRANOUS CONJUNCTIVITIS. DIPHTHERIA BACILLI AND THE SO-CALLED XEROSE BACILLI. STREPTOCOCCI. VARIOUS ORGANISMS.

Recent researches unanimously show that the bacterial findings vary with the varying intensity of pseudo-membranous conjunctivitis. The formation of a pseudo-membrane is a symptom occurring in various forms of infection, though it must be admitted to especially indicate the presence of either Löffler's diphtheria bacillus or the *Streptococcus pyogenes*. The variations of the clinical appearances in relation to bacteriological findings are fully set out in the monograph by Coppez. As the result of experiments and microscopical examinations, Sourdille states that the same chemical agent can produce any degree of reaction, from a slight catarrh to a croupous membrane with severe diphtheritic necrosis, according to its amount, concentration, and time of action.

The presence of diphtheria bacilli or *Streptococci* is always suggested in slight cases of croupous conjunctivitis, as well as in those severe forms which clinically have that peculiar diphtheritic appearance. Croupous conjunctivitis can be quite well distinguished clinically from diphtheritic conjunctivitis (Saemisch, Zur Nedden, Christ); etiologically, however, this distinction does not hold good. The clinical diagnosis, therefore, requires amplification by examination of the secretion.

A clinically mild croupous conjunctivitis can be associated with the presence of virulent Löffler's bacilli. This has been definitely established by the important works of Sourdille, Fränkel, and Uhthoff, as well as by the less well-known previous works of Gallaemerts (1891) and Deyl (1892), and has been since confirmed on all sides (Schirmer, Vossius, Coppez, Gosseti-Jona, Jessop, Sidney Stephenson, etc.).[1]

The differential diagnosis of the diphtheria bacillus and its relation to the so-called *Bacillus xerosis* requires further statement.

Löffler's Diphtheria Bacillus (Corynebacterium Diphtheriæ Lehmann-Neumann).

(See PLATE A, FIG. *V.*, *a* and *b*.)

Morphology.—Rods of variable length, 1·5 to 8 μ and over, of an average breadth of 0·5 to 1 μ; sometimes also intermediate forms, which are spindle or lancet shaped, the smallest forms often pointed at one or at both ends, the longest ones

[1] Full statistics in Axenfeld, 'Bakt. des Aug.'; Lubarsch-Ostertag, 'Ergebnisse,' 1894-1900.

FIG. 37.—DIPHTHERIA BACILLI[1] TWENTY-FOUR-HOUR SERUM CULTURE. × 1,000.

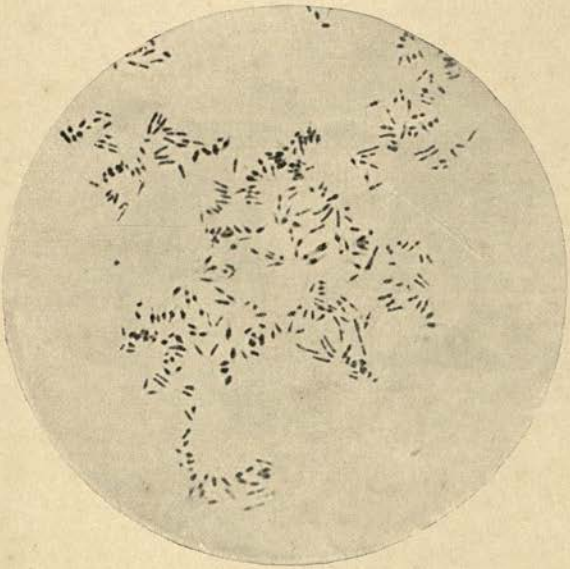

FIG. 38.—DIPHTHERIA BACILLI[1] TWENTY-FOUR HOUR BOUILLON CULTURE. × 1,000.

[1] Beck, Kolle-Wass., 'Handbuch,' Bd. ii., pp. 775, 777.

more often with club-shaped ends. This thickening at the ends in the form of a club is very characteristic, and is especially well seen in cultures. The rods are often curved, especially the longer ones. The bacilli are generally arranged parallel to each other, clustered in a radial manner so as to form irregular rosettes, or else crossed. Their form and size varies, and a differentiation of the organisms according to their length ('bacilles longs,' 'bacilles courts'), and thus an estimation of their virulence cannot always be carried out.

The same strain can vary in form, according to the medium and the length of time it has been cultivated. In culture long threads may form, often with club-shaped ends; these may stain segmentally, and so resemble chains of cocci. Many strains, especially when grown on egg media, show definite branching (Fränkel). These branching bacilli may resemble *Actinomyces*. (It was the occurrence of this branching which suggested the name of 'corynebacterium.' Lehmann and Neumann bring the glanders bacillus and the bacilli of the diphtheria group together under this name). Del Monte considered that the bacilli of this group belonged to the group of the *Streptothrix*.

In a preparation from the secretion of a diphtheritic conjunctivitis variations in the form of the bacilli are of some diagnostic value. Cases do occur in which the slender forms, with swollen ends arranged parallel or in V-form, so predominate that the experienced observer, when polar staining occurs, can give a probable diagnosis of 'true diphtheria' from the smear alone, as the non-virulent *Bacillus xerosis* does not occur in this form. In this connexion it may be of interest to compare Fig. *IV.* on Plate I., which is drawn from a true diphtheria of the conjunctiva (proved by inoculation), with the five drawings of the *Bacillus xerosis* in secretion, which are to be found on Plate I., Fig. *I.*; Plate II., Figs, *III.* and *V. b*; also pp. 7 and 14.

In other cases, as shown by the figures in the text, the form may so vary in one and the same preparation that from a mere examination of a slide it is impossible to make even a probable diagnosis between *Bac. diphtheriæ* and *Bac. xerosis*. In the former, according to my opinion, the slender forms are never entirely absent, though the larger irregular ones may preponderate. Fig. *VI. a* on Plate I. is drawn from a case of true diphtheria of the conjunctiva, though it could equally well represent a secretion with the xerose bacilli. Inoculation alone can decide the question. Morax definitely claims that it is possible to diagnose the *Bacillus diphtheriæ* from the smear preparation. It is certainly true that the expert is often right in the cases mentioned, but in other cases the actual form of the bacilli is not diagnostic, and is never an absolutely certain criterion.

Cultures.—The diphtheria bacilli grow best aerobically. Growth occurs between the temperatures of 20° C. and 40° C.; best from 33° C. to 37° C.

Löffler's *blood-serum* and *ascites agar* are the best media.

On *gelatine* growth is scanty and not characteristic.

White or yellow glistening colonies grow on *glycerine agar;* they vary in size, are transparent, circular with ragged edges, and coarsely granular; they are brownish and darker in their centres. Old colonies become crumbly, opaque, and show darker patches in their interior. Other colonies from the first appear denser and more finely granulated, especially when they are grown on ascites agar. In exceptional instances they may develop other colours.

On Löffler's *blood-serum* development is more vigorous than on agar.

In *bouillon* a fine dusty deposit occurs at the bottom and sides of the tube, or else a fine flocculent mass at the bottom. On the surface a fine skin of variable thickness forms. The bouillon becomes acid and after a few days again alkaline.

In *milk* growth is free, usually without coagulation, and with an amphoteric reaction.

On *alkaline potatoes* a thin shining film develops; it is rarely thick.

When kept cool and in the dark, or hermetically sealed in an incubator, diphtheria bacilli retain their vitality for many months; they have considerable powers of resistance against dryness and cold. Moist heat, on the contrary, kills them at 60° C. very rapidly.

The development of acidity in bouillon is best demonstrated by titration with 1 in 40 normal caustic soda (phenolphthalein as indicator); it especially occurs in sugar bouillon. For cultures in 1 per cent. sugar bouillon twenty hours old Lehmann and Neumann used 3 c.cm. caustic soda; forty hours old, about 6 c.cm.; and for cultures in bouillon without sugar about half these amounts.

The passage of toxin out of the bacilli into the bouillon only begins with the cessation of acid formation. Old cultures, therefore, after filtration show typical toxic activity; fresh twenty-four-hour cultures do not, unless containing the bacilli.

Staining Reactions.—The diphtheria bacilli stain very intensely by Gram's method. It has been stated that old degenerate bacilli lose their colour. This has no practical importance in diagnosis, and when examining fresh cultures we can, with absolute certainty, rely on obtaining an intense colour with Gram's stain. I must again emphasize the fact that an even staining with this method can only be guaranteed when the material has been evenly spread out. In places where clusters of bacilli lie in dense masses of secretion the deeply-placed bacilli are often unstained (the same is true for xerose bacilli).

Intensely stained with Gram, the young small bacilli appear of an even colour; in the older and longer forms a more intense staining occurs at the poles. Segmentation, or granule formation, occurs in the large club-shaped masses, and narrow stained sections alternate with clear intervals (zebra staining). This segmentation is much more obvious in cultures and with Löffler's methylene blue or Roux's mixed stain (see p. 17). The Babes-Ernest bodies, segments, or polar bodies then appear blue or violet; when Löffler's method is used the intervals are either light blue or unstained, and when Roux's is used they are light green. The long rods or threads, especially obvious in involution forms, may be taken on superficial examination to resemble *Streptococci*.

The granules are first formed at the poles, and are most clearly seen in that situation; they are best displayed by M. Neisser's stain (acetic methylene blue and Bismarck brown). A preparation is to be considered as positive and absolutely diagnostic when the bacilli have the typical slender form, are arranged in the characteristic manner, and at the ends of their yellowish-brown bodies—occasionally, too, in their intermediate parts—show dark blue granules; not merely here and there, but in every example.

In secretion preparations this method may give very good results, and in such cases a probable diagnosis of diphtheria is justifiable. On the other hand, a negative result with Neisser's stain in a secretion preparation is of no value in the opposite sense.

According to M. Neisser, the following conditions are necessary for the diagnostic value of this method: the cultures must be fresh, of the first generation, and grown on good Löffler's serum at a temperature of 34° to 36° C. Cultures which in nine to twenty hours show the typical staining and typical form were considered by him to be true diphtheria. Older generations, after longer propagation, do not conform to this rule. It is important to have a good Löffler's serum, and to make certain that this is the case every new batch of tubes should be tested with an inoculation of true diphtheria.

Pseudo-Diphtheria Bacilli.

Besides the toxic diphtheria bacilli, we find on various mucous membranes, both in a state of health and of disease, rod-shaped organisms, which are more or less

nearly related to the true diphtheria bacilli, and often cannot be distinguished from them, only they have no toxic power. These organisms have given rise to the term ' pseudo-diphtheria bacilli.'

The type which was first described under this name by Hofmann and Löffler, and for which we now generally reserve the title ' pseudo-diphtheria bacillus,' is a Gram-positive bacillus, which grows somewhat thicker and shorter on serum, and has very slight tendency to the formation of club-shaped bodies or to segmental staining. The rods tend to lie parallel to each other. On blood-serum, and still more on agar, it grows much more vigorously than the diphtheria bacillus.

Growth rapidly spreads over the surface of the media in the form of a thick greyish-white scum. Later the agar often becomes brown. Growth is more vigorous on potatoes, where a dry, uneven scum forms. A dense diffuse opacity develops in bouillon, and in a few days a deposit, much more profuse and thick than



FIG. 39.—VARIATIONS IN SHAPE AND FORM OF THE BACILLUS XEROSIS IN CULTURE.

1-6, Stained with Löffler's methylene blue; 7-9, M. Neisser's granular staining of blood-serum cultures nine to sixteen hours old; 7, virulent diphtheria bacilli (typical granular staining); 8, xerose bacilli quite unstained; 9, xerose bacilli imperfectly stained (Heinersdorff).

that formed by the diphtheria bacillus. In ordinary bouillon there is either no acid formed, or else so little that the reaction remains alkaline as a rule; on the second day the alkalinity increases (with the diphtheria bacillus the media become strongly acid). In sugar bouillon the acid formation is much less. On gelatine at 18° C. free growth takes place without liquefaction. Neisser's granules either do not stain at all in blood-serum cultures of nine to twenty hours, or do not do so in a typical manner.

This bacillus is quite avirulent for guinea-pigs. (Hawlett and Knight claim to have transformed this organism, by passage through animals, into virulent diphtheria bacilli, and also report that, by careful warming, they have produced the Hofmann-Löffler bacillus out of the virulent diphtheria bacillus. Unfortunately, they did not test whether diphtheria antitoxin influenced the action of the organisms after they had become virulent.)

As a matter of fact, bacilli showing the characteristics just mentioned are so far

removed from the type of the Löffler's diphtheria bacillus that they can at once be differentiated from it.

These forms are often found in the mouth, the throat, and the nose. On the conjunctiva they are not so common.

On the conjunctiva another type of avirulent bacillus is much more commonly found. It is very similar in appearance to the true diphtheria bacillus, many strains being identical, though in secretion preparations and in young cultures short, thick forms are more commonly seen. Cultures on blood-serum are more scanty than those of the true diphtheria bacillus; the individual colonies are often very dry, and adhere so closely to the medium that they cannot be washed away completely. In other strains this is possible. Cultures from a hyperæmic conjunctiva are generally more vigorous than those from the normal conjunctiva. In cultures from many normal conjunctivæ the colonies only begin to appear after several days.

On agar the colonies from the normal conjunctiva as a rule are scanty and dry. Their margins are serrated; like those of the true diphtheria bacilli, under a magnification of 60 the colonies appear freely granular. They vary greatly in size: many strains, when grown on agar, do not form colonies larger than the head of a pin; others are slightly larger. They never approach the colonies of the Hofmann-Löffler bacillus in size. This type of non-virulent bacillus, with its scanty growth, presents features which are quite the opposite of those of the Hofmann-Löffler organism. Lehmann and Neumann and others have given it the name *Bacillus xerosis*, and Heinersdorff recommends the name *Bacillus vulgaris pseudo-diphthericus conjunctivæ*, because he found it the most common inhabitant in the conjunctiva. Undoubtedly numerous strains of both types have been observed, which have retained their peculiarities under varying conditions and after long cultivation, or, at most, have lost them to a very slight extent. I once cultivated a series of thirty strains of the *Bacillus xerosis* type for a long time without finding any appreciable change. Such strains must at least be classed as a variety.

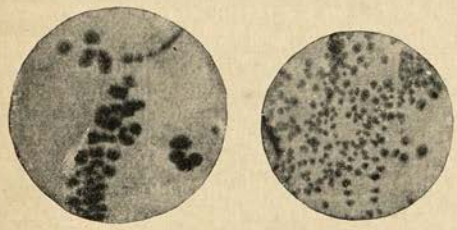

FIG. 40.—XEROSIS COLONIES.

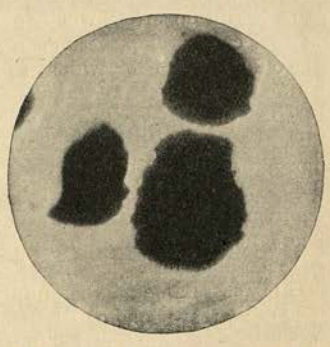

FIG. 41.—HOFMANN-LÖFFLER VARIETY.

Figs. 40 and 41 are of the same magnification.

As an illustration of these different peculiarities, colonies of the same age (five days) and at the same magnification have been photographed: (*a*) from two strains of poorly growing xerosis; (*b*) from the Hofmann type. All three were obtained from the conjunctiva.

The growth in bouillon so far resembles that of the diphtheria bacillus in that the bouillon usually remains clear, while small punctate deposits occur on the sides and bottom of the tube; these can be shaken up, but soon sink again. The most sparsely growing strains grow less freely than the diphtheria bacillus. The reaction of the *B. xerosis* generally is not acid.

On *gelatine* at 18° C. growth almost never occurs; at the very most, we may find here and there the scantiest traces along the needle track.

There is no general pathogenicity for guinea-pigs, even when large doses are injected subcutaneously. A few authors (Spronk, C. Fränkel, and Pes) have obtained transient swelling at the site of inoculation. C. Fränkel states that many of the animals died later from marasmus. In conjunction with many of my students (*cf.* papers by Heinersdorff, Bietti, Plaut, and Zelewski), I have performed many inoculations without being convinced that such was the case, unless enormous doses were employed. These changes and the local reaction to inoculation in the eye have nothing to do with diphtheria toxic action.

There can be no doubt that the two varieties do exist, for the description first given by Hofmann, and since then found applicable to the great majority of the avirulent 'pseudo-diphtheria' organisms which occur in the throat, is not applicable to the majority of the conjunctival xerose bacilli.

That the great majority—if not, indeed, all—of these organisms show marked differences in their power of growth when they come from the two chief sites where they exist (the eye when they grow sparsely, and the throat when they grow freely), appears worthy of note.

It is still uncertain whether the special nutritive conditions present in particular persons can develop these differences, or whether one variety flourishes better than the other in some individuals. According to the researches of Veillon, both forms are to be found in the genital tracts in women.

These differences are very clearly pointed out in the recent works by Schwoner, Gromakowski, Lewandowski, and Tertsch. Quite in accord with my own observations, they divide the diphtheria organisms into two groups: (*a*) growing sparsely; (*b*) growing profusely. Tertsch agrees with Schwoner in calling the profuse group Hofmann's bacilli; the sparsely growing group, on the other hand, seeing that they more nearly resemble in their cultures the true diphtheria bacilli, they term 'pseudo-diphtheria' bacilli. I cannot entirely support this idea, as the custom is to use this last name for the Hofmann bacillus, as, for example, in Lehmann-Neumann and other text-books of bacteriology. It will, perhaps, be sufficient if we contrast the profuse (Hofmann's) with the sparse type.

The exact differentiation of the varieties which we have described, as also that of the pseudo from the true diphtheria bacilli, is often complicated by the occurrence of variable strains. Some of these strains resemble each other in one particular or another, and others seem to conform to the type of the true diphtheria bacillus. Further subdivision according to such criteria would be quite artificial, and Lehmann and Neumann are correct in stating that the subdivision into three classes of pseudo-diphtheria bacillus, as, *e.g.*, by Gromakowski, cannot be carried through.

A classification has been attempted on the basis of agglutination (Nicolas, Nicolle, Landsteiner, Lesieur, Bruno, Lubowski, C. Fränkel, and Schabad). With such a non-motile organism, with a tendency to the formation of a scum in the culture, the determination of agglutination would be difficult, and the results obtained did not agree.

Nicolas, using the serum of convalescent diphtheria patients, succeeded in agglutinating virulent strains in a 1 in 10 dilution, and avirulent in 1 in 20; but he also found true virulent strains which were not thus agglutinated.

Bruno obtained agglutination with the serum of diphtheritic patients up to 1 in 400, but normal serum had the same result up to 1 in 30. With a serum obtained by the action of an atoxic diphtheria strain Lubowski was able to agglutinate twenty-three virulent and two avirulent diphtheria strains (dilution 1 in 40 and 1 in 80), while pseudo-diphtheria strains did not react. Lesieur, on the

other hand, with antitoxic serum was able to agglutinate both true diphtheria strains and also pseudo forms.

The experiments were not conclusive, for a concentrated solution of a serum of a definite Bacterium is able to agglutinate Bacteria which are allied to it (*e.g.*, typhoid serum agglutinates *B. coli*, and the Gram-negative cocci interact). We can only use highly diluted sera, therefore, for the differentiation of allied strains, and such dilution can only be made with sera of high valency. Schwoner was able to produce a very active serum from horses by treating them first with dead and then with virulent diphtheria bacilli. This serum agglutinated the true diphtheria bacilli in a dilution of 1 in 10,000. In such a dilution pseudo-diphtheri bacilli did not agglutinate.

With a serum of this type, the agglutinating power of which for true diphtheria was 1 in 5,000, Tertsch tested thirty-two strains obtained from the conjunctiva (twenty-three from normal, five from catarrh, and four from xerosis). As many strains will of themselves settle down, the bouillon in which the organisms are must be carefully shaken, the serum added, and then the action observed for forty-eight hours. The organisms from two forty-eight-hour-old blood-serum cultures are rubbed up with bouillon in a mortar, and shaken till the organisms are in suspension; equal parts of the fluid and a 1 in 5,000 dilution of the serum are mixed. Six strains from the normal conjunctiva were agglutinated; all others were not. These six strains were quite avirulent for animals, two of them alone merely causing a local infiltration. Tertsch considered these six strains as true, though avirulent, diphtheria organisms. Morphologically, they could not be distinguished from the others; their growth on agar was similar to that of diphtheria. Four of the strains which were agglutinable gave positive pole-staining with Neisser's method, one of them a negative result, and the other a variable one; all the strains which did not agglutinate were negative. All the agglutinating strains produced an acid reaction in bouillon; the non-agglutinating did not. Some of the latter increased the alkalinity; others did not affect it.

Bacilli also were found which were not pathogenic, but still were able to produce an acidity in bouillon. From this we must conclude either that acid formation is not a constant point of differentiation between the true and the pseudo bacilli (calling the avirulent strains 'pseudo'), or that those avirulent bacilli which develop acidity are not pseudo-bacilli, but are true diphtheria bacilli which have become avirulent. There are even strains which are avirulent, form acid, do not stain by Neisser method, and do not agglutinate, and yet do produce a small amount of acid (Lehmann and Neumann). *The development of acidity and the agglutination tests are, therefore, not absolute points of differentiation.*

A. Knapp (who agrees with Axenfeld in recognizing several varieties of these non-pathogenic bacilli) compared the fermentative, or rather the acid-forming, power of twenty-seven virulent diphtheria bacilli, ten xerose, and four pseudo-diphtheria bacilli with respect to serum-water, to which had been added dextrose, mannite, maltose, lactose, saccharose, and dextrine (1 per cent. of each—His). diphtheria and xerose ferment dextrose, mannite, and maltose in the same way, with acid-formation and coagulation. On the other hand, diphtheria alone ferments dextrine, xerose alone saccharose. Pseudo-diphtheria bacilli do not cause fermentation, and form no acid.

The essential point in the whole question is toxic activity, as shown on the one hand by the production of infection and on the other by the effect of the curative serum. There is no doubt that virulence is no constant attribute of the bacteria, for not only can it vary in intensity, but it can be lost and regained. The occurrence, therefore, of avirulent diphtheria bacilli is obvious and well established. Löffler is right in insisting, before an identity can be established, that the organisms in question must be similarly capable of producing a specific characteristic toxin

which can be demonstrated. Are we justified in assuming that this function is latent in the conjunctival xerose bacilli?

There are records of a virulent bacilli having been made virulent in other parts of the body. Trumpp did this in the case of a bacillus from pleuritic pus by mixing it with diphtheria toxin; he then obtained full virulence. We know that Roux and Yersin exalted a diphtheria strain by inoculating it along with *Streptococci*. Trumpp's results are not yet confirmed, and such a record cannot be taken as decisive, seeing that the organisms in question, though formerly virulent, were then avirulent, and they were merely again acquiring their virulence, and this cannot be taken as applying to the *B. xerosis*, which may never have been virulent.

The symbiosis recorded by Roux and Yersin rather opposes the idea that the *B. xerosis* can develop virulence, as these two organisms (*B. xerosis* and *Streptococcus*) are occasionally observed together on the conjunctiva without any such development of virulence. Escherich, however, never succeeded in developing virulence in pseudo-diphtheria bacilli by inoculating them with *Streptococci*. It is interesting to note that Gelpke made the same experiments without obtaining any results.

Doetsch found a *B. xerosis* which was pathogenic for mice, and its virulence increased by passage through the animal and further cultivation.

Such isolated records prove nothing. And it should be noted that pathogenicity for mice is not identical with the production of true diphtheria toxin; neither has it been shown that the animals died in the typical way, nor were immunizing experiments with antitoxin carried out.

Nor can we consider the observations of C. Fränkel, Peters, and Schanz of any greater importance. They report that a long time after the injection of very large doses the animals died. This need not indicate a diphtheritic virulence in the *B. xerosis*. Such, indeed, is not death from diphtheria. Antitoxin does not prevent such results (Spronk). In conjunction with Bietti and Naito, and working with large doses of 120 different strains, I only once had a fatal result, though that, indeed, was a rapid death, as in diphtheria. In this case we had to do with the rare but still well-known occurrence of a virulent diphtheria strain upon the healthy conjunctiva.

De Simon's experiments, in which he obtained a virulent organism from a so-called pseudo-diphtheria bacillus by growing it on tetanus media, is not a proof beyond the possibility of error.

Schanz contrasts the clinical facts that in mild conjunctival catarrh virulent diphtheria bacilli can be found, and in pseudo-membranous conjunctivitis avirulent bacilli are often seen. This is very strong evidence against the pathogenicity of the diphtheria bacilli, but shows that membranes, etc., are good media for the growth of such organisms.

That virulent bacilli are occasionally found upon the conjunctiva when it is only slightly inflamed (Wagner, A. v. Hippel, Fränkel, Pes, Sourdille), and even when healthy (Pilcher, McKee), is not incompatible with their pathogenicity. (Infection with a virulent strain of a pathogenic Bacterium does not necessarily produce the disease in every case, and when the disease does occur we find slight and severe cases, depending on the susceptibility of the individual.

Further comprehensive series of experiments are necessary to prove whether there is any capacity in the xerose bacilli of developing into virulent diphtheria organisms.

Every attempt to immunize susceptible animals against the poison of diphtheria by means of the *B. xerosis* has so far failed. Gelpke, and also Bietti,[1] have made

[1] Duane and Hastings are in error in their opposition to Bietti (*loc. cit.*), on the ground of his ascribing too great an importance to the *Bacillus xerosis* in the etiology of conjunctivitis. Bietti is much more inclined to the opposite view.

such experiments in large series. Treatment for weeks and months with increasing, and finally enormous, doses of xerose bacilli gave no protection against death from diphtheria, but rather accelerated a fatal termination. The results obtained by M. Neisser, Petrie,[1] Lewandowski,[2] and others were similar.

Certain experiments in serum therapeutics have been made lately in the Freiburg clinic with reference to the *B. xerosis*.

Behring holds the view that these bacilli under favourable conditions can pass into the virulent form and produce all grades of toxic action, even mild atypical affections, which he calls 'diphtheroid,' from which greater or less immunity may result in the body.

This would certainly explain the fact, established by Wassermann, that the serum of adults, even when they have not suffered from any demonstrable diphtheria, always shows a definite action against the diphtheria antitoxin.

With relation to these diphtheroid conditions, Gelpke and Pes take the view that they are very common on the conjunctiva, and that the great majority of the simple catarrhal inflammations, especially the epidemic forms, are really attenuated diphtheria. They claim that this can be inferred from the fact that, when the bacilli are cultivated and inoculated under the conjunctiva, a slight local inflammation (œdema) results, which will more rapidly disappear under the influence of diphtheria serum.

With such bacilli obtained from cases of simple catarrh Gelpke sometimes obtained a slight inoculation conjunctivitis in man. The patients affected had previously suffered from scrofulous inflammation of the conjunctiva, slight increase of which did not represent an acute catarrh. Del Monte, with three such strains, obtained a slight traumatic conjunctivitis after superficially wounding the conjunctiva. This, however, does not prove a diphtheritic action, especially as control injuries without an inoculation and inoculations on diphtheria-immunized animals were not carried out. Large numbers of experiments carried out at my instigation by Bietti and Naito[3] have not confirmed this view of simple catarrh. In a hundred cases there was only one showing diphtheria bacilli, so that we must admit that the hypothesis of Pes is not generally true. Gromakowski's results were quite similar: in sixty strains, mostly obtained from catarrh of the conjunctiva, no pathogenicity for animals could be established. In my experience diphtheroid affections in this sense are very rare on the conjunctiva. Behring's serum treatment does not apply to simple catarrh nor to epidemic conjunctivitis.

As we have already said, many diseases have been ascribed to the *Bacillus xerosis*, and some of those who are in favour of the identity of the organisms, especially Deyl and Hala,[4] see in this an evidence that the *B. xerosis* has the power to produce disease, and that it may be looked on as an intermediate form towards virulent diphtheria bacillus. The presence of the *B. xerosis* in (1) chalazion, (2) in the interior of the eye in experimental injection, in wound infection, and also exceptionally in metastatic infected eyes,[5] comprises the evidence available.

The statement that the *Bacillus xerosis* is the cause of chalazia, those infectious tumours inside the tarsus, is based by Deyl on the fact that he found this bacillus regularly in the very first stages of the chalazia, and by injecting a thick suspension of a culture under the skin of rabbits he was able to produce small nodules which consisted of granulation tissue. When the bacilli were injected into the vitreous, a marked inflammation resulted. These inoculation results were first given

[1] Jour. of Hyg., 1905, v. 134.
[2] *Zent. f. Bakt.*, 1904, xxxvi. 336, etc.
[3] *K. M. f. A.*, 1903, 'Festsch. für Manz.'
[4] *Z. f. A.*, 1901, vi.; 1903, ix. 107 (see here the literature).
[5] *Cf.* the work of Demaria in my clinic, 'Endogenous Mixed Infection of Tubercle Bacilli and Pseudo-diphtheria Bacilli.' 'Panophthalmitis Tuberculosa,' *K. M. f. A.*, 1905, xliii., Bd. ii., Beilageheft.

by Deyl, and afterwards confirmed by Hala and Bietti, and are of interest, because Hala, the pupil of Deyl, considered this inflammatory reaction as a proof of the identity of these bacilli with the diphtheria bacilli. The production of chalazia would then be considered as a lower grade of pathogenic activity in a diphtheria bacillus. In considering this question, it is of interest to decide whether diphtheria toxin plays any part in the production of these nodes, and whether they are influenced in any way by the action of the antitoxin. In my laboratory Bietti[1] repeated the experiments of Deyl with bacilli which were obtained from chalazia, and with other xerosis strains; the inoculations were made on animals which were previously immunized to a high degree against diphtheria by means of Behring's serum. The results of inoculation, both in the vitreous and in the subcutaneous tissues, were the same as in the non-immunized animals. As we were not certain whether, in the case of immunized animals, the antitoxin passed into the vitreous, we mixed the bacilli with the serum before they were injected. Römer's[2] experiments show that any diphtheria toxin previously present in the interior of the eye would be neutralized by such a mixture.

Even when antitoxic serum was directly added to the bacterial suspension before the injection, no variation occurred either in the vitreous or in the subcutaneous tissues. It is therefore clear that the diphtheria toxin takes no part in the action, and it is very doubtful whether the occurrence of such a local inflammation proves anything in the way of an identity, as claimed, with the diphtheria bacillus. The same is true for those local inflammations in the cornea and in the anterior chamber which Gourfein and Doret produced by the introduction of large doses of bacilli which they had obtained from cases of catarrhal conjunctivitis. These authors state that bacilli from the normal conjunctiva did not give this reaction, and that an increase in the pathogenic activity took place on the conjunctiva when in a condition of catarrh. That may be so; I myself have often noticed that bacilli from an inflamed conjunctiva grow more freely. These local reactions to inoculation, however, must not be taken as a proof of the presence of diphtheria toxin.

It must be quite obvious that, from the point of view of clinical therapeutics, we can expect nothing from the treatment of chalazia with Behring's serum. The advocates of identity can test their position by this means on any chronic and recurring cases.

[Wassermann has proved that a bactericidal serum can be obtained with bacilli whose toxin has been made inactive. Experiments are already being made by this means to settle the much discussed question of the pseudo-diphtheria bacilli. Further experiments must be carried out to see whether by this means the infection of the so-called chalazion bacillus can be influenced.]

Bietti's experiments show that this production of chalazia has probably nothing to do with specific influences; he was able by injecting other saprophytes (*Sarcina aurantiaca*, *Rosa hefa*, *Prodigiosus*, and the so-called *Pseudogonococcus*), which he used in large numbers, to obtain the same results.

Vitreous injections have the same result. In the dissertation of Vogel I have arranged a number of experiments to show whether the inflammatory reaction, after the injection of xerose bacilli, was influenced by a previous immunizing against diphtheria, or (what would be even more decisive) by a previous admixture of Behring's serum. This was in no wise the case; the changes were quite the same in the animals treated with serum.

These last experiments have a further interest. There are in the literature a few cases of severe intra-ocular inflammation after operations or wounds (Kastalska, De Schweinitz), and a few metastatic ones also, where, in the exudate, bacilli of the pseudo-diphtheria variety occurred, which, when grown in pure culture and injected

[1] *Arch. di Ottal.*, 1905, xii. 534. [2] *A. f. O.*, 1903, l. 1.

into the vitreous, again produced inflammation. Ulbrich[1] tested a large number of saprophytic Bacteria anew with reference to their power of inducing inflammation in the eye, and as a result of his researches, was of the opinion that post-operative infection due to such saprophytic organisms was much more frequent than had previously been thought; such cases clinically take the form, not so much of purulent panophthalmitis as of subacute or insidious inflammations. Further cases have been communicated by Gourfein and Welt, and among them one with bacilli of the xerosis variety. The course of such wound infections is somewhat different from that of Ulbrich's experiments, as it is necessary for the organism in question to multiply in the interior of the eye. In operation cases they will only do this to a very slight extent, so that they cannot induce an inflammatory reaction, or if they do, it can only be very slight. Seeing that the *Bacillus xerosis* in concentrated suspension, as a rule, dies out in the vitreous, the assumed capacity for propagation there is not always present, and I therefore think that these Bacteria rarely have anything to do with wound-infection. An experiment of Deyl[2] and those which Demaria[3] carried out in my clinic show that there are stems of *B. xerosis* which can propagate in the vitreous, which have a pathogenic action, and can remain a relatively long time there.

Here again the question arises, especially for those who favour the view of identity, whether anti-diphtheritic serum should not be used in these cases, on the chance at least that that particular bacillus is present. In my opinion such measures are quite aimless.

Even should proof be furnished of their complete identity, and the possibility thus approached that, without infection from outside, toxic diphtheria bacilli can develop and produce their results on the conjunctiva, our proceedings in bacteriological diagnosis would remain the same as they now are. Whether the *Bacillus xerosis* is to be identified with the *Bacillus diphtheriæ* (Roux, Schanz, Peters, Pes, Behring, Hala, and others), or to be considered merely as a kindred organism of the same group, as we find stated by the great majority of bacteriologists (*cf.* the text-books of Gunther, Heim, Neumann and Lehmann, the literature by Beck in the Kolle-Wassermann Handbook, and others), what we have to ascertain is, Are toxin-forming bacilli present? and when we find them, are we to consider them as wholly or only partially responsible for the inflammatory changes, and direct our therapeutic measures against them? Even then the fact would remain that the non-toxic bacilli of the normal or simple catarrhal conjunctiva are harmless in the cornea, and in wounds or injuries.

Our clinical bacteriological diagnosis and serum treatment, which we should certainly carry out in pseudo-membranous inflammations, briefly summed up, consists in the following measures:

Several slide or cover-glass preparations should be made of the

[1] *A. f. O.*, 1905, lix. 8. [2] 'Über die Ätiologie des Chalazions,' Prag, 1893.
[3] 'Mischinfektion von Tuberkulose- und Pseudodiphtheriebazillen im Auge,' *K. M. f. A.*, 1905, xliii., Beilageheft (*cf.* here the literature).

secretion or membrane, spread out as evenly as possible; these should be stained by Gram's method. If after careful search we find no bacilli of the diphtheria group, then the case is not one of diphtheria. Sufficient material[1] should always be taken, and the case must not have been treated.

If the rods described above are seen, we must examine them carefully with regard to their form and length (*cf.* p. 190). If Neisser's polar staining is found to be positive and typical, then toxic diphtheria bacilli are probably present. When the number of the bacilli and other organisms (especially *Staphylococci* and *Streptococci*) present is very great, we should rub some of the material on to three tubes or Petri dishes. I like to use as O agar as I and II serum, so that isolated serum colonies will certainly be obtained. When the cultures are made before midday, then in the evening, in ten to twelve hours, the colonies can be seen with the loupe, and from characteristic colonies smear preparations can be made, some stained with Neisser's polar stain and others with Gram. A positive result with Neisser's stain makes the diagnosis still more likely.

If isolated colonies occur on the original tube, then make a bouillon culture, into which the greatest possible number of colonies which can be macroscopically and microscopically determined to be characteristic are introduced into the same bouillon tube (10 c.cm.). I do this because we can very well have toxic and non-toxic bacilli occurring together (Schirmer). If we take only one colony and obtain no result, it cannot be concluded that all the other colonies would have been the same. On the other hand, by the use of ten to twenty colonies we are practically certain. Naturally we most carefully examine such a bouillon culture in twenty-four hours in hanging-drop and in stained smear, to make sure that only Bacteria of the diphtheria group are contained in it before using it for inoculation. We further test the bouillon for acidity.

If it be a pure culture, I inject 2 c.cm. of the culture subcutaneously into a guinea-pig. If death occurs in two to six days with the characteristic symptoms, then we have definitely a toxic organism present. The site of the injection is doughy, sometimes covered with a white material, and a section of the surrounding tissue is juicy and hæmorrhagic; there is hyperæmia of the adrenals, exudate in the pleura,

[1] Dutoit recommends that, on getting a negative result, material should be again taken from another spot. In one case the result at first was negative, but in the debris of a corneal ulcer virulent diphtheria bacilli were found. I always make several preparations from different places. Valude makes the same recommendation (*Ann. d'Oculiste*, 1894, cxi. 290).

and often also in the pericardium. The spleen is usually unchanged; the kidneys often show parenchymatous hæmorrhages. The upper part of the stomach is reddened. Injection into the peritoneum produces a hæmorrhagic peritonitis. The bacilli multiply especially in the site of puncture, but can also pass into the blood.

If we cannot inoculate from the original tube, then a pure culture must first be made, and from this we can inoculate.

In cases which clinically are slight or moderate in severity we can await the result of this examination, which takes a few days, and in the meantime we can treat locally and take precautions against contagion. In the severe cases, whenever the smear shows bacilli of the diphtheria group, Behring's serum should always be injected. When bacteriological examinations are not made, then every case of pseudo-membranous conjunctivitis must be treated with the serum.

Along with the diphtheria bacilli pus-formers are often present (*Staphylococci*, *Streptococci*, *Pneumococci*, Plate I., Fig. *VI.*). The mixture of *Streptococci* with diphtheria bacilli produces an especially severe clinical lesion of the conjunctiva.

The experiments of Coppez, confirmed by Dugast, show that the participation of the cornea in a conjunctival diphtheria is due to the toxin, which loosens the epithelium and penetrates into the parenchyma. Such a complication only shows after twenty-four to forty-eight hours, when the toxins begin to diffuse. The cornea then becomes cloudy. When a very powerful toxin acts for a long enough time, a partial necrosis of the cornea may occur (Coppez). Diphtheria in man never reaches this stage by the action of its toxin alone, though the way is thus prepared for a secondary infection. The actual suppuration of the cornea is caused, as a rule, by secondary infection with pyogenic organisms. For this reason a suppuration, when it has already begun, is not influenced by the serum treatment—in other respects so generally efficacious.[1]

Uhthoff has shown by experiment on rabbits that occasionally a severe purulent corneal infiltration can be caused by the diphtheria bacillus alone.

Morax and Elmassian found the same incubation time for the conjunctiva which Coppez had obtained for the cornea. Twenty-four to forty-eight hours after the instillation of diphtheria toxin into the

[1] In considering the action of serum used locally (Coppez), or better subcutaneously injected (Dugast), we must note that even without it many of these cases heal rapidly; the beneficial effect on the severe cases is the best proof of its value (Saemisch, *cf.* Axenfeld, 'Serumtherapie infektiöser Augenerkrankungen,' Freiburg, 1905). Schmidt-Rimpler and Aubineau have used the serum in cases of post-diphtheritic paralysis of accommodation.

intact conjunctiva a typical pseudo-membranous conjunctivitis set in.[1] This proves that the diphtheria poison alone is capable of producing a pseudo-membranous conjunctivitis. This is not contradicted by the fact that, as a general rule, virulent diphtheria bacilli are only found on the human conjunctiva when the ground has been first prepared for them by an eczema or scrofulous condition of the lids (Uhthoff). It is of interest to note that Coppez found diphtheria bacilli in an extraordinary case of *chronic conjunctival diphtheria* which had existed for a year. The literature referring to this little-known form is collected in his paper. T. H. Harlan describes a similar case of several months' duration with virulent diphtheria bacilli. It is a question in many cases whether a pemphigus or a herpes iris conjunctivæ (Hanke) was not present.

As will again be stated in the special chapters, the formation of a pseudo-membrane can occur in a conjunctivitis due to the Koch-Weeks bacillus, the *Pneumococcus*, or the *Gonococcus*. As a rule, this consists merely of a superficial membrane, easily removable. Cases have been described in which a severe pseudo-membranous lesion has been caused by *Pneumococci* (Becker, Roscher, Kimpel, Hertel, Fruginelli, and Christ). If we are to consider the *conjonctivite suraiguë* of Sameh Bey as an infection with Koch-Weeks bacillus, then this organism must be capable of causing necrosis of the cornea. Peters and Kruse are inclined to attribute the formation of a slight pseudo-membrane—*e.g.*, after an injury—to the action of avirulent *Bacillus xerosis;* whether rightly or not is yet to be decided. The results of Lor, C. Fränkel, Uhthoff, and Roscher show that occasionally the *Gonococcus* can produce a pseudo-membrane ; slight membranes are well known to occur in gonorrhœa. A similar condition occurred in a case of diplococcal infection described by C. Fränkel (see p. 208). A similar state of the conjunctiva is recorded with the exclusive presence of *Staphylococcus pyogenes aureus* (Bietti, Christ, Guibert, Pichler, and others); also with Friedländer's bacillus (Brayley and Eyre). A case by Taylor showed only *Coli communis*;[2] one by Knapp enormous numbers of influenza bacilli. The *coli* has the power of forming pseudo-membranes in other parts of the body.

In the case of these various organisms, which are also found mixed, the clinical pictures vary somewhat.

Considering them all, we must say that the other organisms are far behind the diphtheria bacilli[3] and the *Streptococci* in their power to produce membranous conjunctivitis, especially the diphtheritic form, and that the severe necrotic forms more commonly are due to *Streptococci*, either alone or with Löffler's bacilli.

Finally, cases are not so very exceptional in which a well-marked croupous conjunctivitis gives no bacteriological results of any value. According to the results obtained by Peters and Axenfeld, this is especially the case in the so-called scrofulous inflammations, which can reach this height without any demonstrable bacteriological cause.

[1] The reason why Valenti, in his experiments on animals with toxins of diphtheria, only obtained slight irritation was due to the fact that he did not drop it in for a long enough time.

[2] For the literature of these cases, see Lubarsch-Ostertag, 'Ergebnisse,' 'Bakt. des Auges,' 1894-1900.

[3] Sometimes a diphtheria of the skin of the lids occurs with severe necrosis (*cf.* chapter on 'Gangrene of the Lids').

Streptococci.

(*See here* PLATE II., FIG. *IV.*)

As we have already said, the *Streptococcus pyogenes*, either alone or in conjunction with the *B. diphtheriæ*, is the most important factor in those very severe diphtheritic processes, which can cause necrosis of the whole conjunctiva and great danger to the cornea. These cases are very dangerous to life on account of secondary sepsis. The whole surface of the conjunctiva and cornea forms a culture of *Streptococci*. Such cases are often found in the descriptions of streptococcal infection by Fage, Chevallereau, Vialet, Bourgeois and Gaube, Debierre, Villeneuve, Despagnet, H. Coppez, Pichler, Darier, Vanderstraeten, Lebrun, Gasparrini, Uhthoff, Gosetti and Jona, Kauffmann, Valude, O. Meyer, Martin, Pes, Howe, Weeks, Becker, Vossius, Zur Nedden, Saemisch, Chartres, Hieber, Brewerton, Lawson, etc.[1]

Most of the cases were children who were badly nourished or had hereditary syphilis; others were in convalescents. [Chartres reports seven cases in newly-born children, in which only one had a pseudo-membrane, the other six being typical blennorrhœa. They were all severe cases; some of them had perforation of the cornea. One child died of broncho-pneumonia. Except for these cases, *Streptococci* have only rarely been described in ophthalmia neonatorum (Druais, Groenouw, Haupt, Zur Nedden, Weigelin). It is possible that Chartres was mistaken in his cultures, as *Pneumococci* also form chains.] It is probable that the diphtheritic condition of the conjunctiva in measles and scarlet fever belong to this class (Vialet, Uhthoff, Axenfeld, Schottelius). In many epidemics of measles *Streptococci* are comparatively common in the secretion of the ordinary exanthematous conjunctivitis without membrane formation (Schottelius); this should raise the suspicion that we have to deal with a severe epidemic. In the one which was observed by Schottelius and myself the mortality was not only exceptionally high, but the number of very severe cases, with subsequent eye complications and necrotic streptococcal infections, was also very large. Except in the cases mentioned above and the following ones, it is rare for the *Streptococcus* to cause a primary conjunctivitis which is not pseudo-membranous. A simple primary conjunctivitis due to *Streptococcus* is an extreme rarity. The so-called lacrymal streptococcal conjunctivitis (Parinaud, Morax) which follows a stenosis of the nasal duct is a secondary form; it causes a severe

[1] In one case recorded by Holtenhoff a bilateral orbital cellulitis occurred.

inflammation of the conjunctiva, with a painful swelling of the pre-auricular gland and slight feverishness. This is usually rapidly succeeded by an irritation of the iris, due to toxic absorption. This latter condition, which is peculiar in that it occurs without any change in the cornea, though that structure is permeated by the toxin, not only occurs in streptococcal infections of the cornea, but also in infections with the *Pneumococcus* (see Chapter III.). Experiments on animals show that the streptococcal filtrate possesses in a higher degree the power to produce a 'diffusion iritis'—Bardelli has shown this by protracted instillations—while a pneumococcal filtrate does not produce any definite iritis in the rabbit.

It must here be noted that in impetiginous eruptions of the face, which commonly affect the conjunctiva, *Streptococci* are often found in the secretions and in the cultures. This is especially the case in persons with well-marked scrofula, and also in impetigo contagiosa. The conjunctivitis is here secondary, and an extensive formation of membrane is not commonly found in such cases, unless they are associated with diphtheria bacilli.

Characteristics of the Streptococcus Pyogenes.

(Plate II., Figs. *IV.* and *VIa.*)

Streptococcus pyogenes (*Streptococcus erysipelatis, septicus, puerperalis, malignus, articulorum, scarlatinosus*).

In the secretion preparation the (Gram-positive) *Streptococcus pyogenes* varies in appearance: 1. With regard to the size of the individual cocci. This is shown very clearly by Fig. 42 and Fig. *IV.* on Plate II., which were both obtained from similar cases of streptococcal diphtheria of the conjunctiva, and are under the same magnification. 2. With regard to the arrangement of the individual cocci. In Fig. 42 chain-formation is not at all obvious—in many fields it would hardly be noticed; the double form is much more in evidence. When closely examined, we see that chain-formation does occur, but the chains are short and straight. In Plate II. the chains are much clearer; *Diplococci* are also seen. In the phagocytes the cocci often lie together in the manner of *Staphylococci.* (Fig. 43 is drawn from the pus of an orbital cellulitis, due to the breaking out of an empyema of the frontal sinus; long chains were to be seen everywhere.)

The diagnosis of a streptococcal conjunctivitis as against a staphylococcal is one which requires some care. After having observed such cases for years, I have never failed to find chains; and a case such as that in Fig. 42, where there might be a difficulty if only a few fields were examined, is an extreme rarity in my experience. The material should not be too much rubbed out, as then the natural arrangement of the chains of cocci might be destroyed. It is well known that *Streptococci* in animals sometimes do not form chains, so that on the conjunctiva the possibility of a confusion cannot be entirely excluded. It is therefore advisable, in pseudo-membranous or necrotic conjunctivitis in which there appears a strong

probability of *Streptococci*, in cases which show the appearance of Fig. 42, to await the results of a bouillon culture.[1]

Streptococcus pyogenes only rarely plays a part in the other clinical types of conjunctivitis, and mistakes can hardly occur. In the secretion from the lacrymal sac the *Streptococcus* has a great tendency to chain-formation; so also in the interior of the eye, and especially in the vitreous, where even the so-called *Streptococcus brevis* tends to grow in long chains.

Cultures must be used to differentiate this organism from the *Staphylococcus*, which is equally rare in the cornea, when dealing with those rare streptococcal infections where the dense corneal tissues are not so favourable to the formation of chains, and the method of obtaining the material and rubbing it out on the slide loosens the cohesion of any chains which may occur.

FIG. 42.—SECRETION FROM STREPTOCOCCAL NECROSIS OF THE CONJUNCTIVA.
Many *Diplococci*, a few chains.

The differential diagnosis from the *Pneumococcus* by means of a slide is easy and certain, as in no pneumococcal infection do the typical lancet forms fail (*cf.* Fig. 30, Plate II., Fig. *II.*, and Plate III., Fig. *I.*). Of course, in a pneumococcal exudation single round *Diplococci* are often seen. The drawings, made exactly from Nature, show this in many places. In such cases we cannot decide from the microscopical findings whether we have a mixed infection of *Streptococci* and *Pneumococci* or not. It should be noted in this connexion that such a mixed infection in the eye is very rare. I have only seen it here and there in pus from a lacrymal sac (and then long chains were present such as the *Pneumococcus* never forms in secretions). On the other hand, in the hundreds of cases of pneumococcal infection of the cornea (ulcus serpens), which in the course of years we have proved by cultures, we

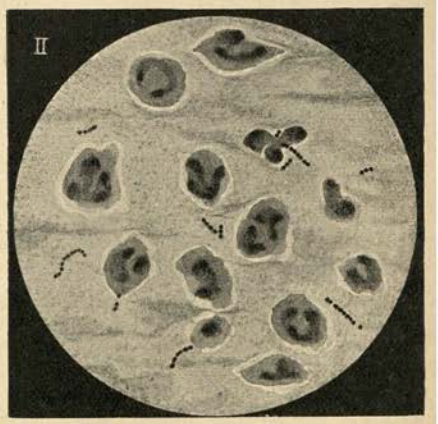

FIG. 43.—STREPTOCOCCAL PUS (ORBITAL CELLULITIS).

[1] The case published by Haglund as one of *Meningococcus* was a pure diplococcal one. In the secretion were only *Diplococci*, some intra-cellular; in the cultures at first *Diplococci*, then long chains. All these forms stained very intensely with Gram. This is not a true *Meningococcus*. The Fränkel *Meningococcus* also forms chains. Fig. 44, from a Fränkel's preparation, shows only *Diplococci* in the secretion; they stain partly by Gram, and thus are different from the Weichselbaum *Meningococcus*.

have never found the *Streptococcus* growing at the same time. The same is true of the numerous cases of pneumococcal conjunctivitis. Such findings as I have figured are rightly to be considered as pure infections with *Pneumococcus;* or, at least, we must attribute to the *Pneumococcus* the causation of the diseased process. When *Pneumococci* do form chains in the secretion, they are quite short, straight little ones, consisting of two or three members, which are to some extent elongated and vary in thickness; while the streptococcal chains are formed of rounded or flattened cocci, of which the adjoining pairs often lie closer, and fuse into a *Diplococcus*. The diagnosis of *Pneumococcus* in secretion can only be difficult as against the *Streptococcus mucosus*. In preparations of the secretion of our case (Rupprecht) elongated *Diplococci* were also found, although in the culture only *Streptococcus mucosus* grew. This variety of the *Streptococcus* is so closely related to the *Pneumococcus* that it can be considered as a variety of that organism (*cf.* p. 187).

The *Streptococcus* and the *Pneumococcus* belong to the great group of the chain-formers. Kruse and Passini have named the *Pneumococcus* the '*Streptococcus* of the mucous membranes,' so that the detailed differential diagnosis may appear to many to be unnecessary at a time when the natural relationships in bacteriology are always being given more weight. This differential diagnosis, however, alone determines the possibility of our evolving a specific serum treatment for the two organisms, and even though this has not yet achieved any definite success, it still deserves our full consideration, and the ophthalmic surgeon should be familiar with the exact differential diagnosis between *Pneumococcus* and *Streptococcus*. If we have only cultures to test, the diagnosis is more difficult; still, it can be made on the following grounds:

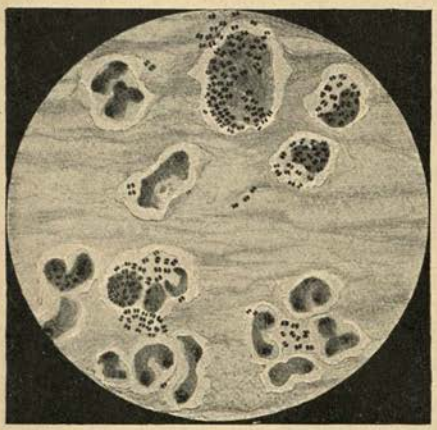

FIG. 44.—DRAWN FROM THE SECRETION IN A FRÄNKEL'S CASE.

(*a*) The presence of elongated *Diplococci* or cocco-bacillary forms on agar and serum.

(*b*) The growth of many *Streptococci* on gelatine.

(*c*) The addition of 1 to 3 per cent. of taurocholate of soda (Neufeld) to the media prevents the growth of *Pneumococcus*, but not that of *Streptococcus pgogenes*. The salt can also be dropped into bouillon. *Pneumococcus* then dissolves after a short time in the incubator, and the fluid clears. *Streptococcus* bouillon remains unchanged.

(*d*) By inoculation in the blood of a white mouse, the *Pneumococci* are to be found in their typical capsulated forms.

(The so-called *Streptococcus mucosus* in these tests usually behaves as a *Pneumococcus*.)

(Though the *Streptococci* in other parts of the body are such common pathogenic agents, in the eye they are seldom in question. Their occurrence on the normal and diseased conjunctiva is described on pp. 41, 205.

They seldom cause corneal infection. They are relatively rare in simple catarrhal or purulent dacryocystitis;[1] they are more commonly found in the pus of a

[1] The *Pneumococci* which form chains in culture are here excepted.

subcutaneous cellulitis, also in orbital inflammations arising from the adjoining sinuses. Concerning the finding of *Streptococci* in the endogenous infections of the eye, see p. 368.

Cultures.—A facultative anaerobe. On agar small round grey surface colonies, slightly stippled, transparent. They generally have sharper margins than the colonies of *Pneumococci*, and have very little tendency to coalesce.

On ascites agar they grow better, and their borders often have fine radial striations.

In bouillon the growth is variable—sometimes a fine cloudiness, sometimes clear, with a more or less free deposit, which often collects into balls, and can only be broken up by vigorous shaking.

Milk is coagulated after a few days. On potatoes there is at most a scanty growth—sometimes, indeed, none at all.

In a gelatine stab-culture at 18° C., fine granules form along the track of the needle without liquefaction; a grey growth, with a smooth, wavy, or indented border, spreads slowly out on the surface.

The chains, which are most easily seen in preparations from bouillon, vary in length and in form in different strains. Behring, von Lingelsheim, and others, have subdivided the organism on this basis[1] into *Str. brevis*, with short chains, diffuse clouding of bouillon, a suspicion of liquefaction in gelatine, growth on potatoes, and generally low virulence; and *Str. longus*, with long chains, giving a deposit at the bottom of the clear bouillon, no liquefaction of gelatine, no growth on potatoes, and greater virulence. This division cannot be rigidly carried out, and the subdivisions attempted by other authors (Lenhartz and Schottmüller) are not recognized. Zangermeister considers that the puerperal and the saprophytic *Streptococci* are the same, and that an exaltation of virulence is possible (*Centr. f. Bakt.*, Ref., 1907, p. 468).

Schottmüller attempted a differentiation of the *Streptococci* by their growth on blood-agar. The *Str. erysipelatis seu longus*, the highly pathogenic form, shows here a definite hæmolysis, a clear circle being formed around the individual white colonies. The *Str. mitior seu viridans* which is not pathogenic or only slightly so, grows as a green or brown smear, without any definite hæmolysis. The capsulated coccus (*Str. mucosus*) forms a glutinous slimy grey-green scum. The *Pneumococcus* develops a dark grey pigment, without any hæmolysis.

Many observers are agreed that the pathogenic forms alone have a hæmolytic action (*cf.* Baumann, *Münch. med. Woch.*, 1906, No. 25). Others, however, deny this; the formation of pigment is also variously stated. It is certainly worth noting these points in the findings in the eye.

There is no constant difference to be made out by the use of different kinds of sugars, although many strains of virulent *Streptococci* constantly cause fermentation, while the *Pneumococcus* and the *Str. mucosus* do not.

The virulence of the *Streptococcus* is very variable; it is best retained in a gelatine culture, which, after two days in an incubator at 22° C. is preserved in an ice-chest. The pathogenicity for man does not always coincide with that for animals. Strains which have become highly pathogenic by passage through animals cannot always be at once used for the production of immune serum, suitable for the treatment of human beings. Individual strains vary much in their power to produce antibodies, so that a serum obtained from one strain does not always immunize to the same extent against other strains. We have, therefore, the preparation of polyvalent sera (Menzer's serum by Merck, Hoechst's antistreptococcal serum, and those of Ahronson and Moser, prepared from strains obtained fresh from

[1] For literature, *cf.* v. Lingelsheim, Kolle and Wassermann, 'Handbook,' vol. ii., and Gunther, 'Bacteriologie,' 1906, sixth edition, p. 735.

the human subject, also the serum of Marmorek, in which the *Streptococcus* is used after an intermediate passage through an animal); and for the same reason we have their variable action in treatment. We find, however, in gynæcology (puerperal infection and prophylaxis in operations) and in medicine (scarlet fever) that good results are being obtained. Serum treatment should therefore be carried out in all severe ophthalmic cases.[1]

When inoculated into the eye, virulent *Streptococci* produce very severe necrosis and suppuration; other strains produce far less irritation.

Regarding the contagiousness of pseudo-membranous conjunctivitis, the general facts known about cases due to the diphtheria bacilli are applicable to those which are due to this organism.

Small epidemics introduced by children affected by such a croupous conjunctivitis have often been observed in hospitals (Schirmer, Vossius). Severe diphtheria of the throat has occurred in connexion with a diphtheria of the conjunctiva.

True epidemics due to infection with the *Streptococcus* are not yet recorded, though the observations of Vossius favour the possibility of a contact infection.

LITERATURE.[1]

AMMANN, K. M. f. A., 1897, S. 135.

AXENFELD, Beiträge zur Ätiologie der Conjunctivalentzündungen. Heidelberger ophthalmologischer Kongress, 1896. 'Ergebnisse,' von LUBARSCH-OSTERTAG, 1894-99 (1900 to 1905 by ZUR NEDDEN). See here literature of 'Conjunctival Diphtheria.'

AUBINEAU, Ann. d'ocul., 1906, CXXXVI, p. 197.

BASSO, XV. Congresso dell' associazione oftalmologica italiana. Torino, 1898.

BECKER, Inaug. Diss., Jena, 1897.

BIETTI, Annali d'ottalm., 1898, vol. 27, p. 441.—*Ibid.*, Festschrift für Manz, Beilageheft, K. M. f. A., 1903, Bd. 41.

BLANCO, T., Infl. pseudomemb. Arch. de oft. hispano-amer., 1907, VII, p. 153.

BRAYLEY and EYRE, Ophth. Soc., London, November 19, 1896. Ophth. Review, 1896, p 338.

CHRIST, Beiträge zur Augenheilkunde, 1905, Heft 63.

COPPEZ, H., Des conjonctivites pseudomembraneuses. Bruxelles, 1897.

DEYL, Über Ätiologie des Chalazion. Prag, 1893.

DEMARIA, K. M. f. A., 1904, XLII, Bd. 2, S. 246.

DORET, Recherches expérim. sur la virul. des xérosebacilles. Thèse de Genêve, 1904.

DUTOIT, Korrespondenzblatt für Schweizer Ärzte, 1906, Nr. 19 u. 20.

FRÄNKEL, C., Hygien. Rundschau, 1898, Nr. 7.

FRÄNKEL, K, Zeitschr. f. Hyg. u. Inf., 1899, Bd. 31, Heft 2.

GALLEMAERTS (1893), quoted by COPPEZ.

GELPCKE, Bacillus septatus. Karlsruhe, 1898.

GUICHARD, Des formes atténuées de la Diphthérie conjonctivale. Thèse de Paris, 1905.

[1] For further information regarding the present position of this question, *cf.* my paper on 'The Serum Treatment of Infectious Diseases of the Eye,' Freiburg, 1906. I have lately seen two very severe cases of streptococcal necrosis of both corneæ and conjunctivæ in children. The general symptoms were so severe that we had expected a fatal result; after the use of Merck's serum the children began to improve. Of course the eyes were lost. Marten, Basso, Boucheron, and others, have reported similar results with Marmorek's serum.

[2] *Cf.* the literature under 'Bacillus Xerosis.'

GONIN, Revue méd. de la Suisse Romande, February and March, 1899.
GOSETTI-JONA, Riforma medica, 1897, vol. 4, p. 543; Ann. di ott., 1898, p. 50.
GROMAKOWSKI, Zentralbl. f. Bakt., 1902.
HAAB, Korrespondenzbl. f. Schweiz. Ärzte, 1897, Nr. 3 and 4.
HALTENHOFF, Ann. d'ocul., 1906, CXXXVI, p. 334.
HANKE, V., Ärztl. Reformzeitung (Wien), 1902, 15 and 16.
HARLAN, H., Chronic Diphtheria. Ophth. Rec., 1907, XVI, p. 124.
HEINERSDORFF, A. f. O., 1898, Bd. 46, 1, S. 1.
HERTEL, A. f. O., 1902, Bd. 53, S. 503 (Pneumococci).
HOWE, T. Am. O. S. Thirty-third Annual Meeting, p. 36.
JESSOP, T. O. S., 1902, XXII.
KAUFFMANN, Diphth. Bac. auf d. Conj. von Enten. Zentralbl. f. Bakt., 1905, Bd. 34, 3.
KNAPP, A., The bact. diagnosis of the *Bacillus diphtheriæ*, esp. in conjunctivitis. The Journal of Med. Researches, 1904, XII, 4, S. 475, and Amer. O. S., 1904.
LAWSON, T. O. S., January, 1907.
MEYERHOF, K. M. f. A., XLIII, II, S. 225 and 231.
MONGOUR, Annal. d'oculist., 1898, t. 120, p. 53, and Revue génér. d'ophth., 1898, p. 316.
MONTE, DEL, Arch. di Ottal., 1907, XIV, p. 345.
MORAX and ELMASSIAN, Annal. d'oculist., 1899, t. 71, and Verhandl. d. internat ophth. Kongr., Utrecht, S. 465.
MORAX, Thèse de Paris, 1893, ferner Maladies de la conjonctive, Encyclop. franç. d'ophth., 1906.
MORAX and PETIT, Annal. d'oculiste, 1898, t. 70, p. 161.
MÜLLER, L., A. f. A., 1899, Bd. 40, S. 13.
PALTAUF and KOLISKO, Wien. klin. Woch., 1889, Nr. 8.
PES, Giornale della R. Accademia di Medicina di Torino, 1897, vol. 60, p. 85.—*Ibid.*, Sulla sieroterapia delle congiuntiviti pseudomembranose 1899.—*Ibid.*, A. f. A., 1902, Bd. 38.
PETERS, K. M. f. A., 1895, S. 370.
PICHLER, Beit. z. A., 1876, Bd. 2, S. 293.
RAUPACH, Conjunctivitis diphtherica. Zeitschr. f. Veterinärh., 1905, S. 195.
RUPPRECHT, Strept. mucosus. K. M. f. A., 1907, XLV, I.
SAEMISCH, Krankheiten der Bindehaut. Handb. d. ges. Augenh., 2 Aufl., 1905.
SCHANZ, Z. f. A., 1900, Nr. 3; Deutsche med. Woch., 1898, Nr. 33; A. f. A., 1896, Bd. 33, S. 224; Berl. klin. Woch., 1896, Nr. 2.
SCHIRMER, A. f. O., 1894, Bd. 40, 5.—*Ibid.*, ebd., 1896, Bd. 42, 1, S. 131.
STEFFENS, Klin. Monatsbl. f. Augenh., 1900, S. 339.
SYDNEY-STEPHENSON, T. O. S., 1902, vol. 22, p. 59.
SOURDILLE, G., Archives d'ophtalm., January, 1894, t. 14.
TAYLOR, Lavori della clinica oculistica di Napoli, 1896, vol. 3, fasc. 5, p. 273.
TERTSCH, Ein Beitrag zu den dem Diphth.-Bac. ähnlichen Stäbchen des Conjunctivalsacks. Z. f. A., 1904, XII, S. 621.
UHTHOFF, Bakteriologische Untersuchungen bei Diphtherie d. Bindehaut. Wiener Naturforschervers, 1894.—Berl. klin. Woch., 1894, Nr. 34 and 35.—Diskussion zu dem Vortrag GROENOUW. Ophth. Heidelberger Kongr., 1898, S. 272.
VALENTI, Archivio di Ottalm., 1900, vol. 8, p. 20.
VALUDE, Annal. d'oculist., 1898, t. 119, p. 328.
VEILLON und MORAX, Société d'ophth. de Paris, 1900; Revue générale d'ophth., 1900.
VILLENEUVE, Thèse de Paris, 1896, and Arch. d'ophth., t. 16, p. 587.

Vossius, Abhandlungen aus dem Gebiete der Augenheilk. Marhold, Halle, 1896. Ferner Deutsche Praxis, 1901, Bd. 3, Heft 22.

Wagner, Ein Beitrag zur Frage der Heilserumtherapie bei der Conjunctivitis diphtherica. Inaug. Diss., Giessen, 1898.

zur Nedden, Über krupöse und diphtheritische Bindehautentzündungen. K. M. f. A., 1902, XLII, Bd. 1, S. 439.

SECTION 5.—GONOCOCCI AND OTHER GRAM-NEGATIVE DIPLOCOCCI (MENINGOCOCCI, MICROCOCCUS CATARRHALIS) FOUND UPON THE CONJUNCTIVA. BLENNORRHŒA AND OPHTHALMIA NEONATORUM.

(Plate II., Figs. *I.* and *II.*)

The Gonococcus (Neisser).

Morphology and Culture.—Bean or kidney-shaped *Diplococci*, each pair 0·8 to 1·6 μ long, 0·6 to 0·8 μ broad, rapidly decolorizing with Gram, found preferably in the cells. Tetrads occur in cultures, especially when old.

Culture.—Grows at 25° C. to 39° C. (optimum, 36° C.), never under 20° C. (facultative anaerobe), and best on media which contain one-third to one-half uncoagulated human serum (serum agar of Wertheim). Ascites, hydrocele, ovarian cyst, and hydrothorax fluids are also suitable for addition to the serum, though not always to the same extent. Pfeiffer's blood agar can also be used (urine and glycerine media and blood serum of animals also). The pig's serum nutrose agar recommended by Wassermann gives varying results.[1]

The opinion used to be prevalent that the *Gonococcus* could not grow at all on simple media. This is a very uncertain means of differentiation from other forms. The latest experiments show that it does not hold for all strains. According to the researches of Wildbolz, Urbahn, and others, it is possible by continued culture to adapt many strains of *Gonococci* to grow on ordinary media. It is only very exceptionally that original cultures will grow on ordinary media, and then only when pus, a human albuminous fluid, has been freely transferred with the culture. The second transference from here to another agar tube practically always fails. Rather better results are obtained with the Thalmann medium, which is slightly acid. (Two-thirds of the amount of soda necessary for neutralization

[1] Fifteen c.cm. pig's serum, free from hæmoglobin, 30 to 35 c.cm. water, 2-3 c.cm. glycerine, and 0·8 to 0·9 nutrose; shake and boil. Precipitation of the serum is prevented by the addition of the nutrose. Take equal parts of this serum and 2 per cent. agar cooled down to 50° C., mix, and pour into Petri dishes.

is added. For continuous propagation, Thalmann recommended that an equal amount of pig's serum should be added to faintly acid bouillon.)

Opinions are not agreed as to the usefulness of this medium. According to Lehmann and Neumann, who refer to the records of Meyer and Bärmann, this medium was no better than ordinary agar; other authors, however, praise it.

The young colonies on serum agar, etc., are very delicate, superficial, grey, and transparent, hardly projecting above the surface level. Older colonies are very faintly granular, their borders clearer and wavy. They are slimy in consistence. (They can readily be distinguished from the opaque yellowish colonies of the *Micrococcus catarrhalis*.) On blood media the colonies push the blood aside so that a kind of septum is formed between them; the same takes place on media covered with pus. In serum bouillon a slimy deposit is formed, and if kept very still a scum rises to the surface. A diffuse cloudiness occurs when the tube is shaken. (*Cf.* the difference in *Mic. catarrhalis*, p. 216.)

Gonococci die out rapidly in the bodies of animals. When in large quantity they cause local inflammation, due to their endo-toxins. When injected into the anterior chamber, they cause a transient exudation (Christmas). Introduced in sufficient numbers into the peritoneum, they kill mice, guinea-pigs, and rabbits. Sometimes the *Gonococci* can be cultivated from the blood post-mortem. Immunity can be produced against this action by repeated injections, and a highly efficient immune serum can be prepared for the differential diagnosis of the *Gonococci*. Specific immune bodies are often found in the blood of patients with gonorrhœa by the complement method of Bruch,[1] when a general infection, especially an arthritis, has occurred. Cultures previously killed also produce inflammation. Morax and Elmassian were able by the repeated instillation of such material to produce a conjunctivitis, commencing after twenty-four hours' incubation, in men and animals.

Transference of the *Gonococci* by inoculation on to the mucous membranes of animals did not succeed. When a large quantity of virulent *Gonococci* were introduced into the conjunctiva of a young rabbit and the lids then stitched together, the poison introduced caused a transient discharge, in which the *Gonococci* rapidly died out, or at least did not multiply (Heller, Morax and Elmassian, Randolph).

[1] *Deutsch. Med. Woch.*, 1906, No. 34; also R. Müller and Oppenheim, *Wien. Klin. Woch.*, 1906, No. 29.

Numerous inoculations of pure cultures of living *Gonococci* on the human urethra have always produced a typical blennorrhœa (Bumm and others). Urethral inoculations with the allied *Meningococcus* produce no result.[1]

Microscopical investigations regarding the relationships of the *Gonococci* in the human conjunctiva have been made by Bumm and confirmed by Schridde, who found that the cocci occurred freely between the loosened epithelial cells, but here and there they had made their way into the subepithelial tissues.

Other Gram-Negative Diplococci.

Bumm gives the first records of other Gram-negative *Diplococci*. According to him, the following organisms occur:

1. *Micrococcus albicans amplus* (morphologically larger than the *Gonococcus*, grows on gelatine at room temperature, without liquefaction).

2. *Diplococcus albicans tardissimus* (morphologically resembles the *Gonococcus*, but is able to grow slowly on gelatine).

3. *Micrococcus subflavus* (a coccus which grows in the form of a yellowish smear at room temperature, and in its culture is very like the *Staph. albus*, but does not liquefy gelatine, and is not so pathogenic).

Later authors (*cf.* Flügge—'Micro-organisms'—Menge and Krönig, Steinschneider) rightly controvert the statement that with Gram's stain the organisms mentioned decolorize to the same extent as do the *Gonococci*. We can leave aside the four cocci described by Gifford, as they only decolorized after the continued action of the absolute alcohol, and not with the classical method of applying the Gram stain (*cf.* 'Technique,' p. 6). When working in Haab's clinic at the disinfection of the conjunctiva, Marthen three times found Gram-negative cocci, which were nearly related to one of Krukenberg's varieties. Marthen's isolated statement found no credence, as he and others stated that the *Sarcina aurantiaca* was decolorized by Gram, while everywhere it was represented as Gram-positive.

A Gram-positive *Sarcina* has since then been discovered;[2] we therefore must not necessarily doubt these findings of Gram-negative *Diplococci*, even though their classification be difficult. The coccus which Marthen found was probably the *Micrococcus catarrhalis*.

[1] Zupnik, *Berl. klin. Woch.*, 1906, 52.
[2] Nagano, *Zent. f. Bakt.*, Orig., 1905, xxxii. 341. A similar case is shown on Plate II.

Marthen's results would not, however, negative the view that all Gram-negative *Diplococci* found on the conjunctiva are *Gonococci.*

Along with Krukenberg, I have more exactly studied a number of *Pseudo-gonococci,* which were perfectly Gram-negative and still not identical with the *Gonococcus.* Since paying special attention to this point, I have not infrequently found on the normal or slightly catarrhal conjunctiva Gram-negative organisms which from their cultures I could not consider to be *Gonococci.* Kayser has lately recorded a similar finding in my clinic. The sketches (Plate II., Fig. *III.*) are made from such cases, and one of them (*b*) shows a Gram-negative *Sarcina.* On the grounds of these facts, I hold that the opinion of Schantz—that all the Gram-negative *Diplococci* are identical—is entirely unproved. Dr. Brons has carried out a further research on this subject in my laboratory; his investigations related to eight different strains of *Micrococcus catarrhalis* obtained from the conjunctiva, and included a searching inquiry into the relations of this organism to the *Meningococcus* and the *Gonococcus,* using all the latest means of research, with the result that, according to our present knowledge, the *Gonococcus,* the *Meningococcus,* and the *Micrococcus catarrhalis* are all members of the same family.

The first of our *Diplococci* was obtained from a slight, spontaneously healing conjunctivitis. In the secretion it resembled the *Gonococcus* exactly, but it grew freely on coagulated bullock's blood serum, and showed considerably more resistance than the *Gonococcus* had been considered to possess; further, it was an obligate aerobe, had a considerable pathogenicity for animals, and when inoculated in considerable quantity on Krukenberg's own conjunctiva, produced no reaction. This organism would still be considered by Morax as a true *Gonococcus,* as it could be included within the limits of the variability of this organism as determined by his latest researches. Such, however, is quite impossible with the four further strains of Gram-negative *Diplococci* which we found later; they grew freely on agar, peptone agar, and coagulated bullock's blood serum, even at room temperatures (15° C.—two even at 13° C.); one also grew on potatoes.

A confirmatory record is supplied by Neumann and Abelsdorff, who in the secretion of three cases of post-operative conjunctivitis after cataract found Gram-negative *Diplococci,* which could only be distinguished from those of Krukenberg in that their agar colonies took on a white colour later.

Micrococcus Catarrhalis (Pfeiffer).

According to our present knowledge, the organisms mentioned are to be considered as belonging to the group of the *Micrococcus catarrhalis* of Pfeiffer, the Gram-negative *Diplococci* resembling the *Gonococci*, which commonly inhabit the nose and throat, and which are met with in catarrhal secretions from these membranes, as well as in bronchitis.[1] According to the researches of Ghon and H. Pfeiffer, Czaplewski and Urbahn, von Lingelsheim and Brons, the *Micrococcus catarrhalis* is the most vigorous and most resistant of the three members of the family of Gram-negative *Diplococci* (*Gonococcus, Meningococcus, Micrococcus catarrhalis*).

It is generally larger than the *Gonococcus* (*cf.* Plate II., Fig. *III.*), but the difference is not always obvious—the more so as these bacilli, especially in the secretions of the nose or of cases of bronchitis, often lie in the cells. The cocci sometimes occur in large numbers in the conjunctival secretion, even when there is only a very slight irritation. Where the cocci do lie in the cells these are not so fully packed with them as is the case with the *Gonococci*.

The *Micrococcus* has a strong tendency to develop large forms when in culture; tetrads commonly occur. Old cultures show plump degeneration forms. Decolorization with Gram is quite regular, and as rapid as is the case with the *Gonococcus*. In contradistinction to the *Gonococcus*, the cultures show colonies of a more greyish-white colour (having a consistence somewhat like mortar, with a centre which is slightly yellowish, becoming later brownish). According to Brons, the colonies are very easily moved about as a coherent mass without being especially tough in consistence. The margins of the larger colonies appear indented and slightly raised. Under low magnification the colonies appear coarsely granular. Growth is free on all media, even at temperatures under 20° C. In gelatine stab the growth takes place only in the upper part in the form of a small bead, with no liquefaction, and a grey mass radiating outwards on the surface. Stroke cultures on agar, serum agar, and sugar agar form a greyish-yellow bright streak, with a raised border. In bouillon a flocculent deposit forms at the bottom and on the walls of the tube. If the bouillon is very still, then the fluid may remain clear, and a fine surface scum or a ring may form (Brons). In milk good growth without coagulation.

Neutral red litmus whey after a few days becomes blue (alkaline). Following Lingelsheim and His, Brons tested the power of fermenting the various sugars.[2] *Micrococcus catarrhalis* did not ferment any of them. There was no formation of indol.

They are more resistant than the *Gonococcus* against the influence of cold and heat.

[1] From its resemblance to the *Meningococci* found in cerebro-spinal meningitis (*vide infra*), many authors have come to the conclusion that the *Meningococcus* is commonly found in the nose under normal circumstances.

[2] Regarding this differential diagnosis, *cf.* the experiments of Dunn and Gordon (B. M. J., 1905, ii. 421).

Cultures kept for sixty days in the incubator still gave a profuse growth. A culture dried for twenty-four hours on a sterile slide in the incubator gave the same. According to Ghon and Pfeiffer, they can resist drying much longer than this, even to twenty-one days.

At 0° C. they remain for 40 days living.
At 6° C. ,, ,, 6 ,, ,,

These authors also found greater resistance to heat. This may have been due to their having used more vigorous cultures. Von Lingelsheim, working, like Brons, with bouillon cultures, obtained practically the same results:

50° C. was resisted for 1 hour.
60° C. ,, ,, 40 minutes.
70° C. ,, ,, 1 minute.

Pathogenicity for Animals.—Intraperitoneal, intravenous, and subcutaneous injections in rabbits and guinea-pigs had no result. Intraperitoneal injection in mice produced diarrhœa and death. A loopful introduced into a corneal pocket produced a severe infiltration, which, however, healed without a hypopyon. In the conjunctival secretion, and also the ulcers of these cases, large numbers of the *Diplococci* can be found, many of them intracellular.

Agglutination tests could not be carried out with Brons' cocci, as they formed a deposit of themselves, and the most careful stirring only produced a fine flocculent suspension. Von Lingelsheim, using older generations, obtained a more homogeneous fluid, and then showed that a powerful meningococcal serum in a dilution of 1 in 50 agglutinated *Meningococci*, but not the *Micrococcus catarrhalis*. Powerful *catarrhalis* serum had the opposite effect.[1]

Meningococcus Intracellularis (Weichselbaum).

The *Meningococcus intracellularis* cannot be distinguished with certainty from the *Gonococcus* by its morphology, though it is somewhat larger and not always so typical in its kidney shape. The cells are not usually so full of the cocci as in the case of the *Gonococcus*. The latest records regarding its Gram reaction agree—especially those of the latest meningitis epidemic—as to its rapid and complete decolorization.

[Jäger's statement—that they decolorize only partially or do not at all—is now generally regarded as a proof that this investigator had other organisms in his cultures—the more so as they grew and formed chains at the room temperature, a thing which the true *Meningococcus* never does. The latest results of Weichselbaum and his school, obtained in the last great epidemic, absolutely oppose those of Jäger. The coccus of Jäger, the *Diplococcus crassus* (von Lingelsheim), is not uncommonly associated with the *Meningococcus*,

[1] Only highly efficient sera can give, in free dilution, different results with different members of the same family. In strong concentration *Meningococci*, *Gonococci*, and *Mic. catarrhalis* mutually agglutinate as members of the same family (group agglutination, *cf.* also p. 197). The limits of this group agglutination are still being discussed.

and can produce a meningitis ; it is not, however, the cause of the epidemics. It is distinguished from the *Gonococcus* by the Gram stain.)

The Weichselbaum *Meningococcus* grows only in the incubator ; on gelatine at room temperature it does not grow.

To be quite certain of the first culture serum media alone should be used. The *Meningococcus* also grows on glycerine agar, on which medium it can be quite well propagated. Many exudates will only give cultures on serum agar, glycerine agar at first failing. On serum agar the colonies are faintly greyish-yellow, prominent, and moist; they are 1 to 2 millimetres in diameter, sometimes slightly larger. On glycerine the colonies are more transparent, of an iridescent yellow colour, almost homogeneous, and of a slimy consistency. They are easily distinguished with a low magnification from the more granular and browner colonies of *Staphylococci*. The growth of the latter is much more profuse, especially on gelatine, and its reaction with Gram's stain is absolutely positive, etc. The appearance is different from that of the *Micrococcus catarrhalis* (*vide supra*). Streptococcal and gonococcal colonies are in general flatter and smaller, and their further differentiation is quite easy (by means of Gram's stain, chain formation, form of the cocci, etc.).

Their differentiation from the *Gonococcus* is the most difficult. *Meningococci* certainly grow more strongly on blood-serum and glycerine agar as a general rule ; but as this vigorous growth may occur with some strains of *Gonococci*, this method of distinguishing the two is not so certain as was thought.

In bouillon a faint cloudiness occurs with a slight deposit; when shaken this diffuses evenly. On sugar media growth is freer, but not so white and opaque as that of *Mic. catarrhalis*.

No growth on potatoes, nor on gelatine at room temperature. Agglutination tests[1] are of great value in deciding between *Gonococci* and *Meningococci*, both of which become diffused on being shaken; while, as we have seen, the *Mic. catarrhalis* always sinks of itself to the bottom. A meningococcal serum of high value will, in the dilution of 1 in 1,500, only agglutinate the *Meningococci*, not the *Gonococci*. In doubtful cases (and such cannot always be distinguished in culture) this method is of special value. According to Kutscher,[2] it is still more certain if we agglutinate at 55° C.; then the *Meningococci* alone react. Brons in his cases tested the fermentative power with eight different kinds of sugar[3] (dextrose, levulose, cane-sugar, inulin, milk-sugar, galactose, maltose, and mannite). Ten per cent. solutions were added to sterilized Kiebel-Tiemann litmus solution, and then placed for ten minutes in a steam oven; 5 per cent. normal soda solution was added; then 1·5 c.cm. of the sugar litmus solution was added to 13·5 c.cm. ascites agar in a Petri dish. After proving sterility the culture was then inoculated on it. In the case of *Gonococci* fermentation (redness of the medium) only occurred with dextrose; in the case of *Meningococcus* with dextrose and maltose (stronger); *Micrococcus* not at all. Buchanan (Lancet, 1907) states that glucose is only fermented by *Meningococcus*.

It is still to be proved whether these latter differences are constant or not.

[1] Reidel, Berlin, prepares from horses a meningococcal agglutinating serum of high value ; it is sent out in air-tight glass tubes containing 0·1, 0·5, and 1 grain of the dried material. The serum is according to the formula of Kolle (Bern). Directions for use accompany it. The Kgl. Institut für Infections-Krankheiten in Berlin also send out a meningococcal serum of high value (*cf. Cent. f. Bakt.*, 1907, xxxix., Ref., p. 442).

[2] *Deutsche Med. Woch.*, 1906, p. 1849.

[3] *Cf.* analogous experiments of Knapp with the bacilli of the diphtheria group.

Sufficient strains have not yet been tested, and *Gonococci* from different sources and of different generations are not yet sufficiently proved. Von Lingelsheim found some strains in the throat which in their cultures acted like the *Mic. catarrhalis*, but which caused fermentation. The sixth strain examined by Brons fermented all kinds of sugar with the exception of galactose and mannite. These may have been different varieties of Gram-negative *Diplococci*, or one and the same variety may show irregularities in these particulars. All these points must be settled by further research.

The *Meningococcus*, when freshly cultivated, is definitely toxic for guinea-pigs and mice, producing a fatal effect. It is not pathogenic for other animals, and certainly is not to be found in the blood of the animal. According to Ruppel (*Deutsche Med. Woch.*, 1906, p. 1367), an intense pathogenicity for animals can be developed by prolonged cultivation.

Von Lingelsheim has described as occurring in the throat:

Diplococcus pharyngis cinereus;
Diplococcus pharyngis flavus I., II., and *III.;*
Diplococcus pharyngis siccus.

All are Gram-negative cocci. He gives the following as the characteristics of these cocci:

Diplococcus pharyngis cinereus: In the original preparation large rounded cocci, larger than *Micrococci*, evenly round or oval, lying together in twos or more, not in tetrads. Growth scanty. Colonies 1·0 to 1·5 millimetres in diameter. Seen by transmitted light with Leitz 3 OK 1 they are brown, smooth bordered, and coarsely granular. On ordinary agar they form a white scum, as also on gelatine at room temperature; in gelatine stab culture they grow well only at the point of perforation.

Diplococcus pharyngis siccus: Colonies when three days old are 3 millimetres in diameter, and have a very crinkled surface. Their texture is marked by a greater dryness and firmness; they therefore cannot be rubbed up in fluids. The microscopic preparations show fine Gram-negative *Diplococci.*

Diplococcus pharyngis flavus I.: Ascites agar plate cultures show 2 to 3 millimetre colonies. They are quite round, slightly raised, with a greenish-grey translucency, and even by low magnification are very like the *Micrococcus.* Microscopically they show fine round Gram-negative *Diplococci*, very like *Micrococci;* but tetrads are rarer, and there are differences in the size. On ascites agar slopes they form a yellowish-green homogeneous mass, which on the loop shows a distinct yellow colour. Growth is also good on agar.

Diplococcus pharyngis flavus II. morphologically resembles the *Micr. catarrhalis*, but is distinguished by the power of developing a golden-yellow pigment when grown on media containing blood and on Löffler's serum.

Diplococcus pharyngis flavus III. also forms a pigment, which, however, is yellower.

I have already mentioned the Gram-negative *Sarcinæ.* (I must again refer to the chapter on '*Staphylococci*,' p. 39. According to Lehmann, Neumann and Migula, many *Micrococci* can under special circumstances form *Sarcinæ.*)

Brons' sixth strain showed special peculiarities. In the secretion of the lacrymal sac, along with *Pneumococci* and influenza bacilli, *Diplococci* were found which were not intracellular, and which grew on ascites agar in the form of tough, rather firmly adherent yellowish colonies, with smooth borders and finely granular appearance. They diminished from the fourth generation both on this medium and also on peptone agar, becoming pulpy. Their colour gradually became brownish-yellow. Bouillon became diffusely clouded, no scum, but a viscous

slimy deposit, which was homogeneous when shaken up. At 18° C. there was only a slight growth in the upper part of a stab in gelatine. Milk was not coagulated. They fermented all sugars except mannite and galactose. They were not influenced at all by meningococcal serum.

Brons is in doubt whether the varieties may not approach each other still more on further cultivation.

The Abelsdorf-Neumann *Diplococci* are so far peculiar in comparison with the typical *catarrhalis*, in that they form milk-white colonies on agar; they also slowly liquefy gelatine.

Differential Diagnosis of the Gram-Negative Diplococci found on the Conjunctiva.

From what has already been said, it is obvious that the Gram-negative *Diplococci* can present such difficulties in their differential diagnosis that in some cases it is only possible after cultures have been made, and in the cases of *Gonococci* and *Meningococci* after agglutination tests have been carried out. This certainly is frequently seen, but still in a great many cases differentiation is possible without these special means. Anyone who is moderately familiar with the appearance of the *Micrococcus catarrhalis* will recognize it often in smear preparations, on account of its difference in size and shape from the *Gonococcus*, the small amount of secretion present in proportion to the numbers of the cocci, and the free admixture of other organisms (*Staphylococci*, xerose bacilli, etc.); the secretion is also very poor in cellular elements. The very appearance of the slide conveys the idea of a saprophytic growth, as Brons has pointed out. A plate in the *K. M. f. A.*, 1907, Bd. i., shows this very well. The admixture of other Bacteria is not quite so obvious in Plate III. of the present work, as only a small field is there represented. The question between these organisms is easily settled by cultures (*vide supra*). The *Meningococci* present much greater difficulties in their differential diagnosis.

Under certain circumstances agglutination tests are necessary. The test by inoculating the urethra cannot be applied. With that test the differentiation is very easy, as numerous inoculations of *Gonococci* on the human urethra always caused a blennorrhœa; while similar inoculations which Zupink made with fresh cultures of *Meningococci* in the same situation were always negative. This is a biological proof that the *Gonococcus*, in spite of morphological and cultural similarities, is not identical with the *Meningococcus*. Such a method of determination, however, is not available for us.

It would be quite incorrect to conclude that the slide diagnosis of the *Gonococcus* is of no use. It has only lost, relatively, some of

its certainty—to what extent can only be decided when we have answered the questions: To what extent do these Gram-negative Bacteria occur upon the conjunctiva? Under what circumstances have they been met with?

The general experience regarding the urethra is that other Gram-negative organisms are so rare in this situation that the slide diagnosis 'gonorrhœa' is in practice almost absolutely certain. Cases are hardly ever known of in which the typical microscopic appearance has been caused by other organisms; the occasional recorded finding of such organisms only refers to colonies occasionally seen in cultures, and easily recognized there.

With regard to the naso-pharynx and bronchitic sputum, the *Gonococcus* does not come into the question; there are no records, confirmed by culture, of its occurrence in this situation. The earlier isolated records—*e.g.*, Ahlfeld and Trantenroth (*Deut. Med. Woch.*, April 6, 1894, 'Gonokokken in der Mundhöhle'), Rosinsky, and Leyden (*Zentr. f. Gyn. u. Geburt.*, 1894)—refer to purely microscopical appearances, and were most probably due to the *Micrococcus catarrhalis*. In the nasal secretion the differential diagnosis between *Micrococcus catarrhalis* and *Meningococcus* may be of importance, and in the slide present some difficulty. In such cases cultures are available, and render the difference apparent.

In the eye the conditions are different from those of the urethra or the respiratory tract.

We must here state that very few indisputable demonstrations of *Meningococcus* on the conjunctiva have yet been published. C. Fränkel's findings are claimed by Urbahn, Czaplewski, and others to have been other *Diplococci*, as the decolorization by Gram was not complete, and the cultivated organisms grew in chains. Such imperfectly Gram-negative organisms should have been readily distinguished from *Gonococci* in the slide preparation, although their shape was similar—a point I was able to confirm by examining the slides which Geheimrat Fränkel kindly submitted to me (*cf.* Fig. 44, p. 208). Fränkel in his paper only emphasized that the differential diagnosis from the Gram-positive organisms required some care. (They may show the form of the *Diplococci*.) The organism, which Haglund describes as *Meningococcus*, was exquisitely Gram-positive, formed chains in culture, and must be considered as one of the *Streptococci*.

According to the literature collected by Gabrielidès, Koplick (Amer. Med. Assoc., Washington, 1904) found the *Meningococcus* in the secretion of a conjunctivitis which preceded a meningococcal meningitis. I also find it stated that D. Smith

(Arch. of Oph., 1905, xxxiv., p. 48) in 100 cases of conjunctivitis found one with the *Micr. intracellularis meningitidis*, in a woman who had nursed a case of meningitis. An exact cultural differential diagnosis was not made.

In a child of twenty-five months, who had a typical cerebro-spinal meningitis, Gabrielidès found the true *Meningococci* in the cerebro-spinal fluid; and on the inflamed conjunctiva, along with numerous xerose bacilli and *Pneumococci*, he obtained, partly inside and partly outside the cells, Gram-negative *Diplococci*, which in every cultural peculiarity resembled those found in the dural sac. As the conjunctivitis occurred during a meningitis, and at the time there was no possibility of a gonorrhœal infection, this is proof of meningococcal infection.

E. S. Thomson reports that among 400 cases of blennorrhœa (Amer. Med. Assoc., Sect. of Oph., 1906) he saw the *Meningococcus* 'two or three times.' He gives no further details.

G. Canby Robinson [Fifteen Cases of epidemic cerebro-spinal Meningitis, with especial reference to the Isolation of the *Meningococcus* from the circulating blood (Amer. Jour. of Med. Sc., April, 1906, ref. Ophthalmology, 1906, ii., p. 659)] obtained typical *Meningococci* from the purulent secretion of a conjunctivitis in a patient suffering from typical epidemic meningitis. In three further cases these were not to be obtained.[1]

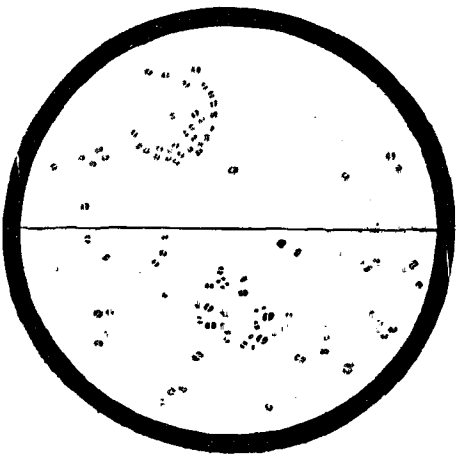

FIG. 45.—MENINGOCOCCI IN THE CONJUNCTIVAL SECRETION OF A CHILD WITH SIMULTANEOUS XEROSIS AND KERATOMALACIA. ASCITES AGAR CULTURE. (GRAM STAIN, SAFRANIN COUNTERSTAIN.) × 1,000.

The fact that the *Meningococcus* can be found in the secretion of the naso-pharynx, not only in cases of meningitis, but also in healthy individuals, is of especial importance with regard to the occurrence of the *Meningococcus* in the eye. This distribution, which has been proved by Weichselbaum, Albrecht and Ghon, Jäger, Flügge, and others, is, however, according to the researches of von Lingelsheim, Ostermann, Westenhoefer, and Hasslauer,[2] restricted to persons in the neighbourhood of meningitis patients.

We cannot assume a free, general distribution of the *Meningococcus* in the healthy nasal cavity, and the records which state this are due to a confusion with the *Micrococcus catarrhalis*.

The opinion that the *Meningococcus* would often be found upon the conjunctiva, an opinion based on this communication of Heubner's, must be corrected; it is, on the contrary, but rarely found in this

[1] *Cf.* records of *Meningococci* in metastatic ophthalmia during cerebro-spinal meningitis.
[2] *Cf. Zentr. f. Bakt.*, Orig., 1906, xli., S. 796.

situation. It would be going too far, when the present epidemics pass over, or when no epidemic occurs, were we to neglect entirely the consideration of this organism. Sporadic cases of meningitis are always being observed. Weichselbaum discovered the *Meningococcus* in a small epidemic. The *Meningococci* must be able here and there to retain their vitality for a considerable time, although in the convalescent cases and in the healthy persons examined they could not be found after a few weeks had elapsed (von Lingelsheim).

Brons has lately recorded the first case of true *Meningococci* on the conjunctiva of a person who had neither suffered from meningitis nor come into contact with any such sufferer. Fig. 45 is made from this case. The patient had a keratomalacia, due to *Pneumococci;* for almost two weeks large numbers of the true *Meningococci* also could be found on the conjunctiva. The true *Meningococcus* is very susceptible to dryness (Albrecht and Ghon, Bettencourt and Franca); if dried for twenty-four hours on glass it is quite killed out. It cannot, therefore, maintain its vitality for long outside the body, a circumstance which further favours its rapid disappearance after epidemics. Germano's statement (*cf.* p. 123) that the *Meningococcus* is very resistant, and belongs to the 'drought-resisting' organisms must, in the light of the latest control tests, be considered as incorrect. He probably worked with Bacteria which belonged to another variety, like the Jäger organism.

Brons has recorded an interesting case from my clinic. The patient suffered from cerebro-spinal meningitis; large numbers of the true *Meningococcus* were found in the cerebro-spinal fluid, and in the conjunctival secretion a *Diplococcus*, which, however, in every cultural peculiarity resembled the *Micrococcus catarrhalis*. Every Gram-negative *Diplococcus* on the conjunctiva of a meningitis patient is not, therefore, to be considered as a *Meningococcus*. It is impossible to say with certainty whether the *Diplococcus* of Urbhan or of the first of Krukenberg's cases really were examples of the true *Meningococcus*.

The results obtained in our clinic show that the organisms of the *Micrococcus catarrhalis* group are more frequently found on the conjunctiva than was formerly thought. Neglecting the first of Krukenberg's cases (as the latest work on the variability of the *Gonococcus* shows that its differentiation from that organism was, perhaps, doubtful), in the four other cases cultures alone were examined in three, and in the fourth a strong resemblance to the *Gonococcus* was demonstrated in the secretion. In Brons' six cases the secretion findings were also available in every one. The organisms were intra-

cellular in few cases; more often they lay in clustered masses. None of our cases were acute, but only showed the scanty secretion of chronically inflamed conjunctivæ, in which were also to be found numerous xerose bacilli, *Staphylococci*, and in one case the *Diplobacillus*. The numbers of the Gram-negative cocci contrasted strongly with the small amount of irritation. This also was noticeable with the Krukenberg cocci in the series by Plaut and Zelewski, referring to the flora of the conjunctiva after extirpation of the lacrymal sac; here also large numbers of xerose bacilli and *Staphylococci* were found. In all these cases (and in a number of others clinically recorded, but from which cultures were not made) the cocci definitely appeared to be saprophytic in their habit, the more so as there was always sufficient ground for the associated irritation (extirpation of the sac, dacryostenosis, ectropion of the punctum, blepharitis, etc.).

The following questions remain undecided: Are not many of the Gram-negative *Diplococci* which are found in pus from cases which present the clinical appearances of a blennorrhœa the *Micrococcus catarrhalis?* Is it possible for a blennorrhœa to arise without organisms, and for the *Diplococci* to have grown secondarily? Does the *Micrococcus catarrhalis* possess the power, like the *Gonococcus*, of producing a blennorrhœa? To what extent is it pathogenic on the conjunctiva?

We cannot yet give definite answers to these questions. What we do know is that in every case of blennorrhœa with *Diplococci* resembling the *Gonococcus* in appearance, staining, and arrangement, when cultures have been made, they have been shown to be true *Gonococci*.

In this respect Groenouw's results agree with those obtained in my own laboratory. There is, therefore, no proof that the *Micrococcus catarrhalis* has the power to produce a blennorrhœa. Nor is it likely that it can originate any process which can develop into a suppuration.

We cannot exclude the possibility that it may cause a simple catarrh though there is no proof that it can. In Urbahn's case, there was a severe catarrh, though not blennorrhœa. As in the cases by Abelsdorff and Neumann, so here, these cocci were in such large numbers that the preparation gave the impression of a gonorrhœa. In post-operative conjunctivitis in three cataract cases Abelsdorff and Neumann found their Gram-negative *Diplococcus*. This organism is very closely allied to the *Micrococcus catarrhalis*, only differing in the power of slowly producing liquefaction in gelatine, and in the milky white colour of the colonies. Its occurrence is, of course, no proof that it has any

etiological significance. Post-operative conjunctivitis is probably to be better explained on the ground of mechanical and chemical (cocaine, disinfection) irritation before and at the operation. The Bacteria found in these cases vary very much.[1]

We have no records of definite inoculations of the conjunctiva with the *Micrococcus catarrhalis*. (Its pathogenicity for the nose is only probable on account of its enormous numbers in the secretion; no positive inoculations have been made.) The pathogenic importance of the *Micrococcus catarrhalis* on the conjunctiva—if, indeed, it has any—still requires further investigation, and more exact bacteriological studies of these organisms would be useful.[2]

With the clinical appearances of a blennorrhœa, the *practical diagnosis of gonorrhœa* can now be made from the Gram-stained slide with so great a degree of certainty that the faint possibility of the occasional presence of *Meningococcus* or *Micrococcus catarrhalis* need not be taken into consideration. Mistakes are more likely to arise in the slide diagnosis of very early cases.

When we find Gram-negative cocci present in a slight catarrh, it may be a case of mild gonorrhœa, and when a culture diagnosis cannot be made, we should in practice consider the more serious condition to be present, and act accordingly; but the possibility of the *Micrococcus catarrhalis* must also be considered. If cultures are made before a case is diagnosed as 'mild gonorrhœa,' we should then be in the position to decide how frequently cases of 'mild gonorrhœa' occur. The statement that, after the healing of a gonorrhœa, the *Gonococcus* remains in the conjunctiva (Groenouw), and can cause recurrences (Meyerhof), requires the same control.

Having found large numbers of intracellular kidney-shaped, Gram-negative *Diplococci* in a case of blennorrhœa, the clinician may consider it as good as certain that he has to deal with gonorrhœa; in other cases the probability is that such is present. Those cases in which the *Micrococci* both clinically and microscopically give the impression that they are saprophytes, and where, in sharp contrast to the cases of gonorrhœa, there is no genital lesion, according to our present knowledge, we should especially ascribe to the benign *Micrococcus catarrhalis*, or to one of the other varieties, and not to the *Gonococcus*.

In this manner our knowledge will increase, and we shall not be

[1] I have most commonly found *B. xerosis*, and also white (rarely yellow) *Staphylococci*. They have a tendency to take the form of Gram-positive, intracellular *Diplococci* (see Plate II., Fig. *VI.*), and on inoculation show only moderate or very slight virulence; probably they have very little to do with the catarrh (*cf.* also p. 81).

[2] Duane and Hastings report in their series that they twice found the *Mic. catarrhalis* associated with the Koch-Weeks bacillus. Such diagnoses should be verified by cultures.

neglecting ascertained clinical and bacteriological facts, and without further thought identifying the various members of the family of the Gram-negative *Diplococci* with each other.

The Clinical Appearances of Gonorrhœal Infection.[1] Blennorrhœa. Ophthalmia Neonatorum.

In comparison with its action on the urethra, the action of the *Gonococcus* on the conjunctiva is peculiar in the following respects:

1. The resulting conjunctivitis does not present a clinical picture which is so peculiarly characteristic as is the case in a gonorrhœal urethritis.

2. The appearance of a blennorrhœa, classically produced by the action of the *Gonococcus* on the conjunctiva, can also be due to other agencies; it is not so exclusively a gonorrhœal condition as in the case of the urethra.[2]

3. A true chronic gonorrhœa of the conjunctiva, comparable with that so commonly found in the urethra, where the *Gonococcus* can be found for years on the mucous membrane, has never been certainly recorded (*vide* Groenouw's and Meyerhof's results).

It has been established that a milder affection can result from the action of the *Gonococcus;* such cases approach the type of a simple catarrh, and are not merely the less acute stage at the onset or termination of the severe form. This latter possibility can occur in special cases, when, before the onset of the gonorrhœa, the conjunctiva has been the site of scarring. Müller has often observed this in Egypt in the case of patients with old trachoma. Even if we do not allow that the Gram-negative intracellular *Diplococci* really were *Gonococci*, but insist that they belonged to the allied but not identical species (*vide supra*), we still can establish the existence of quite mild cases of gonorrhœal catarrh. In 1888 Schmidt-Rimpler asserted that mild cases of gonorrhœal conjunctivitis did occur. In a newly-born child von Herff observed a delayed infection with *Gonococci*, taking the form of a simple catarrh. In my own clinic Brons has recently observed a mild ophthalmia neonatorum in which he demonstrated the *Gonococcus* microscopically and by cultures. Kalt has clearly shown that the introduction of gonorrhœal secretion into the conjunctiva does not always produce the action that would be expected. With a view to

[1] Metastatic gonorrhœal conjunctivitis, mentioned on p. 130, is here excluded.

[2] The exceptional occurrence of a urethritis without *Gonococci* is recorded and confirmed by Jadassohn (see Urbahn, *A. f. A.*, Bd. xlv., Ergzgsh.), Goldberg (*A. f. Derm. u. Syph.*, 1901, Bd. lviii., p. 113, where further literature is given), and Morax.

clearing up an old case of trachomatous pannus in a child, he introduced gonorrhœal pus from the urethra without producing any reaction. A record by Dalen (1897) should here be noted. In a mild acute conjunctivitis in an adult he found a Gram-negative *Diplococcus* which grew rather more freely on ascites agar than the *Gonococcus* usually does, but otherwise was identical with it. Dalen rightly stated that it could quite well be a mild gonorrhœa, but that in such cases attention should be paid to the other allied organisms.

Though rare, slight cases can occur on a conjunctiva which has previously been quite healthy; this has been specially mentioned by Morax and his pupil Druais as a variation of ophthalmia neonatorum. With regard to these *Pseudo-gonococci—i.e.*, the confusion organisms, the name not being intended in the sense of any special variety of Bacteria—it is especially desirable that in the future these cases of apparently mild gonorrhœa should be carefully examined by culture. The same may be said concerning the results of Morax, Müller, and Meyerhof, who state that the *Gonococcus* may lie latent and innocuous in the trachomatous conjunctiva, as, for instance, Meyerhof reports having found enormous numbers of *Gonococci* in a case of trachoma in the partly scarred condition. According to Meyerhof's latest reports, the *Gonococcus* can 'winter' on the trachomatous conjunctiva. Butler also reports that in Palestine he saw very chronic cases with *Gonococci* present. Further testing with cultures is necessary to decide this question.

These occasional and exceptional departures from the typical appearance of gonorrhœa present no special difficulty; they are only examples of how the reaction of the conjunctiva varies with the quantity and virulence of the infecting agent and the susceptibility of the subject. It is obvious from Kalt's case, already quoted, that, in spite of its extreme contagiousness, we can still speak of 'susceptibility' with regard to the *Gonococcus*. In this respect it is worthy of notice that in proportion to the enormous frequency of urethral gonorrhœa the conjunctival affection is rare in adults.[1] We should further note that a conjunctival gonorrhœa may remain one-sided, even although no precautions have been taken, or were possible, to protect the other eye; we must therefore conclude that profuse

[1] Meyerhof emphasizes the remarkable fact that in Egypt, in spite of the frequency of urethral gonorrhœa, and gonorrhœa of the conjunctiva in adults and children, it is rare to find a gonorrhœal ophthalmia neonatorum—the very opposite to what occurs in Europe. Butler says the same with regard to Palestine; he considers that ophthalmia neonatorum is practically unknown in that country, and states that urethral lesions were practically never found in the many children and adults which he observed with gonorrhœa of the conjunctiva. The infection must spread more from eye to eye than from urethra to eye. Gonorrhœal conjunctivitis in summer is more dangerous to the cornea than in winter. Gonorrhœal rheumatism and iritis were never seen by Butler in the East.

contamination with infectious material, which must often occur in washing, etc., does not always produce the disease. In the case of babies the unilateral affection is rarer than in adults: in the former Kroner found six unilateral cases out of sixty-three, Groenouw one in forty-one, and Druais seven in twenty-four; in adults, on the contrary, B. Inouye states that the unilateral is the more common.

It is possible that the infectious material sometimes did not take hold, being so rapidly washed away by the tears, or that a certain amount of immunity was present, or that the damage was averted in some other way—*e.g.*, by the tears making the nidus unsuitable. The urethral secretion also, before reaching the conjunctiva, may have been diluted (*e.g.*, in water), cooled or dried, and thus have lost some of its virulence. Piringer's experiments show clearly the well-known variation of activity in definitely gonorrhœal pus from the urethra, when diluted or cooled. The infectious material in the urethra is, of course, rubbed in with more vigour than in the conjunctiva. In the case of newly-born babies, on the other hand (who also have not yet developed a flow of tears), the susceptibility of the conjunctiva is influenced by the mechanical squeezing and irritation which it is subjected to in the act of parturition.

The occurrence of **non-gonorrhœal catarrh** and **blennorrhœa** in newly-born **infants** naturally varies very much. Soon after the discovery of the *Gonococcus* of Neisser, the serial examinations of Kroner, Widmark, Haab, Schmidt-Rimpler, and others, showed that the *Gonococcus* was absent in many cases of blennorrhœa.

The following are some of the statistical data:

Kroner in 92 cases found the *Gonococcus* 63 times.
Widmark in 103 cases found the *Gonococcus* 64 times.
Chartres in 25 cases found the *Gonococcus* 11 times.
Groenouw in 40 cases of blennorrhœa neonatorum found the *Gonococcus* 14 times.
Haupt in 62 cases found the *Gonococcus* 45 times.
Gonin in 30 cases of catarrh found the *Gonococcus* 24 times.
Morax and Druais in 60 cases of catarrh found the *Gonococcus* 24 times.

As might have been expected, the relative frequency varied.

Kopfstein in fifty-one severe cases only found the *Gonococcus* thirty times.

Since the other causes of conjunctivitis, the Gram-stain, and the finer points of cultural diagnosis have been discovered, these researches have been repeated, with the result that the *Pneumococcus* (Morax, Gasparrini, Axenfeld, Gifford, von Ammon, and others), the Koch-Weeks bacillus (Morax, Chartres, Gonin, Druais, McKee), the *Staphylococcus pyogenes aureus*, when they are found in ophthalmia

neonatorum, mostly produce a simple catarrh, with mild results; but they may occasionally produce an appearance which cannot be distinguished clinically from the true gonorrhœa. This has lately been confirmed by von Herff ('Jahresber. Basel,' 1903, p. 34). The *Diplobacillus* (Morax-Axenfeld) has been found in some rare cases (Andrade, Collomb; see Druais, p. 74). Von Ammon found Friedländer's *Pneumobacillus* three times, von Herff *Pyocyaneus* twice. Axenfeld, McKee, and Bietti found the *Bacterium coli commune* in large numbers and in pure culture; they stated that it probably had an action in producing a conjunctivitis. Chartres, Druais, and others, found the *Streptococcus pyogenes;* Zur Nedden found the 'pseudo-influenza bacillus,' or, rather, the influenza bacillus, pure in cases presenting the appearance of a severe blennorrhœa; Druais and Morax also described a slight case in which they found the Pfeiffer influenza bacillus; Gasparrini described cases complicated with severe destruction of the cornea, in which he found *Pneumococci* of high virulence; Axenfeld, Deyl, and Schmidt found pure cultures of very virulent diphtheria bacilli in cases of ophthalmia neonatorum with marked membranous formation, which rapidly healed under the influence of the curative serum, also single cases with enormous numbers of highly virulent *Staphylococcus aureus;* Cramer, Schmidt-Rimpler, Groenouw describe the *Micrococcus luteus* as present, an organism which is identical with the coccus which von Herff found in a case of ophthalmia, and called the *Diplococcus flavus*, an allied organism to the *Staphylococcus aureus;* Axenfeld, Cramer, Groenouw, Königstein, Morax, and von Herff agree that a typical blennorrhœa can occur without any definite bacteriological findings.

To consider, as does E. von Hippel, that in these cases the *Gonococci* were only difficult to demonstrate, and that they might have even escaped the repeated examinations, is not justifiable, as the authors mentioned examined their cases with every precaution, and it is well known from experience that in gonorrhœa of the conjunctiva, the cocci are freely to be seen in the pus. To avoid any error, only cases which have not been treated, and are not subsiding, should be considered as a test. L. Müller has recently stated that cases of gonorrhœa of the conjunctiva do occur in which the *Gonococcus* can neither be demonstrated in the secretion nor in the culture. In such cases there is a great tendency to attribute the cause to other harmless organisms which may be present.

Fuller details of this rather surprising finding are not available.

The etiology of those rare cases[1] (Magnus, Galezowski, Hirschberg, Nieden, Friedenwald, Strzeminski, Cunningworth, Armaignac,

[1] Sidney Stephenson and Ford have reviewed the literature of the fifty-five cases published up to date. In their own eighteen cases they found the *Gonococcus* fifteen times, the *Pneumococcus* twice, and the *Bacillus coli communis* once.

H. Woods, Morax, Sidney Stephenson, and R. Ford, etc.) in which a child is born with either a commencing or an advanced blennorrhœa, sometimes even with corneal lesions—naturally intra-uterine infection—is not etiologically unique, as here also the *Gonococcus* is much the most important agent, just as in the cases which begin on the first or second day (see the literature by Saemisch, *loc. cit.*, and Morax, *loc. cit.*). Gasparrini has described a severe case of congenital pneumococcal conjunctivitis. On the other hand, the catarrh which sets in later (*i.e.*, from the seventh day on) in the great majority of cases is not gonorrhœal.

The determination that a blennorrhœa of the conjunctiva which is not gonorrhœal does sometimes occur, does not disturb to the slightest degree the etiological significance of the *Gonococcus* in those cases in which it is found in the pus. It is absolutely undoubted that gonorrhœal pus can produce a conjunctivitis, especially seeing that the inoculation of pure cultures of the *Gonococcus* on the conjunctiva has furnished definite proof;[1] in the same way the occasional absence of a reaction after inoculation (see Kalt) does not affect the positive results. Even if in the course of time many of those organisms which we now consider as *Pseudo-gonococci* should be proved to be merely varieties of the *Gonococcus*, its pathological significance would remain certain.

The above facts must not be considered to indicate that there is no clinical difference between gonorrhœa of the conjunctiva and other forms of catarrh. On the contrary, although perhaps we cannot always say on the first clinical examination, whether the case is one of gonorrhœa or not, the further course of the gonorrhœa is, as a rule,

[1] Kartulis obtained a typical urethral gonorrhœa with the pus from a conjunctival case.

Abscesses corresponding to the peri-urethral are rarely found in the eye. In cases such as that of Fuchs ('Lehrbuch,' 1905), where the lids were gangrenous, some other infection probably was at work (*Streptococcus, B. diphtheriæ*). In a few cases the lacrymal gland has been affected (Seligsohn). The majority of the cases of **dacryo-adenitis, with urethral blennorrhœa**, seem to have been certainly metastatic, and not ectogenous (Panas, Gonella, Terson, Pes, Morax and Ferry, Etievant; see the literature by Pes, *A. f. A.*, 1905, li. 157). The anterior **ethmoidal cells** are affected in rare cases (G. F. Suker, Ann. of Ophth., April, 1905). In Campbell-Posey's cases the **sphenoidal sinus** and the nasal cavity were affected (Philadelphia Ophth. Sect., November, 1906, and Ann. of Ophth., 1907, p. 71). Pus from the sphenoidal sinus contained the *Gonococcus;* considering the prevalence of the *Micr. catarrhalis* in the nose, cultures would have been desirable in this case. The occurrence of a **general infection** from the conjunctiva is uncommon. Such cases of conjunctival gonorrhœal rheumatism have been described by Deutschmann, Lindemann, Wicherkiewicz, Sobotka, Koock, Ross, Lucas, Comba, Paulsen, Smith, Altland, Neuberger, Dahlstroem. For further cases, see the literature by Pes (*loc. cit.*, p. 161), and by Saemisch (p. 236); also by Wodrig (Inaug. Dissert., Berlin, 1906). In certain of these cases the *Gonococcus* was found in the joints (Deutschmann, Lindemann, Hoek, Sabotka, Finger, Paulsen, Altland, Dahlstroem, Hocheisen). Of very rare occurrence are such cases as those of Murray—fatal general infection with endocarditis (Ophth. Record, 1900, p. 63); Stevens (*Ibid.*, 1905, p. 519), and Bremer (*Deutsche Med. Woch.*, 1905, No. 2).

quite different from that of the other infections. The series of Groenouw, von Ammon, and Morax confirm this. With rare exceptions, gonorrhœa lasts for weeks, requires special treatment, and is very dangerous to the cornea;[1] the other forms more rapidly subside, especially the pneumococcal conjunctivitis. Gonococcal infection more commonly leads to severe purulent blennorrhœa, non-gonorrhœal to slight forms of catarrh.

In many series (Druais) almost half the cases cannot be defined bacteriologically; in these either nothing is found or else the inevitable *B. xerosis*, with or without a few cocci. The irritant here is probably a chemical traumatism.

Cramer has shown that bruising of the conjunctiva often occurs during parturition, and chemical irritation can occur very easily. The use of silver nitrate (Credé), so common in these cases, can also produce a profuse catarrhal secretion. Cramer is of the opinion that in such damaged conjunctivæ the otherwise harmless *Staphylococci*, which always settle down a few days after birth, can multiply and produce a secretion in spite of their low virulence. Morax states that these are the cases in which hereditary syphilis plays a part. That an influence which generally is slight and weak can markedly affect the onset and the course of a catarrh is shown by the frequency of catarrh in premature and weakly children. It is quite rational to treat cases which are progressing badly by antisyphilitic measures (Lagrange).

No etiological significance can be attributed to the *Bacillus xerosis*, so commonly found in the last-mentioned group. Groenouw examined several cases, and found that the bacilli were quite avirulent when tested on animals, and did not react to the Neisser stain. It is very exceptional to find virulent diphtheria bacilli in newly-born infants.

Groenouw cultivated the *Gonococcus* from the conjunctiva in forty-one cases, and found that, as a rule, the following was characteristic: the organisms grew with certainty only on serum agar; a very slight growth exceptionally occurred on the ordinary media, but only when pus was removed with the organism; they could not be propagated further on these ordinary media.

The presence of the *Gonococci* continues parallel with the amount of the discharge; when the *Diplococci* disappear the secretion ceases. Groenouw has, however, shown that cases do occur in which the *Gonococci* persist after the secretion has ceased, even up to the twenty-fifth day. Meyerhof talks of a persistence for a month.[2] This was probably due to the presence of *Gonococci* on a conjunctiva which had practically returned to the normal condition, and suggests the development of immunity, the more so as gonorrhœa of the conjunctiva always heals without treatment, though in some cases only after destruction of the cornea. A true chronic gonorrhœa of the conjunctiva has not yet been observed. After the

[1] Not only can the *Gonococcus* infect the globe of itself, penetrating into the iris (Dinkler) even as far as the equator (French), but suppuration of the globe can take place from the pyogenic organisms present at the same time (Kalt, Chibret), after the toxin of the *Gonococci* has prepared the way by loosening the corneal epithelium (experiments of Coppez). Chartres says that the associated presence of *Streptococci* is especially dangerous.

[2] It is doubtful whether these persisting cocci did not belong to the other Gram-negative groups. A careful diagnosis by cultures is to be recommended in such interesting cases.

suppuration has ceased, there is merely a stage of papillary trachomatous hypertrophy. As a rule *Gonococci* cannot be found in this stage, which after some time disappears completely, leaving no scarring. If in a trachomatous country a gonorrhœa is directly followed by trachoma (see section on 'Trachoma'), we should consider it a mixed infection. A chronic gonorrhœa, such as would be suggested by the former name of 'chronic blennorrhœa,' is certainly not present in these cases. The fact that, a short time after the subsidence of a gonorrhœal inflammation, the *Gonococci* completely disappear out of the conjunctival sac is certainly no proof that the other Gram-negative *Diplococci* which we find on the normal conjunctiva are to be considered as *Gonococci* which have become avirulent. There is just as little justification for the former hypothesis that *Gonococci* could occasionally be developed out of the other Gram-negative *Diplococci;* a contagion from without can be proved in almost every case of gonorrhœal inflammation.

It is very doubtful whether a superimposed gonorrhœa has any curative action on a trachoma, even though an old pannus may be cleared by this means. Gonococcal toxin, which was shown by the experiments of Morax and Elmassian to produce, after an incubation of twenty-four hours, a severe catarrh on continued instillation, could not produce any curative action.

LITERATURE.

The collected literature up to 1901 can be found in A. f. O., 1901, Bd. lii., p. 66; Groenouw, 'Die Augenentzündungen bei Neugeborenen'; also in 'Ergebnisse,' Lubarsch-Ostertag, by Axenfeld, Sect. 'Bacteriology des Auges,' 1894-1900, Bd. 2, 3, 6 (Supplement), continued in 1900-1905 by Zur Nedden; also in Saemisch, 'Handbuch,' 2nd edit., 'Bindehaut,' p. 216 *et seq.*

Abelsdorff-Neumann, A. f. A., 1900, XLII. S. 68.

Brons, K. M. f. A., 1907, Bd. I, S. 1. *Cf.* here the collected literature of Gram-negative Diplococci.

Butler, R. L. O. H. Rep., 1907, XVII, p. 115.

Dalén, Hygiea, 1899, S. 326. Gabrielidès, Ophthalm. mikrobiologique, Constantinople, 1906, S. 111. La Clin. ophth., 1906, p. 179.

Dauber, Zur Prophylaxe der Ophthalmoblennorrhœa neonatorum. Münch. med. Wochenschr., 1904, S. 297.

Druais, Thèse de Paris, 1904.

French, New York Eye and Ear Infirm. Ref. January, 1897, V.

Haupt, Über gonorrh. und nichtgonorrh. Bindehautentzündung bei Neugeborenen. K. M. f. A., 1903, Bd. XLI, S. 447.

von Herff, Ophthalmoblennorrhœa gonorrhoica. Jahresbericht, Basel, 1904.

Hess, Münch. med. Wochenschr., 1904, S. 456.

Kayser, B., K. M. f. A., 1903, Bd. 42, T. I, Beilageheft (Festsch.).

Koblank, Meningococcus auf der Bindehaut. Amer. Med. Assoc., Washington, 1904.

Koenigstein u. L. Müller, Wien. ophth. Gesellsch., October 25, 1905 (Z. f. A., XV, S. 88).

Krukenberg, K. M. f. A., 1899, Bd. 37, S. 271, 1900, Bd. 38, S. 859, and 1901, Bd. 39, T. II, S. 604.

Lehmann-Neumann, Bakteriologie, 1904 and 1906.

McKee, Blen. Neonat. from B. Coli Comm. Montreal Med. Jour., October, 1906, and February, 1907.

Meyerhof, K. M. f. A., 1905. XLIII, II, S. 226, and Ann. d'ocul., November, 1906, CXXXVI.

MORAX, K. M. f. A., 1900, S. 349.—*Ibid.*, Étiologie des ophthalmies des nouveaux-nés. Ann. d'ocul., 1902, CXXIX, p. 346, and Maladies de la conjonctive, 1905 (Encyclop. franç. d'opht.).
PALDROCK, Staph. alb. den Gonoc. Neisser vortäuschend. Dermat. Zentralbl., 1904, Nr. 11.
PES, A. f. A., 1905, S. 159, Bd. 51.
SCHMIDT-RIMPLER, Blennorrhoe u. Diphtherie. Klin. therap. Wochenschr., 1901, Nr. 9.
SIDNEY STEPHENSON et ROSA FORD, Ophthalmie intrautérine. La Clin. ophth., 1906, p. 179.—*Ibid.*
VON SIKLOSSY, Ann. d'ocul., July, 1898.
SYM, Edinb. Med. and Surg. Journ., August, 1904.
THORNER, Charité-Annalen, 1904, S. 340 (4 Fälle).
URBAHN, A. f. A., 1901, XLIV, Ergänzungsheft.
VANNOD, L'agar ordinaire, comme milieu de culture du gonocoque. Zentralbl. f. Bakt., 1905, XL, S. 162, and 1907, XLIV, Orig., p. 10.
WILDHOLZ, Arch. f. Dermatol. u. Syph., 1902, and Habilitationsschrift. Bern, 1902.
ZABEL, Über die Blennorrhœa neonatorum ohne Gonokokken. Inaug. Dissert., Halle, 1903.

SECTION 6.—STAPHYLOCOCCAL CONJUNCTIVITIS.

PLATE II., FIGS. *V.*, *a* AND *b*; *VI.*, *a* AND *b*.

Staphylococci are very common on the normal conjunctiva, and also in irritative conditions of varied pathology. It is therefore difficult to sharply delimit a staphylococcal conjunctivitis, and the difficulty is increased by the regular failure of repeated attempts to produce a catarrh by the inoculation of pure cultures of virulent *Staphylococci pyogenes aureus* on the human conjunctiva (Leber, Sattler, Bach, Hirota). Collica-Accordina only succeeded three times in producing a conjunctivitis by inoculating very virulent *aureus* on to the intact conjunctiva of newly-born dogs.

This, of course, is no proof that, under special circumstances, virulent *Staphylococci* (particularly the *aureus*, which is rarely found on the normal conjunctiva) are not able to produce a conjunctivitis in man, especially when an irritated condition is already present.

Bach and Neumann report that the introduction of *aureus* into the conjunctiva of a patient who was suffering from a subsiding phlycten caused the profuse secretion to recur. Its prevalence in so many cases of new-born catarrh which are not gonorrhœal, is in favour of its causal significance in these cases (Axenfeld, Groenouw, von Ammon); in their secretions we find *Diplococci* which are certainly very like *Gonococci*, but can be at once differentiated by the Gram stain (see Plate II.).

A similar condition of affairs is present in many cases of follicular catarrh. The coccus found by Michel, Sattler, Goldschmidt, Wildebrand, Saenger, and Staehlin in this condition often shows a number of points of difference from the common coccus (which does not liquefy gelatine). Samperi attributes to the *Staphylococci* an action in the production of that form of conjunctivitis folliculosa which occurs in people who work in a dusty atmosphere. It should be noted that exactly the same organisms occur on the conjunctiva which is not affected with follicles.

Thus, Fig. *IV.*, *b*, on Plate II. is drawn from the secretion of a post-operative conjunctivitis, and shows how a transient and harmless catarrh can occur a few days after a cataract operation, apparently due to the mechanical and chemical irritation at the operation from disinfection, etc. In these cases I have found such phagocytes containing *Diplococci* in enormous numbers. On cultivation the common white, non-liquefying *Staphylococcus*, of variable but slight virulence, was found; it can therefore be concluded that, for such a catarrh at any rate, these organisms have only a secondary importance. These cocci have nothing to do with true trachoma; the experiments of Villards fail to demonstrate any such connexion.

An acute catarrh often occurs in the course of a blepharitis, or an eczema, especially the impetiginous variety; in such cases large numbers of the *aureus*[1] are often found, and under the circumstances may well have a pathological significance. Poulard described this staphylococcal conjunctivitis fully; it is non-contagious, as can be inferred from its frequent unilateral occurrence, and occurs in persons with a special disposition.[2] It is not always possible to prove in these cases that a pyogenic form is present. In some cases the number of the cocci is so small that we should not be correct in attributing an etiological significance to them.

I have often noticed that we find *Staphylococci* in chronic conjunctivitis, in ectropion of the lids or punctum, in cases of neglected catarrh, and in cases of trachoma where the surrounding skin is very dirty. The *Staphylococci* here have probably some action, just as they play an important part in many forms of inflammation of the lids, hordeola, and pustules. In these cases of blepharo-conjunctivitis the *Staphylococcus aureus* is the important one; in the other cases the organism which is found is the ordinary white coccus of the conjunctiva and skin, which does not liquefy gelatine and has a very low virulence.

[1] Often along with *Streptococci*.

[2] Perhaps a low opsonic index.—TRANSLATOR.

In rare cases of pseudo-membranous conjunctivitis *Staphylococcus aureus* alone is found in enormous numbers (Gasparrini, Pichler, Jessop, Coppez, Gosetti and Jona, Bietti, Roscher). These cases can be both severe and lasting. It is much more common to have diphtheria bacilli and *Streptococci* along with the *Staphylococci*.

Further research is necessary to determine the causal connexion between the *Staphylococci* and the so-called phlyctenular external affections of the eye (eczematous and scrofulous).

Sporadic, and usually mild, cases of catarrh are found which do not show the usual conjunctivitis organisms. It is difficult to say whether the *Staphylococci*, which are so often found in these cases along with the xerose bacilli, are causal or not. Stephenson, Randolph, Duane, and Hastings hold the view that they are causal. Hirota states that their occurrence in these cases cannot be differentiated from their occurrence on the normal conjunctiva.

Morax and Elmassian have shown by protracted instillation that the toxins of the virulent *Staphylococci* can produce severe irritation in the conjunctival sac. Randolph produced severe inflammation by their subconjunctival injection. In his latest publication Morax states that a staphylococcal conjunctivitis is quite rare. In his last work on conjunctivitis he insists that the *Staphylococci* mostly develop secondarily—that is, when some other irritation has already occurred; it is quite possible that they can then increase and keep up the inflammation, provided that a really virulent form is present. This may explain how Meijers was able to produce a conjunctivitis in rabbits by the introduction of virulent *Staphylococcus aureus* into the conjunctiva, after ligaturing the lacrymal passages, and stitching the lids together. Römer produced the same result when he irritated the conjunctiva with dust, sand, etc., at the same time as he inoculated it; Samperi did the same; and Cramer is of the opinion that when the conjunctiva has been squeezed and made susceptible during parturition, the *Staphylococcus* can act as the cause of an inflammation in the newly-born.

Gonin, after carefully considering this question, came to the conclusion that in some cases of pseudo-membranous conjunctivitis, catarrh with eczema of the lids, etc., the *Staphylococci* may be considered as the cause, especially if present in large numbers and in a virulent condition, but that in the majority of cases they cannot be so considered. Lundsgaard takes the same view, and I also agree with him. We must not speak of a 'mixed infection' if along with the organism causing the conjunctivitis numbers of *Staphylococci* can

be found, for the latter are generally merely 'associated organisms,' which have no influence on the condition.

The occurrence of *Staphylococci*, with or without *B. xerosis*, in a smear from a simple conjunctivitis is important in that it shows that we have to deal with a non-contagious process, in which the *Staphylococci* are at most of secondary importance; or else with an infection of some other nature, whose cause we have not yet discovered (*e.g.*, trachoma, follicular conjunctivitis, etc.), and in which the *Staphylococcus* is merely casual.

According to my own researches and the records available, the *Staphylococcus* hardly comes into question as the cause of epidemics. We can make the general statement that the *Staphylococcus* on the conjunctiva is not contagious (*cf.* p. 110).

Bach found a very small *Micrococcus* in an epidemic of acute conjunctivitis; its inoculation on the conjunctiva of other persons reproduced the disease. This is the only record of a positive inoculation of the human conjunctiva with any form of *Staphylococcus*. No general deduction can be drawn from this record. On the whole, it is not likely that the *Staphylococcus* is a factor in the contagion of epidemics.

The contents of the *secretion* in *staphylococcal cases* require further consideration and illustration (see Plate II., Figs. *V.* and *VI.*).

In considering the occurrence of *Staphylococci* upon the conjunctiva it is necessary on all possible occasions to take the secretion which has not been in contact with the lid margins or angles. In such situations a secondary contamination and a growth due to contact with the cocci of the skin very soon occurs. The appearances cannot then be referred to the really important cocci in the conjunctival secretion. If we leave aside such cases, then the ones with excess of *Staphylococci* in the secretion are considerably decreased in number. A few stray cocci of this species in a conjunctival secretion are naturally of no etiological significance, as such are found there normally and can multiply on the slightest provocation.

The name *Staphylococcus* (*i.e.*, a bunch of grapes) indicates the clustered arrangement of the round cocci. This familiar appearance can usually be seen in the pus from abscesses of the lids, hordeolum internum or externum (see Plate II., Fig. *V.*, *a*). It is obvious in pus from vitreous abscesses. In the conjunctival secretion it is less frequent; there we more often find irregular masses. The cocci very often vary in size. In many cases phagocytes are numerous, and the cocci may lie in them as well as free; many of what appear at first to be round bodies present on closer examination a partition line, so that we have beautiful 'coffee-bean *Diplococci*.'

The staining has a very great influence on the demonstration of this diplococcal form. The dividing line is hardly visible in preparations which are stained intensely; then the globular form seems very obvious, and the only one present.

This is especially the case in many Gram-stained films, but it also occurs when they are intensely stained with fuchsin. When only stained slightly—and over-staining is carefully avoided—this coffee-bean form is always more obvious, and may even be the only one present. This appearance is very striking in Löffler's

methylene blue films. Possibly in certain secretions this may be a fixed characteristic.

I must here state that after a considerable experience I consider that this coffee-bean form does not indicate any special variety, particularly any pathogenic form, as one might suppose from the emphasis laid upon it by Michel with regard to his so-called *Trachoma cocci*, and by Wildbrand, Saenger, and Staehlin in follicular conjunctivitis. This diplococcal form is common to the whole group of the *Staphylococci*, and is especially noticeable in the white, non-virulent, common form when growing on the conjunctiva. Gram-positive coffee-bean shaped *Diplococci* can generally be diagnosed as *Staphylococci*,[1] and a causal function should not be lightly attributed to them, as in the majority of cases they represent a secondary growth, not the original or sole infection.

The examination of a smear preparation does not allow us to diagnose which variety of the large family of the *Staphylococci* is present, though it may be stated that the typical grape-like clusters appear more frequent in the strongly pathogenic forms, while the Gram-positive *Pseudo-gonococci* (meaning organisms resembling the *Gonococcus* when stained by the ordinary aniline dyes) more frequently occur in the common saprophytic forms.

Even when in a culture there is only one form present (*e.g.*, the slightly pathogenic *Staphylococcus albus non-liquefaciens*, or *Micrococcus candicans*), quite a considerabfe variation in the size and arrangement of the cocci in the secretion preparation may be apparent.

The common cultural characteristics of the *Staphylococcus pyogenes aureus*, *albus*, and *citreus* (the latter of which is the rarest on the conjunctiva) will be found in the chapter on the 'Normal Conjunctiva,' and in the tables at the end. The pyogenic forms liquefy gelatine with acid formation; the saprophytes do not, though their agar and serum cultures very much resemble those of the *albus pyogenes*. In the individual colonies the commonest white saprophytes show a concentric marking and a central prominence; this, however, is not constant. In many cases it resembles the variety known as the *Micrococcus candicans*.

Besides the common representatives of the group of *Staphylococci*, single colonies of the rarer allied forms are occasionally met with, but never in profusion. They are of very little practical value. I have referred to them in the chapter on the 'Normal Conjunctiva' (see p. 36).

In the secretions of other kinds of catarrh—*e.g.*, in trachomatous secretions—we not uncommonly see very large Gram-positive *Diplococci*, in which, when the staining is favourable, the clear separation line is very well marked (see Plate II., Fig. *V.*, *b*). These may belong to the common white variety. They may, however, be Gram-positive *Sarcinæ*, especially when they lie in fours; the *Sarcinæ* in the conjunctiva tend to occur less in packet forms than in fours or in couples (this is also the case for the Gram-negative *Sarcinæ*, see Plate II., Fig. *III.*, *c*). Capsulated tetrads should suggest *Tetragenus* (*Sarcina tetragena*, Migula), which I have obtained a few times.

This organism is of no practical importance in ophthalmic practice (Valude found it in the secretion of a case of dacryocystitis neonatorum). According to Migula, tetrads and *Sarcina* forms can develop out of *Staphylococci*.

On the normal conjunctiva and lid-margins the white *Staphylococci* are commonly found; the *aureus* is the most generally met with on the catarrhal membrane. This is a repetition of what we find in the skin in acute eczema, and in the lids in blepharitis, where with the inflammation the *aureus* always tends to come more and more to the fore. There are several possible explanations for this: either the inflammation affects those people who have the *aureus* present, and

[1] It is much rarer for the *Streptococcus* to show this diplococcal form.

perhaps because of it, or the *aureus* flourishes better on those persons whose tissues are subject to changes such as are present in these conjunctivæ and can further develop on them. This latter does really occur, for in the conjunctivitis of measles—in many epidemics, at any rate—the *aureus* is very plentiful (Schottelius), though it has primarily nothing to do with the measles or the conjunctivitis.

The possibility of a change of the ordinary saprophytic *Staphylococcus* into the pathogenic form, due to a change in the nidus, is still under discussion; further records can be found (see the collected literature by M. Neisser) concerning such transitions—records which in every case do not pay due attention to the sources of error pointed out by Leber, that the white and the yellow *Staphylococci* may be intimately mixed, and can be transferred together in cultures. It is important to remember that Rupprecht and I have obtained a hæmolytic action from conjunctival cocci which appeared to be saprophytic—a characteristic which Neisser would only attribute to the pathogenic forms.

The pigment in the *aureus* belongs to the group of the *Lipochromes*, and is insoluble in water. Every bacteriologist knows that its production is very variable, and Neisser considers it possible that the *Staph. albus* may be a *Staph. aureus*, which, from some external influence, has lost its pigment. This contention must not be carried too far, for the transference of an *aureus* into an *albus*, with its special characteristics, has never yet been successful, and attempts to change a non-liquefying *Staph. albus* into an *aureus* have similarly always failed.

LITERATURE.

Axenfeld, Deutsche med. Woch., 1898, Nr. 1, and 'Ergebnisse,' l. c.

Bach, A. f. O., 1894, Bd. 40, 3.

Bach-Neumann, A. f. A., 1898, 37, S. 93.

Bietti, Annali di Ottalmol., 1897.

Collica-Accordino, Supplemento al Policlinico, 1899 (Ref. Michel-Nagel, 1900, p. 249).

Coppez, Les conjonctivites pseudomembraneuses, Brüssel, 1896.

Cramer, A. f. Gynäkol., 1899, Bd. 59, Heft 2.

Duane and Hastings, N. Y. Med. Jour., 1906.

Gasparrini, Annali di Ott., 1895, Suppl., p. 30.

Gonin, Revue de la Suisse romande, February, 1899.

Groenouw, A. f. O., 1901, Bd. 51.

Hirota, Über die Mikroorganismen der Conj. catarrh. Inaug. Diss., Halle, 1902.

Leber, Sattler, Internat. ophth. Kongr., Heidelberg, 1880.

Lehmann-Neumann, Bakteriologie, 3 Aufl., 1903.

Lundsgaard, Bakt. Stud. over Konjunktivitis. Kopenhagen, 1900, p. 58.

Meijers, Inaug. Dissert., Jena, 1900.

Michel, A. f. A., XVI, 1886 (Trachomcoccus).

Morax, Maladies de la conjonctive. Encyclop. franç. d'ophth. (Valude-Lagrange, 1905).

Morax and Elmassian, Internat. ophth. Kongr., Utrecht.

Neisser, M., and Lipstein, Die Staphylokokken. Handbuch von Kolle-Wassermann, 1903, Bd. 3.

Poulard, Infection staphylococcique de la conjonctive. Arch. d'ophth., 1905, p. 603.

Randolph, Johns Hopkins Hosp. Bull., 1903.

Römer, Z. f. Hyg., 1899, XXXII, Heft 2.

SAMPERI, Archivio di Ottalmol., 1906, XII, p. 106.
SMITH, D., Arch. of ophth., 1905 and 1906, 34 and 35.
STRAUB, A. f. O., 1905, LX, 1.
STEPHENSON, SIDNEY, Note upon a Form of Acute Conjunctivitis associated with Pus Cocci. Lancet, November 13, 1897.
WILBRAND, SAENGER and STAEHLIN, Mitteil. der Hamburger Staatskrankenh., 1894.

SECTION 7.—RARER FORMS OF CONJUNCTIVITIS.

1. Conjunctivitis due to the Bacterium Coli.

PLATE I., FIG. *V.*

In 1896 Axenfeld found the *Bacterium coli* in pure culture in a case of ophthalmia neonatorum; since then Bietti, Zur Nedden, Saemisch, and McKee have also found it. In their series of cases of catarrh in the new-born infant Groenouw and Cramer found, along with the *Gonococcus*, Bacteria which belonged to the coli group, but in some particulars differed from the ordinary form of coli. Axenfeld and Bietti state that blennorrhœa from this cause heals more rapidly than the gono-blennorrhœa (of Saemisch) does. The bacilli when tested on animals were very pathogenic. Jarnatowski reported a case of conjunctivitis with the *Bacterium coli* in an adult. Vossius and Markwaldt found bacilli of the coli group in a case of double conjunctivitis with iridocyclitis occurring in dysentery.

U. Tailor reported a case of peculiar necrotic diphtheritic inflammation in a child of one and a half years. It resembled a lime burn in appearance, and in the discharge bacilli of the coli group were found, which, when tested on animals, did not produce suppuration but necrosis.

We have no definite records of inoculation of human beings with the *Bacterium coli*. As, however, the *Bacterium coli* can cause a catarrh in other mucous membranes, especially the bladder, an etiological rôle can be attributed to it in those cases where it is found in the conjunctival sac in large numbers and in pure culture. Infectiousness has not yet been observed. Its power of causing inflammation and suppuration is apparent from the experiments of Panas and Picot.

The *Bacterium coli* has been found a few times in the pus of a dacryocystitis (Mircoli, Uhthoff, Mazet), once in a panophthalmitis (Randolph), once in pus from the orbit (Loser), and a few times in hypopyon-keratitis (Zur Nedden, de Berardinis, Bietti).

A further case has been observed in my clinic by Kayser. Macnab records a case of keratomalacia in the secretion from which a mixture of coli, *Pneumococci*, and a Gram-negative *Diplococcus* were found.

The organisms in the secretion: A point of differential diagnosis is brought out in the drawing on Plate I., where the Gram-negative bacilli are seen to vary in length. Occasionally they present the appearance of *Diplobacilli*, but not nearly so constantly as does the Morax-Axenfeld bacillus; on the other hand, long threads can be seen as well as single, short individuals. When examined carefully they cannot be confused with *Diplobacilli*. The resemblance to Zur Nedden's bacilli is closer (Plate III., Fig. *III.*), though these latter are slightly curved, and are somewhat smaller.

Shortly stated, its characteristics are as follows:

Short rods with rounded ends, not forming spores, without capsules, about 0·7 to 0·8 μ broad, 1 to 3 μ long, in singles or pairs, rarely longer; the smallest rods look like cocci.

Gram staining is *negative; motile.* The activity of movement is not very great (in contrast to the *Bacillus typhosus*), corresponding to the fact that there is only one flagellum at the end of the bacillus. The motility is very often rapidly lost in cultures as the flagellæ are cast off, and appear free in the fluid of the stained preparation, swollen, rolled up, or tangled. In the case of bacilli which appear to belong to the coli group, but do not show any motility, we must therefore examine very young cultures in the hanging-drop, and with the special stains for flagellæ (*cf.* 'Technical Remarks,' p. 15). In a case of coli blennorrhœa published by Bietti we were only able to find definite motility in cultures which were not more than ten to twelve hours old.

It is a *facultative aerobe.* Growth takes place on all media, even at room temperature. The greyish-white iridescent colonies spread out on gelatine as a circular or dentate film, growing rapidly even at room temperature (*typhosus* grows slowly). The gelatine is not liquefied. On agar a greyish-white, glistening, transparent scum. In bouillon a diffuse clouding, usually with the formation of a thin scum; development of acidity, which in the older cultures again disappears. With varying rapidity milk is coagulated with acid formation. In grape-sugar bouillon acid formation occurs with gas development, especially of oxygen and carbonic acid. In sugar agar and sugar gelatine there is a definite development of gas bubbles. On alkaline potatoes there is a thin yellowish scum. On the addition of nitrite of potash and sulphuric acid to a twenty-four-hour bouillon culture there is a red colour—the *nitroso-indol reaction.* The intensity of this reaction varies with the particular medium. Gunther, therefore, recommends that a control with a standard *coli* should be used.

Of the cases which have been published in the German literature, those of Axenfeld, Taylor, Bietti, Mircoli, Mercanti, Mazet, Uhthoff, Ricchi, Randolph, de Berardinis, Jarnatowski, and Zur Nedden, have all shown the well-known characteristics of the *Bacterium coli* to a varying extent. Groenouw's results differ, in that he did not find gas formation or the indol reaction. The bacilli of Vossius and Markwald were not quite typical. Opinions will vary as to whether these variations should still be reckoned as the *Bacterium coli.*

It should be noticed in this connexion that indol-free strains after prolonged cultivation may eventually produce indol (see Morris, *Arch. f. Hyg. u. Infect.*, 1897, Bd. xxx., p. 309). Bacilli which, while showing all the other characteristics, morphological and cultural, show no motility, have no flagellæ, and do not form gas, may still be considered as modifications of the *Bacterium coli*. Gunther and others oppose this view.

LITERATURE.

Axenfeld, Ophth. Vers., Heidelberg, 1896, Anm., Deutsche med. Woch., 1898, Nr. 1.
Bietti, K. M. f. A., 1899, S. 311.
De Berardinis, Annali di Ottalmol., 1904, XXXIII, p. 18.
Groenouw, A. f. O., 1900, Bd. 52.
Jarnatowski (polnisch), ref. Michel-Nagel, 1898.
McKee, Montreal Med. Jour., October, 1906.
MacNab, 'Ulceration of the Cornea,' London, 1907.
Markwald, Zeitschr. f. klin. Med., 1904, Heft 1 & 2.
Mazet, Thèse de Paris, 1895.
Mercanti, Annali di Ottalmol., 1872, vol. 21, p. 133.
Panas, Archives d'ophth., 1897, XVII, p. 273, and Soc. franç. d'ophth., 1897.
Picot, Archives d'ophth., 1897, XVIII, p. 341.
Randolph, Jour. Amer. Med. Ass., 1893, p. 440.
Saemisch, 2 Aufl. des Handbuchs, 1905.
Tailor, U., Lavori della clin. ocul. di Napoli, 1896, vol. 3, p. 273.
Vossius, Ophthalmol. Klinik, 1904, Nr. 2.
Zur Nedden, K. M. f. A., 1902, XL, Bd. 1, S. 1.

2. Capsulated Bacilli. The so-called Ozæna Bacillus (Löwenberg), and Friedländer's Pneumobacillus. The Bacillus Mucosus Capsulatus.

(Plate I., Fig. *VI.*).

The appearance of the *Pneumobacillus* is clearly seen from the plates. It forms non-motile plump rods of varying length.

In the secretion the capsules are always clearly seen, and when deeply stained they take on the dye much more intensely than those of the *Pneumococcus*.

It grows on all media even at room temperature.[1] Gelatine stab cultures give a typical 'nail culture,' with a porcelain knob rising over the surface of the medium. No liquefaction of gelatine, but a slight brownish discoloration of the medium. On agar and potatoes a thick white scum; in sugar media gas formation. No formation of indol; no spore formation. The cultures are very resistant. Facultative anaerobe.

Gram-staining is *negative*.

Pathogenic for mouse and dog; less so for the guinea-pig; rabbits are not susceptible. This last statement is only true for subcutaneous and intraperitoneal injection. In the vitreous these bacilli cause a severe inflammation (Perles), and they are pathogenic for the cornea and the anterior chamber.

[1] The similar intra-epithelial bacilli, found by Herbert in keratitis punctata superficialis, have not yet been cultivated (see section on 'Keratitis').

These bacilli are considered by many (W. Kruse and others) to form with the so-called ozæna bacillus (Kleinenberger) the group of the *Bacillus mucosus capsulatus*. These bacilli, as a matter of fact, are very closely allied (*cf.* Abel, 'The Capsulated Bacilli'; 'Wassermann-Kolle Handbuch,' 1903, iii., p. 870). Other closely related bacilli are the bacillus of rhinoscleroma (*cf.* 'The Lids,' p. 73) and the *B. lactis aërogenes*, which is of no interest in ophthalmology.

Between the recognized members of this group there are many intermediate forms. There is very little difference in morphology or biology between Friedländer's bacillus, the ozæna bacillus, and the rhinoscleroma bacillus. Their capacity for forming agglutinin, and being themselves agglutinated, has furnished no clinical tests; we therefore cannot differentiate them with certainty. The ozæna bacillus is not known to have any definite significance, and there is still much doubt as to the rhinoscleroma bacillus, which is found in the nasal cavity under normal conditions. These bacilli come under our notice when we consider the rare causes of catarrh.

Lacrymal disease and catarrh of the conjunctiva are very commonly present along with ozæna. Terson and Gabriélidès therefore supposed that the ozæna bacillus of Löwenberg and Abel must be common upon the conjunctiva, and must play a considerable part in infection of epithelial wounds, operations, etc. These writers were confirmed in their opinion by the fact that in twelve cases of ozæna they found these bacilli in the form of Gram-negative encapsulated rods, of varying size, and with the characteristic cultural peculiarities. A case of infection of the cornea passing on to panophthalmitis also showed the same organism.

Since then our views have changed concerning the Löwenberg-Abel bacillus; although it certainly does occur very often in the nose, we cannot attribute to it any causal connexion with ozæna.[1] The very strong resemblance—if not, indeed, identity—between this organism and the *Pneumobacillus* of Friedländer is gradually becoming better known. Their morphology, their staining, and almost all their cultural peculiarities are common, and their pathogenicity for animals is identical. Gourfein states that the only differences are that the *Pneumobacillus* coagulates milk, has a different smell in culture, and can grow on acid media—differences which are not sufficient to justify a separation of the two forms. At any rate, the two bacilli are closely related and belong to a common group, and when we would determine the significance of such organisms in ophthalmology, it is as well to treat them together. The presence of these bacilli in the eye does not necessitate the occurrence of ozæna in the nose.

The supposition of Terson and Gabriélidès is not borne out by the facts; on the contrary, the *Pneumobacillus* is rarely found to be a cause of infection in the eye. Even in pus from the lacrymal sac in patients

[1] *Cf.* Hasslauer, *Zent. f. Bakt.*, 1904, Bd. xxxiv., Ref., p. 353.

with ozæna it is seldom found (Cuénod, Uhthoff and Axenfeld, Gourfein); in these persons the *Pneumococcus* is the most important, both in the conjunctival and in the corneal infections.

The majority of the cases in which the ozæna bacillus has been found upon the conjunctiva were patients who did not suffer from ozæna. Lodato and Angelucci state that the relation of the ozæna bacillus to the conjunctiva, claimed by Terson and Gabriélidès, was not present to the extent stated; they were unable to find the bacilli in the conjunctiva in cases where it was present in the nose.

As a pure conjunctivitis producer, I have not yet met this organism; here and there I have seen individual examples of its rare occurrence on the conjunctiva in other forms of catarrh, and I have also found it freely in the secretions of two cases of chronic conjunctivitis with simultaneous lacrymal trouble. Fig. 46 shows the secretion of one of the cases which Dr. Brons examined in the Freiburg clinic. The *Pneumobacilli* can be at once recognized by their large and distinct capsules; at places where the preparation is deeply stained the capsules have also taken on the dye. In this slide xerose bacilli, *Pneumococci*, and influenza bacilli occur in extraordinary quantity. The preparation from which the figure on Plate I. was drawn was sent me by Dr. Zur Nedden, and it, along with Fig. 46, shows the variable appearance of the bacilli; it was obtained from a case of conjunctivitis with lacrymal trouble. In this case the *Pneumobacillus* alone was present.

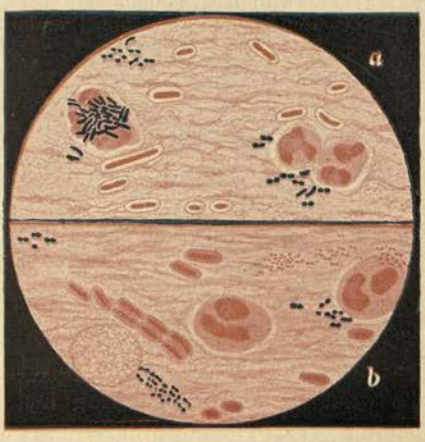

FIG. 46.—FRIEDLÄNDER'S PNEUMOBACILLUS, FROM A CASE OF DACRYOCYSTITIS.

Besides these, we have in *a*, *B. xerosis*; in *b*, *B. influenzæ*; also *Pneumococci* (blue). The capsules of the *Pneumobacilli* are clear in *a*, red in *b* (over-stain with safranin).

Pure infections of the conjunctiva with the *Pneumobacillus* have been freely recorded in the recent literature. Brayley and Eyre found one in a case of pseudo-membranous conjunctivitis. Groenouw, Kreseritzki, and von Ammon saw the same a few times in newly-born infants; Gonin, Zia, and Derby found it in scattered cases; Hirota found the practically identical *Bacillus mucosus capsulatus* rather more frequently, and considered it as the cause of conjunctivitis; Gourfein

found it frequently—20 times in 450 cases. No other author has found this bacillus so frequently in the eye, and therefore Morax has some doubts as to the correctness of the findings.

Gourfein found the bacillus four times in pure culture in cases of new-born catarrh. He described the cases as blennorrhœa of moderate severity; at first they had a superficial membrane. In every case both eyes were affected; the cornea and the lacrymal passages showed no change. Duration was from one to three weeks; in one case there was a recurrence. Gourfein also observed seven cases of catarrhal conjunctivitis resembling Koch-Weeks catarrh, of which two had hæmorrhages in the conjunctiva bulbi. He also saw twelve cases of subacute conjunctivitis, which to some extent resembled diplobacillary conjunctivitis, but were not so chronic.

Gourfein emphasized the variability of the clinical picture. A case of pneumobacillary conjunctivitis of great chronicity is recorded by Derby, and another by Kreseritzki.

Contact transference of this form of conjunctivitis has not been recorded; only sporadic cases have occurred; epidemics are out of the question. Neither have positive infections of the human conjunctiva with pure cultures been made. In those cases, nevertheless, in which the *Pneumobacilli* or ozæna bacilli are plentiful in the secretion they are probably the cause of the inflammation, and certainly they do cause suppuration in the cornea and in wounds. To what extent predisposing factors play a part in these cases we cannot say. The conjunctivitis is certainly rare.

The differential diagnosis is of interest in the demonstration of the Morax-Axenfeld bacillus, which is similar in size and staining. The double form is more constant in the *Diplobacillus*. The *Pneumobacilli* vary very much in length; they are single, and amongst them very short, and also very long, individuals can be seen. The capsule is very obvious in the *Pneumobacilli*, and at once presents a definite point of differentiation, as in Gram-stained specimens of the *Diplobacillus* it is not at all obvious, or is quite absent.

The wide, clear spaces around the bacilli are not invariably capsules, but are sometimes due to the fact that around these capsulated bacilli the albuminous fluid retracts when too much heated. When the film has been carefully heated, or is fixed without heat, then the appearance is quite different. The capsule appears to be lighter than the bacillus, but occasionally takes the colour more intensely. Often chains or clusters of bacilli lie together in a common, lightly-stained envelope. When deeply overstained, the capsule may be so dark that the bacilli appear as thick, plump rods, in each of which, as a matter of fact, a Bacterium is enclosed.

On examining cultures, many of these appearances are presented.

In Fig. 47 towards the upper part of the film there is a place which has been heated too much; the surrounding medium has retracted and formed a broad clear space; elsewhere the bacilli lie in a gelatinous stained medium, preventing the movement of the bacilli amongst each other, and composed of their confluent capsules.

The cultural characteristics and the pathogenicity of the *Diplobacillus* are also quite different; it will only grow on blood-serum and media containing human fluids at blood temperatures. It has no pathogenicity for animals, while the so-called ozæna bacillus will grow in a characteristic manner on the ordinary media even at the temperature of a room, and will cause suppuration in rabbits.

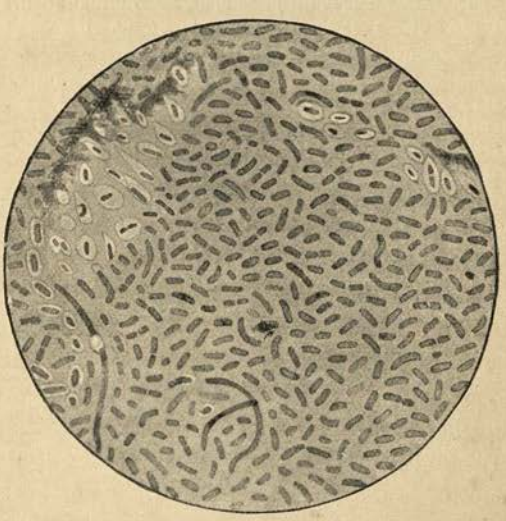

FIG. 47.—FRIEDLÄNDER'S PNEUMOBACILLUS, AGAR CULTURE, FROM A CASE OF DACRYOCYSTITIS.

The even separation of the bacilli is due to the mucous material between (confluent capsules). Where the heat has been excessive, clear spaces have been formed by retraction.

Pneumobacilli are also reported to have occurred in connexion with the eye as follows: In forty cases of dacryocystitis Gourfein found the *Pneumobacillus* four times. The intensity of the symptoms varied; there were no changes in the nose; ozæna was not present. Cuénod, Uhthoff and Axenfeld, and Gerstenberger report single similar cases. In the earlier literature there is a report by Sattler (1887), the first record of this organism; he twice isolated it from lacrymal-sac pus, and proved its pathogenicity for the cornea of the rabbit. Experimental researches into the working of this organism have been made by Mandry, and more fully by Perles, the latter of whom, like Terson, on the basis of his results, ascribed a considerable importance in eye pathology to the *Pneumobacillus*. Loeb found the *Pneumobacillus* in keratomalacia infantum, and Étienne in a dacryocystitis with an ulcus corneæ serpens.

Gourfein, Basso, Zur Nedden, Rupprecht, like Terson and Gabriélidès, found the *Pneumobacillus* in individual cases of hypopyon-keratitis. Gourfein, however, goes too far when he ascribes to the *Pneumobacillus* a power of producing an ulcus serpens equal to that of the *Pneumococcus*, and states that all the pyogenic organisms produce the same clinical appearances in the cornea (*cf.* chapter on 'Keratitis').

The full records show that the *Pneumobacillus* has been found a few times in the contents of chalazia (Priouzeau, Maklakow; *cf.* section on 'Chalazion'). Wopfner found it in the interior of the eye in metastatic ophthalmia resulting from pneumonia; Pergens found it in a metastatic orbital abscess.

The *Pneumobacilli* when grown were very pyogenic when tested on animals, as the earlier experiments of Perles had shown.

LITERATURE.

v. AMMON, Münch. med. Woch., 1901.

BASSO, Cheratite ipopion nell' uomo e cheratite sperimentale da bacillo mucosus ozenae. La clinica ocul., 1903, p. 1479.

CUÉNOD, Dakryocystite ozéneuse. Arch. d'ophth., 1894, XIV, p. 495.

DERBY, The bacillus pneumoniae found in a case of conjunctivitis. The Amer. Journ. of Ophth., 1905, p. 1.

ÉTIENNE, Zentralbl. f. Bakt., 1895, Bd. 18, S. 502.

GERSTENBERGER, Inaug. Dissert., Würzburg, 1895.

GONIN, Revue méd. de la Suisse Romande, 1899.

GOURFEIN, Revue méd. de la Suisse Romande, February, 1902.

GROENOUW, A. f. O., 1901, Bd. 52.

HIROTA, Inaug. Dissert., Halle, 1901.

LODATO, Arch. di Ottal., 1902, Bd. 9, p. 80.

LOEB, Zentralbl. f. Bakt., 1891, Bd. 10, S. 369.

MANDRY, Fortschritte der Med., 1890, Nr. 6.

MORAX, Maladies de la conj., 1906.

PERLES, Erfahrungen über die durch den FRIEDLÄNDERschen Pneumobacillus hervorgerufenen Augenentzündungen. Naturforschervers, Wien, 1894.

SATTLER, Heidelberger ophth. Kongr., 1887.

TERSON and GABRIÉLIDÈS, Arch. d'ophth., 1894, t. 14, p. 488.

UHTHOFF-AXENFELD, A. f. O., 1896, Bd. 42.

WOPFNER, Zur metastat. Panophthalmie. Naturforscherversamml. in Meran. K. M. f. A., XLIII, Bd. 2, S. 402.

3. Bacillus Subtilis on the Conjunctiva.

(PLATE III., FIG. *VI.*)

Bacilli of the *Subtilis* group are also found on the conjunctiva,[1] as, indeed, would have been expected from their wide distribution. Shongolowicz, Puccioni, and Hirota first record their stray and casual occurrence, and, if we reckon the *B. mesentericus* as a member of this group, we must also include the reports of Bach, Franke, and Basso. I have several times seen one or two *Subtilis bacilli* on the normal and also on the catarrhal conjunctiva, but I cannot support Ulbrich's contention that the spore-forming saprophytes—*i.e.*, the *Subtilis* group—are frequently met with in chronic catarrh. Kayser found the *Subtilis* in a glutinous secretion from the conjunctiva in a case of a splinter wound, though the bacilli could not be demonstrated in the globe itself. Gourfein, and Michalski more emphatically, ascribes the power of producing a conjunctivitis to many of the strains which belong to this group. In a house epidemic of acute conjunctivitis, which at first affected thirteen people, and later spread to fifty others,

[1] *Cf.* Literature of 'Normal Conjunctiva.'

Michalski (*Zent. f. Bakt.*, 1904, xxxvi., p. 212) found a *Bacillus conjunctivitidis subtiliformis*. The people lived in a 'dusty manufacturing district.' In three cases *Staphylococci* were also present, and in one *B. xerosis*. When rubbed into the conjunctiva for some time, the organism produced a transient inflammation in rabbits; when injected into the vitreous, it caused panophthalmitis. Negative results were obtained from the inoculation of other animals. Filtered cultures caused no inflammation in the eye.

The following are the morphological and cultural peculiarities of the bacilli: Large motile rods, 2 to 2·5 μ long, 0·5 to 0·6 μ thick, rounded at their ends, with flagellæ; they very often arrange themselves in threads. In the secretion they are often granular in appearance, are Gram-positive, and in old cultures spores are seen centrally placed; milk is peptonized. Their aerobic optimum is 37° C. In bouillon a skin forms; it is wrinkled, yellowish-brown, and easily sinks to the bottom. The bouillon is at first diffusely clouded, but later clears. Gelatine plate colonies have a serrated edge, but no radiating markings; stab cultures in gelatine liquefy, also without any radiations. There is a greater tendency for egg-shaped bodies to form in this medium.

FIG. 48.—B. SUBTILIS, FROM A TRAUMATIC PANOPHTHALMITIS. AGAR CULTURE. GRAM STAIN. × 1,000.

On agar round grey colonies are formed, and the medium is gradually stained a rusty colour; along the site of the stroke there is a dense yellowish wrinkled scum; on potatoes at first a grey, then a chocolate-brown, wrinkled skin. Blood-serum is slowly liquefied. Michalski states that in many points the bacilli resemble the hay bacillus, in others the *B. megaterium*. It is not correct, therefore, to consider that every large spore-containing Gram-positive bacillus is undoubtedly the hay bacillus.

Gourfein (Internat. Ophthal. Congress, Lucerne, 1904, Verhand., B. S. 11) found bacilli of this group so freely present in the conjunctiva that he spoke of a *Subtilis* conjunctivitis. Dorland Smith

found the *Subtilis* very freely in many cases of conjunctivitis in a very dusty neighbourhood. In an acute conjunctivitis Pollock (*loc. cit.*) found a mixture of the Koch-Weeks and the *Subtilis*. Samperi found the *Subtilis* as a casual in follicular conjunctivitis (*cf.* p. 272). The cultural peculiarities of the bacillus which he grew showed a very full agreement with those of the Michalski and Silberschmidt organism.

The colonies which Michalski obtained

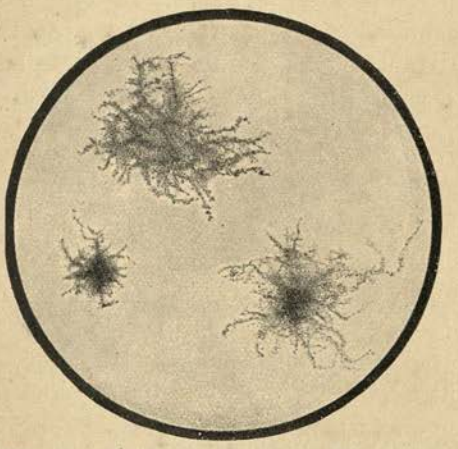

FIG. 49.—B. SUBTILIS, FROM A TRAUMATIC PANOPHTHALMITIS. AGAR PLATE COLONIES. × 30.



FIG. 50.—GELATINE STAB CULTURE, FROM PATHOGENIC SUBTILIS IN THE EYE.

on agar had smooth, rounded edges, while those of Gourfein agreed with the appearances in Fig. 49, which represents the cultures from a splinter, which I obtained in a case of injury. According to Gourfein, the clinical appearances of a *Subtilis* conjunctivitis varied between those of an acute catarrh and those of a mild conjunctivitis. In six cases the inflammation was unilateral. The duration under silver treatment was six to eighteen days. On two occasions there was a superficial corneal ulceration. Each of the seventeen cases observed followed an injury. All the patients were country people. Five of them were children, every one of whom had had a handful of earth thrown in his face, and in the other cases the inflammation could be referred to the introduction of earth.

In five of his cases Gourfein could find particles of earth, containing *Subtilis bacilli;* three times the organism was in a very virulent form. Five times he found the *Subtilis* alone, three times along with *Staph. aureus*, twice with *Streptococci*, and twice with *Pneumococci*.

When inoculated on to the scarified conjunctiva of rabbits, the cultures caused a severe catarrh; in the cornea the results were practically negative. Injections into the anterior chamber caused a severe iritis; when ½ c.cm. was injected the exudation was sufficient to close the pupil. In the vitreous a panophthalmitis resulted, the bacilli themselves rapidly disappearing. In the lacrymal sac they did not cause a true dacryocystitis, but only a slight irritation (epiphora).

We have no records of positive inoculations of the human conjunctiva. The results of Gourfein's experiments, however, are in favour of the view that the conjunctivitis which follows the injury to the conjunctiva with earth is not merely the result of the trauma and the foreign body, but that the bacilli take a part in it. Their prolonged duration in the conjunctival secretion is also in favour of this view.

In any case the occurrence of *Subtilis* on the conjunctiva in any considerable numbers is very rare, and its pathological significance is still a matter for discussion. Excluding its occurrence in large numbers on the conjunctiva after splinter wounds, in the thousands of cases whose secretions I have examined I have only once met with this bacillus in a case which I could call *Subtilis conjunctivitis*.

(For further records of the occurrence of *Subtilis* in the eye, the experimental examination of the cases, the biology of *Subtilis* and the literature of the subject, see the chapter on 'Wound Infection,' p. 77.)

4. Ulcus Molle (Soft Sore).

This affection of the conjunctiva has been described by Vignes (*Bull. de la Soc. franc. d'ophth.*, 1898, p. 94). The *Streptobacilli* of Ducrey were demonstrated. (For further information concerning the methods of demonstration and diagnosis of these bacilli, see section on 'Affections of the Lids,' p. 53.)

5. Glanders (Morve).

In rare cases this infection can occur through the conjunctiva. Nicolle and Dubos have described a case (*Press. med.*, 1902, ii., p. 997; rev. by Petit in the *Ann. d'ocul.*, 1902, cxxix., p. 157), where the conjunctiva was the point of entry. The original irritation of the conjunctiva rapidly passed away, then the swelling of the pre-auricular gland began, and changes in the nose and mouth followed. Five similar cases occur in the literature, in one of which Gourfein was able to grow the *Bacillus mallei* from the ulcerated surface, and to confirm its identity by inoculations (Gourfein, Marignac, and Valette, *Rev. med. de la Suisse romande*, 1897, xvii., p. 737; and *Ann. d'ocul.*, cxxi., 1899, p. 292).

The further case by Strzeminski ('Un Cas de Morve primitive de la Conjonctive tarsienne,' *Postemp. Okul.*, 1900, No. 1) is received with scepticism by Morax, as inoculation tests were wanting.

The disease is very rare, and the bacteriological text-books must be consulted for the more exact peculiarities of the bacilli. They are slender rods 0·5 to 1 μ broad, 2 to 3 μ long, Gram-negative, staining in segments, and then only slightly. They

grow, like coli, on agar and gelatine, but form no gas on sugar media. On potatoes they form a yellow scum, becoming later brownish. They are very pathogenic for guinea-pigs.

Galtier and Conte (*Ann. d'ocul.*, 1902, cxxviii., p. 300) obtained a fatal general infection on the conjunctiva of rabbits. On inoculation in various parts of the globe nodules formed; these ulcerated, and finally the eye was destroyed. Optic neuritis occurred, proceeding from the interior of the eye (Tedeschi, *Annali di Ottal.*, xi., p. 96; Ref., *Ann. d'ocul.*, 1893, T. cx., p. 216).

['Actinomycosis of the conjunctiva' has not yet been observed. The cases of De Vincentiis ('Lavori della Clin. ocul. di Napoli') and of Demicheri (*Arch. d'ophth.*, 1899, p. 102), which are thought by many to be examples of this condition, are really concrements of the conjunctiva as described by Fuchs and Wintersteiner (*cf.* p. 286)].

6. Soor.

Soor has been described on the conjunctiva by Pichler in a case of pseudo-membranous conjunctivitis; it occurred along with *Streptococci* and some double bacilli.[1] In a second case by the same author[2] a child was suffering from scarlet fever, whooping-cough, and chicken-pox; a severe inflammation of the conjunctiva, with necrosis of both corneæ, occurred, and in the greyish-white, dry, sour-smelling scum which covered the eyes, and occurred also in the mouth and nose, masses of soor were found.

In a case of pseudo-membranous conjunctivitis, Pichler found soor on the conjunctiva, along with *Streptococci* and double bacilli (*Beit. z. Aug.*, 1896, Heft 24, S. 1). According to Plaut (*K. und W. Handbuch*, 1903, Bd. i., S. 595), infection of the cornea with soor produces in rabbits an appearance which resembles keratomycosis. When it is introduced into the anterior chamber, a mouldy growth in the inside of the eye results.

7. Parinaud's Conjunctivitis.

The bacteriological findings in Parinaud's conjunctivitis are not uniform. In the collected literature of Verhoeff and Derby, Kayser and Hoor the findings were often quite negative; in other cases only the usual *Staphylococci* and *B. xerosis* were found. Römer and Villeneuve found the *Streptococcus*. Scholtz in his case repeatedly found a pure culture of a Gram-negative bacillus with polar-staining. It was non-motile, did not form spores, and could be grown on all the ordinary media, with the exception of potatoes; it would grow at room temperature quite well, and was a facultative aerobe. Ragged, finely granulated, non-liquefying grey colonies grew on gelatine, also on agar; on Löffler's blood-serum the colonies were punctate. The length of the bacilli was 0·5 to 1·5 μ, and the breadth about the half of this; in the tissues they were longer, and in old bouillon cultures shorter, almost like cocci, and often in chains. They were pathogenic for mice and fowls.

[1] *Beiträge zur Augen.*, 1895, p. 24. [2] *Z. f. A.*, 1900, iii. Ergänzungsheft, p. 669.

The latter died from diarrhœa. The bacillus was very like the *Bacillus gallinarum*, and belonged to the group of the Polar-staining Bacteria (plague, hæmorrhagic septicæmia, etc.). The drawing (Fig. 51) is from a pure culture, kindly sent me by Dr. Scholtz.

This is certainly a very interesting organism. Being an isolated case, a causal significance in Parinaud's conjunctivitis is unlikely, though it must be admitted that in the case quoted it may have played some part in the inflammation.

In spite of the many points of histological resemblance, it cannot be said that tuberculosis is a likely cause of Parinaud's conjunctivitis. Every inoculation has failed, and the search for the *Bacillus tuberculosis* has also been unsuccessful. This question requires further investigation to show whether an organismal cause is present, and if so what it is.

For the Literature, *cf.* Hoor, *K. M. f. A.*, liii., 1905, p. 40; also Rohmer, *Ann. d'ocul.*, 1894, T. iii., p. 360; Villeneuve, *Thèse de Paris*, 1896, p. 95; Gourfein, *Rev. gen. d'ophth.*, 1907, p. 54.

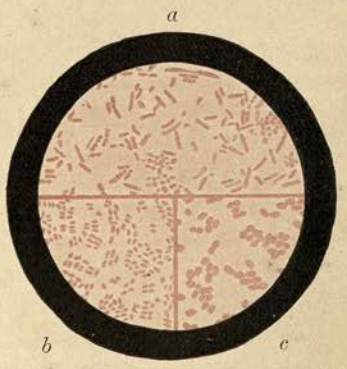

FIG. 51. — SCHOLTZ' BACILLUS, FROM PARINAUD'S CONJUNCTIVITIS. × 1,000.

a, Blood-serum culture, four days old (involution forms); *b*, agar culture, eight days old, at room temperature (bacilli typical); *c*, deposit from a six-day-old culture in bouillon (overstained).

8. Conjunctivitis in the Acute Exanthemata.

CONJUNCTIVITIS OF MEASLES.

It is obvious, from the variety of the findings, that the well-known conjunctivitis which occurs in measles is exanthematous in origin, and is not due to an infection with the ordinary causes of conjunctivitis.

In a large number of measles cases Giarré and Picchi found the influenza bacillus, as did M. Neisser and A. Mayer.[1] Morax, on the other hand, in twenty-two cases out of twenty-six only found the common saprophytes of the conjunctiva. (This agrees with my own observations.) In one of his cases influenza bacilli, in two Koch-Weeks bacilli, in one *Diplobacilli* were found. Morax considered these four cases to be secondary infections of the conjunctiva.

In forty cases Schottelius[2] almost always found the *Bacillus xerosis* regularly associated with *Staphylococci*, in twenty cases the *aureus*; besides this organism the *Streptococcus pyogenes* was found six times (*proteus* once, the *Diplobacillus* once, and once 'air cocci'). The special epidemic examined was one with a high mortality; in 50 per cent. of the post-mortem sections streptococcal sepsis was found. In the

[1] *Münch. Med. Woch.*, 1904. [2] *K. M. f. A.*, 1904, xvii. 1, p. 565.

course of the same epidemic Axenfeld[1] observed many cases of severe conjunctival and corneal complications, many of which were streptococcal diphtheria, with necrosis of the cornea. The comparative frequency with which *Streptococci* were found in the conjunctiva at the outset is closely related to the severity of the secondary results.

Hertel observed severe corneal complications, due to *Pneumococci*, after measles.[2]

The flora of the conjunctiva is a matter of some consequence. The frequency of the influenza bacilli shows either that this organism, as do other Bacteria, finds a specially good nidus during these exanthematous processes, or that both infections tend to occur together. Measles seems to have a special influence in preparing the way for the so-called scrofulous eye affections (*cf.* p. 253).

Similarly, in **pemphigus** affecting the conjunctiva nothing specific has been found, only pyogenic cocci (*Streptococci, Staphylococci; cf.* the findings of Deutschmann and Uhthoff), and *Bacillus xerosis.*

On the findings in **eczema**, see the next chapter.

9. Spring Catarrh.

Even in secreting cases of spring catarrh, no findings of any etiological value have yet been made. I have paid special attention to this question (*cf.* Axenfeld, 'Le Catarrhe printannier,' *Rapp. Offic. de la Soc. Franc. d'Ophth.*, 1907, p. 28). Saemisch records the same opinion. At most the well-known conjunctival saprophytes are found. The alleged positive findings of Bellinzona must be added to these (*Bollet. della Soc. Med. Chir. di Pavia*, 1901, pp. 3 and 4); his statement that he succeeded in producing the early stages of the affection in the conjunctiva of the rabbit is certainly not convincing. The bacillus which Taylor (*Ann. di Ottal.*, 1891) found in a case, and which resembled the *Bacillus subtilis*, represents an isolated casual finding.

Parisotti (*Soc. Franc. d'Ophth*, 1901, p. 298) states that he has demonstrated Blastomycetes in the sections of the limbal growths, and quotes the record of Fortunati having grown two varieties of Hefæ from them (*Arch. di Ottal.*, 1904, p. 81). The one he described as causing the inflammation, the other as causing the anæmia. He states that he has obtained limbus overgrowth by injecting the latter subconjunctivally into rabbits, and that the hypertrophy recurred in warm weather. The etiological significance of these results is not at all proved, and it is still freely argued whether the affection is

[1] *K. M. f. A.*, 1904, xvii. 576. [2] *A. f. O.*, 1902, liii. 503.

contagious or not (*cf.* Dimmer, *Wien. Klin. Woch.*, 1905, p. 2). For my own part, I have not been able to find these Blastomycetes.

SECTION 8.—THE SO-CALLED SCROFULOUS (PHLYCTENULAR, ECZEMATOUS) INFLAMMATIONS.

The well-known appearance of phlyctenular, scrofulous, or eczematous conjunctivitis naturally gave rise to the idea that the individual phlyctens, the subepithelial nodules, owed their origin to circumscribed ectogenous infections, which, according to the known principles of the pathology of inflammation, would determine a collection of leucocytes. The vulnerability of the epithelium, which, since the time of Virchow, has been considered to occur in these scrofulous individuals, prepares the way for an ordinary infection. At the commencement of the bacteriological era this idea was supported by many observers (Duclos and Bucheron, Leber, Sattler, Gifford, Straub, Gallenga). These authors only alleged a limited etiological significance to the Bacteria found, but Burchard and Bach, and D. Smith distinctly state that the phlyctens are caused by a circumscribed inoculation with pyogenic cocci, especially the *Staphylococci*.

Burchard's results cannot be considered in this discussion, as this author did not say either how old the phlyctens were or in what proportion the Bacteria in question were found. For the same reason, the later work of A. Michel (Bordeaux) does not assist us. Exact details on this question are absolutely necessary, as in old-standing cases of such superficial eruptions the demonstration of individual organisms is of no value for the diagnosis of the original cause, just as no causal significance can be attributed to the presence of *Staphylococci* in variola pustules or pemphigus vesicles. In old phlyctenules, too, the original cause may have disappeared, just as in Bach's experiments on animals the *Staphylococci* introduced into the conjunctiva could not be seen after a few days had elapsed.

In considering this question, we must clearly bear in mind that in a mucous membrane which normally contains Bacteria, and which in these scrofulous persons is specially rich in the *Staphylococci*, any superficial affection will be very rapidly contaminated. Before we can explain the phlyctenules as inoculation infiltrations due to the known pus producers, especially the *Staphylococci*, we must demonstrate in the contents of very early phlyctenules the regular presence of a definite number of these organisms.

The results of Axenfeld, von Bach, Neumann, and L. Müller have

shown that this is by no means the case. On the contrary, their researches show, especially in these very early cases, that the results were negative in a comparatively large number of cases, and that in some of the remaining ones the number of the organisms found was so small, and they were so various in their nature, that no definite conclusions with regard to the cause could be drawn from their presence.

Gifford and Straub would attribute the localization of the phlyctenules at the scleral limbus to the stagnation of tears laden with the *Staphylococci* and their toxins, in the cleft between the cornea and the sclera. I cannot admit the existence of such a cleft. The surface of the cornea passes quite evenly over into the conjunctiva bulbi, and when in many scrofulous catarrhs the conjunctiva does rise up from the corneal level, it is a result of the irritation. Straub attributes the earliest commencement of the phlycten to toxic irritation, to which the bacterial invasion is added later. In the many cases where few or no *Staphylococci* are to be found in the conjunctival secretion this presumption of a concentration of toxic action at one spot is not justifiable. Does not Straub by this very hypothesis presuppose some alteration in the limbus which is not due to an infection? In a recent paper Bach has modified his view that an antecedent localization of cocci cannot be held to occur in the small vesicular eruption of the corneal epithelium.

From his experiments Meijers comes to the conclusion that the *Staphylococci* are not without some influence in this infection. Van Haaften, a pupil of Straub, attributes to the *Staphylococci* an active part in the production of scrofulous ophthalmia. He came to this conclusion because he found them relatively more common in the conjunctival discharge of such cases than in that of normal persons. These authors did not examine the contents of the phlyctens; their results, therefore, are not decisive with regard to the incidence of this eruption. Van Haaften goes too far when he considers that the eye-changes are simply 'Staphylococcal scrofula,' as the cultures of more than a third of his cases were negative. Morax reports that he often found *Staphylococci* in the conjunctival secretion of phlyctenular cases, but that the results were also often negative; he considers that their causal influence is doubtful. Leber's description of the condition as impetiginous appeared to him to be the best. With what care the question of secondary infection must be considered is also shown by the frequency with which the inevitable *B. xerosis* is met with. We may, at least, consider the hypothesis that the phlyc-

tenules are due to localized inoculations with *Staphylococci* as not sufficiently proved. The *Staphylococci* must not be considered to have nothing to do with the question; their presence added to an inflammatory process does influence its further course. This is so, not only in the cornea, but also in the conjunctiva.

The inoculations of the human conjunctiva made by Burchard and Bach, who introduced large quantities of *Staphylococci* into conjunctival pockets, cannot settle this question either way.

Such severe disturbances of the tissues do not precede the formation of phlyctenules, and further, we can obtain abscess formation in this way with a variety of organisms. When, however, Bach scratched the conjunctiva bulbi with a needle, and then introduced virulent *aureus* into the conjunctival sac, he obtained no phlyctenules; this Leber had previously done, also without any result. In distinctly scrofulous patients, even in those who had just had an attack of kerato-conjunctivitis eczematosa, small aseptic wounds produced no phlyctenules.

The examination of the secretions of these cases, and even of cases of acute catarrhal conjunctivitis, often gives a negative result—that is to say, only *B. xerosis* and a few organisms of uncertain significance can be found. Bach holds the opinion that the number of the organisms is lessened by means of the tears; but, as a matter of fact, in other forms of infection, with a similar amount of secretion, we find that the number of the organisms is increased. The so-called scrofulous forms of catarrh sharply contrast with the others, in that with a profuse discharge we either find no organisms or only a few.

The virulent yellow *Staphylococci* or the *Streptococci* are found only in a proportion of the cases in which we have associated an impetiginous eczema.

Here and there undoubted conjunctivitis organisms are to be met with, and there is no doubt that in scrofulous persons these can produce the appearances of a phlyctenular affection.

Morax and Axenfeld have observed this in cases of diplobacillary infection, and Gasparrini and Axenfeld in pneumococcal conjunctivitis. In many epidemics a free phlyctenular eruption appears, without any general condition being present as a basis. Such cases have been occasionally observed. The occurrence of eruptions of phlyctenular character at the margin of the cornea has been observed by L. Müller only in scrofulous subjects; they occurred regularly in the epidemic of Koch-Weeks conjunctivitis recorded by Markus. The condition present in these cases may correspond

to the appearance described by the older Vienna school as pustular conjunctivitis. Morax does not consider that these limbal eruptions should be identified with the true phlyctenules; he describes them as vesicles, in contradistinction to the subepithelial nodules, which are the true phlyctenules. Uhthoff, Schmidt-Rimpler, and Schleich and Reuchlin have stated that the formation of such a limbal eruption is not absolutely dependent upon so-called scrofula; this appears likely from the fact that the diagnostic tuberculin reaction often fails in patients with a few phlyctenules. With regard to the cases of recurrent kerato-conjunctivitis, with the characteristic appearance of vessels in the cornea (especially pannus and keratitis fasciculosa), the view that their occurrence requires not only an external irritation, but also some special state of the nidus, cannot be rejected. I have always obtained a positive reaction with tuberculin in these cases.

The observations quoted above that, as a matter of fact, the ordinary forms of infection can produce such symptoms in scrofulous persons, show that an infection from without may be the cause of a phlyctenular eruption. It is, however, not yet proved that the phlyctenules are caused by a local infection with these organisms.

The cases where phlyctenules occur in a conjunctivitis due to the ordinary organisms are specially worth examining, to determine whether the individual phlyctenules are caused by the local inoculation with these organisms or not. A negative result of such an examination, at any rate, would be strong evidence that the phlyctenules could occur in an irritated conjunctiva without any localized inoculation.

On the evidence before us it is hardly probable that kerato-conjunctivitis is a clinical etiological entity of specific nature. It is more probable that it indicates the manner in which the conjunctiva, of scrofulous persons especially, reacts to various forms of irritation.

If we still consider, from theoretical grounds, that cases may be infections, which with our methods appear to be bacteriologically negative, then we must suppose that in these cases we have to do with some unknown organism; and this can naturally also be the case with regard to the occurrence of the individual phlyctenules. The possibility is not altogether excluded that we have to do with an endogenous irritation. We have circumscribed lesions occurring in the clear cornea in herpes zoster and also in herpes febrilis, and we have also undoubted cases of endogenous conjunctivitis in metastatic gonorrhœa, and after experimental injections of pathogenic *Hefæ*

(E. Cohn, Stock). This is no proof that a pure endogenous keratoconjunctivitis does occur. The possibility of its occurrence, however, must be considered.

In his work on this subject Bruns gives my opinion on this point in the following words: 'Axenfeld considers that scrofula is the decisive etiological factor, endogenously producing the phlyctenular process, and that the associated ectogenous irritations only play a secondary part.' This does not accurately represent my views. I have never positively stated that scrofula will produce a phlyctenular inflammation in a purely endogenous manner. I have opposed the view that the endogenous factor can be left aside, and that the problem is solved by the finding of *Staphylococci*, stating that we are not justified at the present time in excluding the possibility of its occurrence in an endogenous manner. The question as to whether such an endogenous infection really does occur, and to what extent, and in what manner it is produced, is quite open. There is a great difference between the statement that 'the affection arises endogenously' and that 'the possibility of an endogenous origin cannot be excluded—*i.e.*, is still open to discussion.' (Similarly Krause is not justified in saying that I have pronounced myself as 'against the bacterial etiology' of this condition.)

Microscopical examination, with the help of bacterial staining, has shown no organisms to be present in the interior of fresh phlyctenules (Axenfeld, Leber, Wagenmann, L. Müller, Hertel, Mayou).

Similarly, the inoculation of fresh phlyctenules into the anterior chamber of rabbits has not produced infection (Augieras, Leber, L. Müller); only in one of Müller's cases did a suppuration occur.

The purulent secretion from such cases of catarrhal conjunctivitis often causes no reaction in the eyes of animals susceptible to *Staphylococci*. These facts, along with the histological structure of the phlyctenules, and the whole clinical appearances, finally exclude the unlikely hypothesis that this form of inflammation is a true tuberculosis. That it certainly is not. It is, on the contrary, simply inflammatory,[1] although there is an indirect connexion between these local scrofular phenomena and general tuberculosis. L. Müller has

[1] The occasional giant cells which occur (Leber) are not of the Langhan's type, and do not prove any tubercular element to be present. On account of these findings, Leber asks the question whether or not dead tubercle bacilli are concerned in their production. In their interesting experiments with dead tubercle bacilli, Leber and Bruns produced changes which were not quite similar to the phlyctenular changes in man. Limbal tuberculosis does occur, though it is rare, and in the early stage resembles phlyctenules. Stock has succeeded in experimentally producing similar conditions through the blood in rabbits; they were essentially different from phlyctenules, as are also the other forms of nodules at the limbus (*e.g.*, in acne rosaceæ).

very carefully examined large numbers of excised phlyctenules for tubercle bacilli, but has never found any. In twenty cases in which the anterior chamber was inoculated in rabbits, only once a transient nodule occurred.

The source of these scrofular or phlyctenular (eczematous) external affections of the eye must therefore be considered in many respects to be an open question. It is certain that Bacteria from without can induce the condition; but whether it is always such a cause, which produces these clinical appearances in the people who are liable to local catarrhal and vasomotor disturbances, or whether mechanical, chemical, or endogenous agencies can have the same effect, can only be settled after further researches have been made. This question of etiology is in many respects analogous to that of the etiology of eczema of the skin, concerning which no uniform results have yet been found, mostly on account of the difficulty of differentiating the secondary organisms present. The sharply marked seborrhœic eczema alone (Unna) can be considered as certainly parasitic. The latest work of Scholz attributes to the *Staphylococcus aureus* some agency in the causation of the acute forms of eczema. Scholz comes to the conclusion that this organism is the primary cause (*Deutsche Klinik*, 1903).

Klingmüller has reviewed the whole question of the pathology of eczema still more recently, and from the experience of the Neisser clinic he concludes that in every eczema of the skin, almost without exception, large, but varying, numbers of *Staphylococci* are present, the yellow being more common than the white. 'They only fail in the vesicles, the primary lesion of the epithelium.' This fact of itself, unless otherwise explained, is directly opposed to the cocci being the direct cause of the vesicles. A true eczema has never been produced either with them or their toxins; at most they have only caused a spontaneously healing dermatitis. They appear only to flourish on a skin which has been rendered susceptible, or is predisposed, to their action. Bender, Bockart, and Gerlach produced an eczema by the action of staphylococcal filtrate free from organisms on the previously irritated skin of the arm. This is explained by M. Neisser and Lipstein[1] as not being due to the toxic activity of the *Staphylococci*, for a similar alkaline bouillon and also the inactive filtrate (heated to 70° C.) produced the same result. In these cases they considered the eczema to be due to a non-specific chemical irritation.

The following points should be noticed: In eczema the *aureus*

[1] Kolle-Wassermann, 1903, Bd. iii., p. 130.

generally is derived from the patients themselves; it is not contagious from without. As virulent *aureus* is relatively very rare in the skin, the question as to whether the ordinary skin cocci, by some variation, have increased in virulence must be considered. Such a change would require an antecedent and preparatory change in the skin.

The cocci which occur in eczema of the skin have an influence on the course of the disease, and generally are more virulent in their characteristics, when contrasted with the common skin saprophytes. This is obvious from the fact that they can form hæmolysin and agglutinate the pyogenic forms. In the scrofulous inflammations of the lids, which are only in part eczematous or impetiginous, and are much more nearly allied to acne, the *Staphylococcus pyogenes aureus* commonly occurs (Gifford, Straub, Deyl, Stephenson, Meijers, van Haaften). To ascribe on this account the clinical picture which we know as kerato-conjunctivitis phlyctenulosa, and still more the individual phlyctenules, to this organism is going much too far.

Though the study of eczema is of importance, it should for the present be provisionally kept distinct from that of the phlyctenular inflammations, as this appearance does not occur in every case of eczema affecting the region of the eye, but only in young scrofular patients, or those who have been affected with scrofula from their youth; and, on the other hand, the corneal eruption has not been proved anatomically to agree exactly with eczema of the skin (*cf.* here the records of Klingmüller). In particular, the formation of a true vesicle, which has been once recorded by J. von Michel, appears to be a rare exception in the records available; phlyctenules are rather subepithelial nodules, and even so they are not quite identical with eczematous papules. The whole clinical course of the corneal condition is not a characteristic of eczema in general, but rather of scrofula.

It should here be noted that Nias and Paton found that the opsonic index of the blood-serum of patients with phlyctenules was lowered for tubercle. The index rose as the lesion improved. They conclude that the phlyctenules are caused by attenuated or dead tubercle bacilli, especially as they found that, under treatment with tuberculin, phlyctenules occasionally occurred. The pathogenesis is by no means proved by this. If phlyctenular kerato-conjunctivitis should be proved to be a staphylococcal disease, the vaccine treatment of Wright with *Staphylococci* should be tried (further, see p. 355).

LITERATURE.

ADDARIO, Archivio di Ottalmol., 1904, XII, p. 1.

AXENFELD, Berl. klin. Woch., 1897, Nr. 39.—*Ibid.*, Bericht über die 26 Versammlung der ophth. Gesellsch., S. 197. Heidelberg, 1897.—*Ibid.*, Pathologie des Auges; Ergebnisse der allgemeinen Pathologie, etc., Lubarsch und Ostertag, Bericht über die Jahre 1895-1899. Bergmanns Verlag, Wiesbaden.

BACH, Z. f. A., 1897-98, Bd. 1 u. 3.—*Ibid.*, Abh. aus dem Gebiete der Augenheilk. Halle a/S., Marhold, 1899.—*Ibid.*, A. f. O., Bd. 41, 2.

BACH and NEUMANN, A. f. A., Bd. 37, S. 57 and 93.

BRUNS, Experimentelle Erzeugung phlyktänenartiger Knötchen durch abgetötete Tuberkelbazillen. A. f. O., 1904, LVIII, S. 439.

BURCHARDT, Zentralbl. f. A., 1887, S. 40.—*Ibid.*, Zeitschr. von v. Lassor, Jahrg. 1893-94, Bd. 1, S. 336.

COHN, E., Exper. Unters. über tierpath. Hefe. Zentr. f. Bakt., 1902, Bd. 31, S. 739.

DUCLAUX et BOUCHERON, Revue mensuelle des maladies de l'enfance, IV.

FOOTE, Med. Rec., May 30, 1896. Ref. Zentralbl. f. A., 1896, S. 661.

GALLENGA, Ateneo medico parmense, 1889.

GIFFORD, A. f. A., 1886, Bd. 16, S. 187.

VAN HAAFTEN, Inaug. Dissert., Amsterdam, 1903.

HERTEL, A. f. O., Bd. 46, S. 630.

KLINGMÜLLER, Die ekzematösen Erkrankungen. Deutsche Klinik, 1905, S. 449.

KRAUSE, Conjunctivitis phlyctænulosa. Inaug. Dissert., Halle, 1905.

LEBER, VII ophth. Kongress zu Heidelberg, 1888.—*Ibid.*, Discussion on Axenfeld's paper. Bericht über die 26 Vers. der ophth. Ges. zu Heidelberg, 1897, S. 197.—*Ibid.*, Ophth. Kongress zu Heidelberg, 1901, S. 66.

MAYOU, The changes produced by inflamm. in the conjunct. London, 1905, p. 150 *et seq.*

MEIJERS, Über das Vorkommen von Staphylococcus pyogenes aureus bei den sog. skrofulösen Augenentzündungen. Inaug. Diss., Jena, 1898.

MICHEL, A. V., Contribution à l'étude bactériologique de l'ophthalmie phlycténulaire. Thèse de Bordeaux, 1898, u. Annal. d'oculist., t. 120, p. 257.

MICHEL, J. v., Z. f. A., 1900, Bd. 4, S. 102.

MORAX, Ann. d'oculist., 1897, t. 117, p. 361.

MÜLLER, L., Wiener med. Presse, 1901, Nr. 11 u. 12.

NIAS and LESLIE PATON, Ophthalmic Review, January, 1906, p. 27, and K. M. f. A., 1906, XXXIV, I, S. 81; Lancet, 1906, p. 1500.

REUCHLIN, Tuberkulin. K. M. f. A., 1906, XLI, Nr. 4/5.

SATTLER, VII internat. ophth. Kongress zu Heidelberg, 1888.

SCHMIDT, E., Sur les microorganismes du trachome et de quelques autres affections mycotiques de la conjonctive. Thèse de Saint-Pétersbourg, 1887.

SCHOLZ, Deutsche med. Woch., 1900, Nr. 29.

STEPHENSON, SYDNEY, Ophth. Record, 1900, p. 522.

STRAUB, Archiv f. Augenh., 1892, S. 416.—*Ibid.*, Nederlandsch Oogheelkundige Bydragen, 2 Aufl., 1896, p. 47.—*Ibid.*, A. f. O., 1905, LX, S. 165.

UHTHOFF, Berl. klin. Woch., 1900, Nr. 50.

WAGENMANN, Discussion on Axenfeld's paper in Heidelberg, 1897, 'Was wissen wir über die phlykt. Augenentzündungen?'

SECTION 9. TRACHOMA. FOLLICULAR CONJUNCTIVITIS.

The cause of trachoma is still quite unknown; neither in the secretions nor in the contents of the follicles[1] have any microbes been demonstrated which can be considered to have a causal significance. Even the most modern methods of staining have failed to give any positive result. The latest results of Halberstaedter, Prawoczek, and Greeff regarding the presence of very small granules do not furnish any explanation.

Halberstaedter, Prawoczek, and Greeff report that by means of the Giemsa stain, they have recently found fine red-stained granules. In many of the epithelial cells these granules coalesce and form bodies which cover the nucleus like a cap. Prawoczek states that they are certainly parasitic, and called them *Chlamydozoa;* Greeff is more reserved upon this point. For the present we must consider it doubtful whether these granules are parasitic in nature or not, and further research is necessary before we can say whether they occur so regularly in trachoma that they can be considered as of diagnostic value. The orang-outangs inoculated by Halberstaedter and Prawoczek did not show any enlargement of the conjunctival follicles, as did those of Hess, Römer, and Bajardi; contagiousness was presumed from the fact that the granules occurred in the epithelium of the inoculated orang-outangs, a conclusion which is by no means certain.

Meyerhof examined fresh cases of trachoma for the *Spirochætæ* by means of the Giemsa stain, and Stock examined sections by means of the silver methods; neither found anything definite. The ordinary saprophytes alone are commonly found, in some cases mixed with the common conjunctivitis organisms; it is, however, quite certain that these latter are not capable, even after prolonged activity, of producing a true trachoma, with scar formation and pannus.

This must be admitted, even though the common conjunctivitis organisms are found in large numbers in trachomatous secretion,[2] especially from the profusely secreting cases. This question has lately been discussed by Kartulis, Demettriades, Gasparrini, L. Müller, Kuhnt, Zur Nedden, Greeff, Junius, Axenfeld, Osborne, Morax,

[1] In order to divide the follicular material as finely as possible for purposes of culture, Morax ground it up with sterile quartz sand; he used every conceivable human medium, but without result.

[2] According to Mayou, trachoma secretion, in the early stages, contains more plasma cells than does that of any other form of conjunctivitis. Even in the tissues enormous numbers of plasma cells lie around the follicles.

A. Knapp, and Meyerhof, and the general opinion is that such cases are secondary infections, and that after their subsidence the trachoma will again quietly appear, or develop independently. Such mixed infections, especially with the Koch-Weeks bacillus, the *Pneumococcus*, and the *Gonococcus*, give trachoma the appearance of an acute catarrh, though such is not its true nature. In different places the nature of the secondary infection varies, and with it also the severity of the secondary catarrh. De Lietro-Vollaro found the *Diplobacillus* very frequently in Naples, Gasparrini found the *Pneumococcus* in Siena, and Rymowicz the same organism in Kasan. In the large series of cases collected by Lakah and Kouhri (1902) in Egypt, this last organism, in proportion to the Koch-Weeks bacillus and the *Gonococcus*, was not so common. Meyerhof has lately written to me that he found (1906) the *Diplobacillus* in 20 to 30 per cent. of all the trachoma cases in Cairo. The conditions may have changed in this respect.

Recent work on this subject has shown that acute trachoma is a disease which begins acutely with profuse secretion, and in the majority of cases is not a pure trachoma, but a mixed infection with an acute catarrh. Only a few authors (Saemisch, Peters) report that the acute onset of trachoma without the presence of conjunctivitis organisms occurs freely in their districts. Uncomplicated trachoma most generally begins and continues insidiously. Simple harmless conjunctival follicles, such as are often found in school-children, may give the impression of trachoma when they have associated with them an acute catarrh—*e.g.*, a pneumococcal[1] or a Koch-Weeks infection. If we wait till the acute catarrh has subsided, it is then obvious whether a trachoma is present or not.

An examination of the secretion is therefore indispensable, and it is only when such infections have subsided that an opinion can be formed with regard to the nature of the follicles.

It is because of the frequency of this associated acute catarrhal infection that relatively to Europe, trachoma in Egypt is more commonly of the acute 'watery' type. There is no proof that at the commencement of the previous century pure trachoma presented clinical features at all different from those which we see at the present day, although it may have shown a more 'blennorrhœal' course.

There is no proof that some of these secondary infections were not

[1] In the case of the conjunctiva, the occurrence of an 'antagonism' between trachoma and the *Pneumococci*, such as is stated by Augstein to occur (*Z. f. A.*, 1906, xvi. 243) in the cornea (*cf.* section on 'Keratitis'), cannot be proved.

present. What was called 'Egyptian ophthalmia' was not a definite clinical picture. The records so freely quoted about ships, which, on account of such conditions, could hardly reach port, are much more likely to relate to attacks of acute Koch-Weeks conjunctivitis than to pure trachoma; similarly the large epidemics breaking out in armies may be explained. The literature on this point requires critical revision.

From the work of Koch, Kartulis, and Demettriades, and from the more prolonged researches of L. Müller, Morax, Lakah, and Kouhri, who used every aid available, it is clear that trachoma in Egypt is very commonly associated with gonorrhœa and Koch-Weeks infection, the latter of which is there almost pandemic, like the trachoma itself (*cf.* section on 'Koch-Weeks Bacillus'). *Diplobacilli* are not uncommon; *Pneumococci* are the least important. Mixed infections with these organisms are common. It is the gonorrhœal mixture, not the pure trachoma, which causes so much blindness. It is not unlikely that such infections, more or less intermixed with trachoma, were introduced by the returning soldiers of the Napoleonic wars, and were the cause of the acute epidemics. The remarkable increase in the frequency of this form of catarrh in Egypt during the hot season has already been mentioned (p. 137); it varies in North and South Egypt (Meyerhof), and the prevalence of the *Gonococcus* (July to October) does not coincide with that of the Koch-Weeks (May to July).

It is naturally quite possible that, in lands where trachoma is endemic, a true trachoma can follow on a catarrhal conjunctivitis (*e.g.*, one due to the Koch-Weeks bacillus), seeing that the catarrh presents a favourable opportunity for the transference of the trachoma virus. The Koch-Weeks bacillus in these cases is not the true cause of the trachoma, as is clearly shown for this organism, and also for others, by the fact that inoculations with pure cultures have never produced a trachoma.

Gromakowski is opposed to this view; he attributes the condition to the Koch-Weeks bacilli, which he so commonly found.

Piringer, and more recently Goldzieher and Hoor, insist that a gonorrhœal infection is capable of producing a trachoma. This cannot be considered as proven, provided that we understand this statement to mean that the gonorrhœal infection is the direct cause of the trachoma, and not merely that it prepares the way for it. It must be admitted that in many cases the sequence is very striking (Goldzieher, Sattler). One of Hoor's cases is especially noteworthy: 'Gonorrhœal urethritis, severe unilateral ophthalmo-blennorrhœa, ending in papillary

trachoma.' Three weeks after the commencement of the blennorrhœa on the right side, a typical granular trachoma appeared on the left side. In the secretion of both eyes were *Gonococci* (Gram stain was not used). Such a question as this cannot be decided in a trachomatous country like Hungary, where the possibility of a simultaneous infection with trachoma cannot be excluded. It is noteworthy that in countries free from trachoma such cases are not recorded. This is opposed to the view that gonorrhœal secretion can produce a trachoma.

The older records of the onset of trachoma with blennorrhœa,[1] or of trachoma as the direct result of gonorrhœa, can be explained thus: A blenorrhœa—in many of the cases only a Koch-Weeks conjunctivitis—may have complicated a trachoma, or else the papillary condition of the conjunctiva, which persists for some time after a gonorrhœa, and resembles the so-called papillary trachoma, may have been mistaken for it. This 'post-blennorrhœal conjunctivitis,' as it has been called by L. Müller, is not identical with trachoma, but disappears without any scarring or the formation of a typical trachomatous pannus. It was customary for many text-books to use the term 'chronic blennorrhœa' as a synonym for certain forms of trachoma; this still persists in some modern books. If by it we are to mean a gonorrhœal infection, then there is no proof that such a statement represents the facts. Meyerhof's statement that in many trachomatous cases *Gonococci* could be demonstrated for a long time after the subsidence of the inflammation, and could cause its recurrence, is not a proof of the gonorrhœal etiology of trachoma (these records should have been controlled by cultures to exclude the other Gram-negative cocci). Meyerhof also considers that these are secondary infections.

Infection with the Koch-Weeks bacillus can lead, in chronic cases, to a hypertrophy of the conjunctiva, especially the tarsal portion. Weeks and Morax first described this, and the question has since been more fully studied by Hoffmann. This, however, is not a true trachoma, and does not lead to its characteristic complications.[2]

Micro-organisms, designated 'trachoma cocci,' have been found by Michel and Sattler, and more recently by Goldschmidt, Stadarini,

[1] Trachoma was exclusively considered as due to a blennorrhœal urethral secretion.

[2] Several observers have expressed the hope that a secondary infection with *Pneumococci* might act curatively in cases of trachoma (Ferri, Gasparrini, Rymowitsch; see chapter on 'Pneumococcal Conjunctivitis'). Nothing has yet been brought forward to prove this. It is improbable that *Gonococci* have this action, and their toxins certainly have no curative action (Morax and Elmassian). These various forms of irritation have only been shown to have a clearing effect in many cases of pannus, analogous to the action of jequirity (Wecker) and jequiritol (Römer). An improvement in a trachoma has been occasionally observed from an intercurrent erysipelas (Bäck).

Kucharski, Wittram, Wilbrand, Saenger, and Staehlin; they are not constant (Schmidt-Rimpler), and are not the cause of the condition. In an epidemic, which he later called a 'conjunctivitis folliculosa,' Michel observed in the secretions Gram-positive *Diplococci*, belonging to the staphylococcal group, and resembling *Gonococci*.

Seeing that Sattler as well as Michel reports the production of follicles by the inoculation of these cocci on to the scarified conjunctiva, we can attribute to them some definite pathogenicity for a damaged conjunctiva. But even these authors no longer consider them to be the cause of trachoma (*cf.* 'Staphylococcal Conjunctivitis'). Wilbrand, Saenger and Staehlin frequently found these cocci along with a yellow variety, and also the Koch-Weeks bacillus: they attribute the power of producing follicles to them. They, however, rarely record appearances like trachoma. When forming any conclusion regarding these findings, we must bear in mind that both of these epidemics of follicular conjunctivitis occurred in districts in which true trachoma is almost never seen.

Shongolowicz considered that the cause of trachoma was the *Bacillus xerosis;* Noiczewski attributed it to the mould fungi;[1] Burchardt thought that the goblet cells of the conjunctiva were Protozoa; and Elze considered the cell detritus to be parasites. These ideas have long since been put on one side. The latest records by Elze (*Woch. f. Ther. u. Hyg. d. A.*, 1905, p. 18) concerning 'Fungi Imperfecti in the Secretions of the Eye' only refer to the casual occurrence of a contaminating organism of the Cryptogam family. Krudener described peculiar cell inclusions in the large cells of the trachoma follicles; these, on account of their molecular movements, he called 'Körperchenzellen' or 'Wimmelzellen.'[2] It is doubtful whether they really have a parasitic nature, as Leber has found the same appearance in the follicles of the normal conjunctiva. Similarly, we cannot accept Santucci's views that the *Streptothricea* have a causal connexion with trachoma.

The importance of the ultra-microscopical results reported by Raehlmann and Santucci is very doubtful (*cf.* the statement about the Halberstaedter and Prawoczek bodies). The larger examples of the bacilli described by Raehlmann were not ultra-microscopical,

[1] In a later work (1905) he calls his organism a variety of leptrothrix, the *Microsporon trachomatosum*, which lies around the trachoma follicle, while its fructification organs are in the interior of the granule, and form the hyaline bodies. It is obvious that Noiczewski has mistaken histological tissue changes for fungi. As a matter of fact, no such organisms are present.

[2] Literally, 'granule cells' or "swarming cells.'

and should have been obvious in the previous examinations. Without having demonstrated them in a stained smear, Raehlmann asks whether they are identical with the Müller bacillus. We know just as little about the relation of these organisms to the saline extract of the follicles as we do of their cultural peculiarities. Information on both of these points is essential for control tests. The nature of the 'Protozoa-like' bodies which he described is still undetermined. No definite information is obtained from the ultra-microscope with regard to the finest structure of the individual particles; they are only to be seen as points of light. The rapid movement of the bacilli, as well as of the other bodies, cannot be said to be motility in the ordinary sense of the word. Pfeiffer and Kuhnt deny the possibility that the cause can be in these ultra-microscopical bodies, as an infusion of granulations when filtered and inoculated on the healthy conjunctiva will not cause any inflammation. This is not absolutely conclusive, as the immediate transference of trachomatous secretion does not always cause a trachoma (*vide infra*). The fact that Hess and Römer, with the filtrate of an emulsion, which unfiltered was active, obtained a negative result on apes, is of definite value. Similar inoculations of apes by Bajardi were negative, though with the unfiltered material an inflammatory reaction very like trachoma was produced. Raehlmann does not claim to have definitely proved their causal nature, but he attributes a considerable importance to the bacilli, though that is not even shown to be likely (*cf.* p. 261).

The small bacilli which L. Müller has shown to be present in such a large number of cases, and which resemble the influenza bacillus in every particular, are not the cause of trachoma. They are inconstant in their presence, and in many fresh untreated cases cannot be found. This represents the general opinion of authors who, with every possible assistance, have studied such trachoma cases for years. The fact that C. Fränkel and Morax also agree with this view adds to its importance. I have searched in vain for these bacilli in untreated fresh cases of trachoma. A. Knapp and Luerssen also report that they have found them very irregularly in fresh untreated cases, and that their presence bore no relation to the profuseness of the secretion.

It is specially important to note that Luerssen made three negative inoculations on the human conjunctiva with freshly-grown Müller's bacilli from such cases. Only a slight transient irritation occurred and no trachoma. Such bacilli have also been found by Zur Nedden, Jundell, and myself in cases which had no resemblance to trachoma.

When the Müller bacillus occurs in a case of trachoma, it appears that we have to deal with a mixed infection. The relations to the Koch-Weeks bacillus are given in the chapter relating to that organism. L. Müller himself admits that there is no definite proof of an etiological significance for his bacillus.

The opinion held by Truc, Cazalais, Gromakowski, and Bäck that, in people with a predisposition (lymphatic persons), any irritation, continued for a long enough time, can lead to trachoma, must be considered as highly improbable. The large experience which we have collected with regard to conjunctivitis points in exactly the opposite direction. This is beautifully shown in the case of diplobacillary infection. This eminently chronic affection can exist for years, even in scrofulous persons, without giving rise to the slightest sign of trachoma. When, in trachomatous districts, it is associated with a trachoma, there is no demonstrable etiological connexion between the two conditions.

Everything is in favour of trachoma being a specific infectious disease, the cause of which is not yet determined. Under this name we should not include every case of follicle formation, but only those granule formations in the conjunctiva which, in typical cases, begin insidiously, and finally fill the whole conjunctiva with granulations, gradually leading to scarring, and very often to the well-known pannus trachomatosus.

Though we still find persons opposed to the contagiousness of this disease, it is established beyond all doubt. There are positive inoculations (Sättler) to prove it. Addario and Greeff transferred trachomatous excised follicles into the scarified conjunctiva of blind persons. In three or four days the hyperæmia began, and after about eight days the infiltration; the inflammation passed to the other side. By rubbing fresh trachomatous material into the conjunctiva of apes, Hess and Römer produced a dense formation of follicles. (This inoculated affection could be transferred to a second ape for six to seven weeks, but not later.) When the affection spread to the other eye no follicles formed there, but microscopically a few granules were to be seen. No reaction was produced by the Berkefeld filtrate of ground-up material, which acted vigorously on direct inoculation. When the ground-up material is heated to 58° to 63° C. no infection results. Every attempt made by these authors to stain Bacteria or Protozoa was fruitless. Scar formation and other complications have not yet been observed in these animals. Bajardi reports positive inoculations in the *Macacus* and *Cercopithecus*. He either planted a piece of trachomatous tissue

into a pouch made in the ape's conjunctiva, or he injected subconjunctivally an emulsion of the trachomatous material. The inflammatory symptoms at first subsided, but from the second week onwards a granular inflammation occurred, lasting a long time, and spreading to the plica semilunaris and conjunctiva bulbi. He did not observe cicatrization.

We also know of many cases in which doctors have been infected when treating cases (*cf.* the statistics of Wurdemann, Duprez, and Poulard). I am personally aware of two such. The view brought forward by Straub that generally it is only contagious for children cannot be accepted, although infection in childhood is more common than is commonly supposed. Ewetzky confirms this for Russia, and Müller and Morax for Egypt. The disease presupposes the transference of the secretion, and therefore it may remain isolated in many cases. The contagiousness also is not the same in all stages. In many families living in close contact it is often found that in the course of years only a few persons—or, indeed, a single person—are affected, and that, too, when they are sleeping together in the same bed.

We cannot deny the influence of personal disposition. The severity of the attacks also may vary in different epidemics, and in exceptional cases trachoma will remain one-sided. The experiments of Germaix are of considerable value; especially interesting were his attempts, in unilateral cases, to infect the healthy eye with the contents of the follicles from the diseased one, either through rubbing in or subcutaneous injection. This was never successful; there appeared to be a unilateral immunity. Germaix has also repeatedly inoculated his own conjunctiva with trachomatous secretion without result. Similarly Bäck reports (*Munch. med. Wochen.*, 1900, Bd. i., S. 256) that he has often inoculated his own conjunctiva with trachomatous secretion, in every instance without any result. Bäch lays special emphasis on the personal factor in predisposition, and considers that it is especially due to the presence of scrofula, as was previously claimed by Arlt, Panas, Truc, and others. (The complete literature of this subject is to be found in the paper by Duprez.) It is certain that such a condition does conduce to the infection, and can influence the course of the disease. The racial predisposition,[1] considered so important by Chibert and others, has not the great importance attributed to it, and the statistics on which their views are based are

[1] On this question, see my review in the 'Ergebnisse,' Lubarsch and Ostertag, section 'Bakterologie des Auges,' 1894-99. The literature is given there.

very insufficient. Much of what has been stated with the certainty of law on this subject has been definitely proved untrue, as, for instance, the alleged immunity of the Celts; and with regard to the other trachoma-free races, it is doubtful whether they really have had any considerable opportunity for infection. This is the case with regard to the alleged immunity of the coloured people in North America (who generally live by themselves), for it has been shown (van Milligan) that people of the same negro races in Europe and Asia are often severely affected. Climatic considerations, especially height above the sea-level, are greatly exaggerated. Low-lying land near rivers and marshy places do appear to be particularly affected, especially in certain countries. In his historical account of trachoma Hirschberg lays particular emphasis on this point, and asks whether the trachoma virus may not be closely related to that of malaria.

It has often been suggested that some attenuation in the virulence of trachoma occurs through adaptation in affected races, but it is doubtful if such be the case. Certainly at the commencement of the nineteenth century, after the Napoleonic campaigns, severe acute catarrh was more frequently observed; but this can have been quite well due to the more frequent and epidemic occurrence of the mixed infections referred to above, as, indeed, is the case at the present time in Egypt. The opportunities for infection, and the hygienic conditions which would favour the transference of the infection and intensify the severity of the disease when established, are all important factors.

A condition of affairs opposed to this idea is seen in many parts of Germany (Rhine Valley and Westphalia), where trachoma is diminishing. It is very doubtful whether this is not essentially due to a better hygiene and the spread and improvement of medical attention, rather than to the trachoma becoming worn out and extinct. The supposition brought forward by Peters that the tendency to infection by the ubiquitous trachoma virus is decreasing is also purely hypothetical. Thus ubiquity attributed to the trachoma virus is in the highest degree unlikely, as experience shows that trachoma has always been introduced, and that it forms groups of cases where none were previously present. The indigenous population are naturally only infected when they come into sufficiently close contact with the diseased aliens; and where this contact does not occur, or does so only to a very limited extent, only very few cases occur among the indigenous population.

Junius and Schmeichler have rightly shown that this excessive

emphasis on disposition, carried beyond any justification by the facts of the case, is not in the interest of the truth, and tends to minimize the importance of the specific infectiousness of the disease, and its definite introduction in the individual case.

Acquired immunity cannot be demonstrated, reinfections are not uncommon, and a trachoma which has long been in a state of quietness can break out again.

No life-period is proof against trachoma in any trachomatous district. The particular age at which infection most commonly takes place naturally depends on the local conditions, and will vary in different localities. The view is gaining ground that in many trachomatous countries the disease is acquired in early childhood. This is stated to be the case in Amsterdam (Straub), for the greater part of Russia (Ewetsky and others), and particularly for Egypt, where large series of experiments by L. Müller and Morax have shown that in children of the first year trachoma is already widespread, and, as in adults, is often combined with other infections. The previous assertion that children have a low susceptibility is not correct.

It is doubtful whether any disease corresponding to trachoma affects any of the other mucous membranes. The lacrymal sac alone appears to be affected with true trachoma. The occurrence of single follicles is not infrequent in simple dacryocystitis, but when they occur in the enormous numbers which Kuhnt, Raehlmann, Wernеke, Ischreyt, Cirincione, and Basso found, they can be considered as a sign of trachoma. This is just as valid a diagnosis as is made in the case of the conjunctiva, as there, too, non-trachomatous follicles are frequently enough seen in other forms of irritation. It is very strange that the conjunctiva of the lacrymal sac is only affected in a proportion of the cases, although in them all the infectious secretion comes in contact with it. A case reported by Stock favours the spread of trachoma in the subepithelial adenoid tissue of the tear passages. This case is figured on p. 280 to show the enormous masses of the *Pneumococci* which lie in the lumen of the canal. The specimen was a fresh post-mortem one from a case of severe trachoma with a diffuse infiltration, which had broken through the epithelium at one point. Besides this, there was a fresh dacryocystitis with a few follicles. In the secretions of dacryocystitis in trachomatous cases *Pneumococci* are often seen. In spite of this, an ulcus serpens in such cases is very rare, although disturbances of the epithelium are very common. Uhthoff and Axenfeld consider that this is due to the frequent vascularization of the cornea being unfavourable to the development of an

ulcus serpens. Augustein (*loc. cit.*), on the other hand, thinks that it is due to an antagonism between trachoma and *Pneumococci.*

Whether a true trachoma of the nasal mucous membrane occurs, as claimed by Küht and Hoffmann,[1] must remain uncertain as the nasal changes which so often occur in trachomatous persons do not present any special clinical peculiarities. Basso considers that the follicular affections which occur in other parts of the body—*e.g.*, in the pharynx—have a direct etiological relationship to trachoma. This is very unlikely, although Peters has shown many points of similarity in their histology.[2]

So long as we do not know what is the cause of trachoma, it is manifestly impossible, even in the conjunctiva, to define this disease with exactness, and to determine whether there are abortive cases, as Peters claims, in which follicles are not formed. There is no proof of the existence of these follicle-free cases of trachoma, and with regard to epidemiological questions this hypothesis can for the present be neglected, as experience shows us more and more that an infection with a trachomatous secretion will always cause a follicular affection. In the same way the discovery of the cause alone will show what is the relationship between mild follicular affections of the conjunctiva and true trachoma. This much we know for certain : that many forms of irritation—chemical, mechanical, physical, and infectious—can lead to the formation of follicles which are not contagious, and have nothing to do with trachoma.

The so-called 'school follicle' ('Schulfollikel,' Cohn, Schmidt-Rimpler) is an example of the non-infectious, or rather non-contagious, forms of follicle formation; this is very often seen in children of the school age. It occurs without any special irritation, and has often been mistaken for trachoma. Greeff and Mayweg have shown that the introduction of such follicles on to the healthy conjunctiva does not produce any reaction. It appears that the majority of these follicle formations in the conjunctiva are the result of chemico-physical insults (dust, foul air, over-strain, etc.), acting simultaneously on many people, especially school-children, and thus giving the impression of an epidemic affection. Saemisch called this latent form 'folliculosis conjunctivæ,' to distinguish it from 'conjunctivitis folliculosa,' in which inflammatory symptoms are much more pronounced in the conjunctiva. With the secretion of a conjunctivitis folliculosa which had developed in a cavalry regiment, Samperi made many inoculations of the human conjunctiva. These

[1] Inaug. Dissert., Königsberg, 1906. [2] *K. M. f. A.*, 1902, xl. 1, p. 497.

were without effect, as was also the transference of an excised follicle into his own conjunctiva. Samperi found in the secretions of these follicular cases, along with *Staphylococci*, very many *Bac. mesentericus* and *Bac. subtilis*, which were also present in the dust from the horses; he therefore referred the disease to the action of this dust. The *Staphylococci* were only secondary to the presence of the follicles. This was, of course, not an infectious disease.

Béal made three inoculations with the secretions of an acute conjunctivitis folliculosa, and only once obtained a slight follicular affection, which disappeared in a few days. He, nevertheless, considered the disease contagious, on account of its rapid transference from one eye to the other. The actual infection must, however, take place in some other way.

Benign infectious follicular affections of the conjunctiva do also occur, and we are not sufficiently well acquainted with their cause. The findings which Michel, Sattler, Basevi, Wilbrand, Saenger, and Staehlin (Gram-positive cocci) report were only in a few of such epidemics. The consideration of these findings has already been discussed. They were the more acute epidemics in the course of which follicles had formed. As I have already mentioned in the chapters on the organisms in conjunctivitis, transient follicular formation has been observed in infections with *Diplobacilli*, *Pneumococci*, and *Streptococci*. Among the benign, chronic, and almost latent follicular epidemics with negative bacterial findings, there are cases which can be transferred by inoculation, and which, therefore, can be infectious. I have proved this on myself. I have had an excised follicle introduced into my own conjunctiva, where, after a ten days incubation period, a progressive follicular formation occurred; in about four weeks it passed over to the other side, affecting the upper and the lower fornices. The condition lasted for about eighteen months. A condition endemic in an orphan asylum was found to differ from trachoma in that the cases always healed spontaneously, without leaving scars, and without having produced in a single case any of the well-known complications of trachoma. My own inoculated conjunctiva spontaneously returned to the normal without any changes. It is not likely that in these cases an 'attenuated' trachoma was present.

Only the discovery of the cause of trachoma will bring certainty in these investigations, and to this end we must use new culture methods, as the finest of our present ones have completely failed.

LITERATURE.

ADDARIO, A. f. A., 1900, Bd. 41, and Progresso ophthalmologico, 1906, S. 347; K. M. f. A., November and December, 1906, Bd. II.

AUGSTEIN, Z. f. A., 1906, XVI, S. 243.

AXENFELD, Discussion on Leber's paper, Ophth. Gesellsch., Heidelberg, 1896; also Trachom., Freiburg, 1902, Speyer und Kärner; and 'Ergebnisse der path. Anat.' (Lubarsch-Ostertag), 1894-99.

BAJARDI, La clinica ocul., 1906, VII, p. 2661, and 1907.

BASERI, Ann. di Ottal., 1889, XVII, p. 493.

BASSO, La clinica ocul., 1906, VII, S. 2663 u. 2664.

BEAL, Conjonctivite aigue avec follicles. Ann. d'ocul., 1907, CXXXVII, p. 1.

BOLDT, Trachom. Bibl. v. Coler, 1903. (Trans. Parsons and Coats, London.)

BURCHARDT, Zentralbl. f. prakt. Augenn., 1897.

CAZALIS, Études bactériologiques de la conjonctivite granuleuse. Thèse de Montpellier, 1895.

DUDZINSKI, MICHEL-NAGEL, 1900, S. 263.

DUPREZ, Sur la conjonctivite granuleuse monoculaire. Thèse de Lille, 1904.

FRÄNKEL, C., Hygienische Rundschau, 1899, Bd. 21, 2.—*Ibid.*, Zeitschr. f. Hyg. u. Inf., 1899, S. 221.

GERMAIX, De la non contagion des granulations. Recueil d'ophth., 1902, XXIV, pp. 234-239.

GOLDSCHMIDT, Zentralbl. f. klin. Med., 1887, Nr. 18.

GOLDZIEHER, Die Pathologie des Trachoms. Berl. klin. Wochenschr., 1905, Nr. 41.

GONIN, Rev. med. de la Suisse Romande, 1879, p. 89.

GREEFF, Klin. Jahrbuch, 1898, Bd. 7, and Lehrbuch der pathol. Anatomie des Auges. Berlin, 1902 (A. Hirschwald), S. 32 *et seq.* Also Deutsche Med. Woch., 1907, p. 914.

GROMAKOWSKI, A. f. A., 1900, XLI, 2.

HALBERSTAEDTER and PRAWOCZEK, Über Zelleinschlusse parasitarer Natur beim Trachom. Arb. aus dem Kaiserl. Gesundheitsamte, 1907, XXVI, p. 44.

HESS and RÖMER, Übertragungsversuche von Trachom auf Affen. Arch. f. Augenh., 1906, LV, S. 1.

HIRSCHBERG, Die Conjunctivitis granulosa. Klin. Jahrbuch, 1897, Bd. 6.

HIRSCHBERG and KRAUSE, Zentralbl. f. prakt. Augenh., 1881, S. 39 and 270.

HOFFMANN, Statistik über 3000 Fälle von Conj. gran. Inaug. Dissert., Königsberg. See here the literature of Trachoma of the Lacrymal Sac.

HOOR, K. M. f. A., 1895, S. 107.

JUNIUS, Z. f. A., 1905, XIV, S. 452, and Münch. klin. Wochenschr., 1905, Nr. 16.

KARTULIS, Zentralbl. f. Bakt., 1887.

KNAPP, A., A. of ophth., XXXIII, 1904, S. 463.

VON KRÜDENER, Petersburger med. Wochenschr., 1895, S. 451.

KUCHARSKI, Zentralbl. f. A., 1889, S. 225.

KUHNT, Die Conjunctivitis granulosa. Klin. Jahrbuch, 1898, Bd. 7.

KUHNT-PFEIFFER, Z. f. A., 1905, Bd. 13, S. 321.

LAKAH and KOUHRI, Ann. d'ocul., 1902, T. 128, S. 420.

LEBER, Ophth. Kongress in Heidelberg, 1896.

LOGETSCHNIKOW, Michels Trachomkokken (quoted by Saemisch).

LUERSSEN, A., Bakter. Unters b. Trachom. Zentralbl. f. Bakt., Originale, 1905, XXXIX, S. 678, and Z. f. A., 1905, XIV, S. 443.

MEYERHOF, Die akuten eitrigen Bindehautentzündungen in Ägypten. Klin. Monatsbl. f. Augenh., 1905, XLIII, Bd. 2, S. 216 (see here the literature), and Ann. d'ocul., November, 1906, II.

MICHEL, A. f. A., 1886, S. 348.
MORAX, Rercherches cliniques et bactériologiques sur la conjonctivite granuleuse d'Égypte. Paris, 1902, J. Therenot, and Encyclop. d'opht., 1905, V, Maladies de la conjonctive.
MÜLLER, L., A. f. A., 1899, Bd. 40, S. 13. Wien. ophth. Ges., 1905 (Z. f. A., XV, S. 88).
NOISZEWSKI, Zentralbl. f. prakt. Augenh., 1891.—*Ibid.*, Ein Beitrag zur Pathologie des Trachoms. Postemp okul., 1890, Nr. 9 (reviewed in Ophth. Klinik, 1906, S. 377).
OSBORNE, A. f. A., 1901, XLIV, S. 89.
PETERS, Münch. med. Wochenschr., 1903, Nr. 3, und 1905, Nr. 1 and 24.
POULARD, La contagiosité du trachome. Soc. d'opht. de Paris. K. M. f. A., 1905, I, S. 433.
RAEHLMANN, Naturforschervers. Hamburg, 1901. — *Ibid.*, Ultramikroskopische Untersuchungen. Beiträge z. Augenh., 1905, 62, S. 38.
SAEMISCH, Erkrankungen der Bindehaut. Handbuch II. Aufl., 1905, S. 102.
SAMPERI, Arch. di Ottalm., 1902, X, p. 106, and 1906, XIV, p. 24.
SANTUCCI, La clinica ocul., 1906, VII, p. 2676.
SATTLER, K. M. f. A., Bericht über ophth. Kongress, Heidelberg, 1881, 1882.
SCHMEICHLER, L., Bemerkungen zur Trachominfektion. Wien. klin. Wochenbl., 1903, XVI, S. 1247.
SCHMIDT, E., Mikroorganismen bei Trachom. Inaug. Dissert., Petersburg, 1887.
SCHMIDT-RIMPLER, Verhandl. internat. ophth. Kongress, 1888, p. 395 (Heidelberg). —*Ibid.*, Schuluntersuchungen, Leipzig, W. Engelmann, 1890. Lehrbuch, 1, 7 Aufl.
SHONGOLOWITSCH, St. Petersburger med. Wochenschr., 1890, S. 28.
STADERINI, Ann. di Ottalm., 1887, XVI, S. 367.
STRAUB, Geneeskundige Bladen, 1904, Nr. 7, and Z. f. A., 1906, XV, S. 75.
WERNCKE, Ätiologie der Dakryocystitis acuta. Inaug. Dissert., Dorpat, 1900.
WILBRAND-SAENGER-STAEHLIN, Mitteilungen aus den Hamburger Staatskrankenhäusern, 1894, Bd. 3.
WITTRAM, Inaug. Dissert., Dorpat, 1889 (reviewed in Zentralbl. f. A., S. 65).
WÜRDEMANN, La conj. gran. monoc. Ann. d'ocul., 1896, CXV, p. 344.

CHAPTER VII

THE LACRYMAL APPARATUS

Dacryocystitis.

THOUGH the mucous membrane of the lacrymal sac is in immediate continuation with that of the conjunctiva, still it does not react in the same way to the causes which produce disease.

The majority of the infectious diseases of the conjunctiva pass the lacrymal sac by without affecting it, although the organisms which produce them pass through the sac in large numbers. We can only presume that, on account of frequent downward evacuation by the lid movements, the material which enters it cannot gain a footing. The importance of this is shown by the fact that, when there is a stenosis of the nasal duct and the flow of the secretion is prevented, a catarrhal inflammation soon occurs. This, however, does not explain all the facts, for during the course of a gonorrhœa of the conjunctiva the sac is filled for weeks with infectious material; we must rather assume that the mucous membrane of the lacrymal sac possesses quite different 'affinities' or receptors. It is more nearly related to the mucous membrane of the nose than to that of the conjunctiva, and is relatively immune to the *Gonococcus* and the Koch-Weeks bacillus. An inflammation of the lacrymal sac in the course of these affections is well known to be extremely rare, and in the exceptional cases in which it does occur, an examination should be made to see whether there is not a mixed infection with some other bacteria, or some special condition present. An inflammation of the lacrymal sac with *Diplobacilli* is also very rare; I have exceptionally found *Diplobacilli* to be the only bacteria present in the lacrymal sac.

If we consider the facts and the results of bacteriological examinations, we find that *Pneumococci*, either pure or mixed with other organisms, are the most common organisms present in a simple catarrhal dacryocystitis; next in the order of frequency are the *Staphylococci* then perhaps the Gram-negative bacilli of the influenza

group, then the *Streptococci* and the other pyogenic bacilli. *Staphylococci* are rather common in small numbers, as casuals along with other organisms; but it is rare to find them in pure culture, or so in excess that they could be taken to be causal. None of these infections will attack the lacrymal sac unless they are fixed there by some predisposing factor. Any stoppage of the duct, especially one which is due to nasal conditions, has an important influence. Voelkers and Rehr lay stress upon injuries to the mucous membrane due to small foreign bodies which pass down from the conjunctiva. Individual variations in the nasal duct have also a predisposing influence. Cases of catarrhal dacryocystitis primarily due merely to the introduction of the last-named irritant are quite rare. Cases are quite common in which a transient obstruction occurs due to the infected mucous membrane swelling up, and in which complete healing can be obtained by simply washing out the sac. Even in these cases I have mostly found *Pneumococci.*

A primary infection must be presumed in many of the cases of tuberculosis of the sac in which no changes can be found, either in the nose or in the surrounding parts. It is quite impossible to say whether these infrequent cases may not be endogenous. (I consider that endogenous tuberculosis of the conjunctiva is not such an extreme rarity.) Considering the experiments of Valude (see 'Wound Infection,' p. 78), it seems hardly possible that a healthy sac with a normal passage can be infected by tubercle from without. A 'primary tuberculosis of the lacrymal sac' in many cases may develop ectogenously on the basis of a previous stenosis or a simple dacryocystitis.

Not uncommonly the tuberculosis arises from a lupus of the nasal mucous membrane finding its way upwards. In many cases the dacryocystitis in a nasal tuberculosis is really non-tubercular, and merely a simple inflammation due to the retention of the secretions (Jaulin, Ginsberg, Shiba, *K. M. f. A.*, 1905, Beilageheft, Axenfeld, *Med. Klin.*, 1906, No. 7). Even a dacryocystitis complicating a tuberculosis of the conjunctiva (see here the literature) need not necessarily be tubercular (A. Levy).

Seeing that tubercular dacryocystitis cannot always be diagnosed as such clinically, Morax recommends that the secretion should be stained for the tubercle bacilli. This, however, is not always a certain method, as a negative result will often occur in tubercular cases.

Trachoma seems to have more affinity for the lacrymal sac, although primary trachoma of the lacrymal sac has rarely been demonstrated.

In the chapter on 'Trachoma' it has been shown how a complicating dacryocystitis is often trachomatous. Kuhnt, Werncke, Raehlmann, Ischreyt, and Basso found microscopically so many follicles in the sac that trachoma could be certainly diagnosed.

The hypothesis that there is really a true trachoma of the sac is not contradicted

by the fact that follicular formation is sometimes found normally in it, just as in the conjunctiva we meet with simple and trachomatous follicular formation.

Rochon-Duvigneaud and Tartuferri's denial of 'trachoma of the sac,' because follicles are also found under normal circumstances, is not justifiable. Weber,[1] Moauro,[2] Kalt,[3] De Vincentiis, and Cirincione[4] have demonstrated the presence of follicles which they consider to be trachomatous A primary trachoma of the lacrymal sac can also develop.[5] The means by which the affection is transferred from the conjunctiva into the lacrymal sac is radically different from that of any other form of conjunctival inflammation, in that the trachomatous follicular infiltration spreads along the canaliculi under the epithelium; I have preparations from Dr. Stock in which this canalicular infiltration is very easily seen (*cf.* Fig. 52).

This must not be taken to mean that all cases of dacryocystitis in granular conjunctivitis are necessarily trachomatous; many of them are simply catarrhal. The bacteriological examination of the pus from these cases of trachoma of the sac gives the usual findings. According to Augstein,[6] *Pneumococci* are the most plentiful, and L. Müller emphasizes the frequency of the influenza bacilli, which are commonly found in the sac under other conditions.

For the present it is doubtful to what extent the changes which occur in the nose in trachomatous patients, and are especially common when there is also a dacryocystitis present, are specifically trachomatous.

The great importance of the diseases of the nose, with regard especially to affections of the lacrymal passages, is due to the fact that changes in the nose by an ascending swelling in the nasal duct (*cf.* the literature by Eversbusch, second edition of the Saemisch Handbook, 1905), or through a stricture, mechanically obstruct the outflow. Nasal bacteria cannot ascend the healthy nasal duct (Bach), and even in the presence of stenosis and dacryocystitis no ascent could be experimentally demonstrated to take place (Hauenschild). Nevertheless, with an ascending inflammation of the mucous membrane *in continuo*, an upward spread of the organisms appears possible, provided that they are not being freely removed.

Affections of the neighbouring sinuses (ethmoid, frontal, and maxillary) can also involve the lacrymal sac, chiefly because an acute collateral hyperæmia or toxic irritation spreads to the tear passages, producing stenosis and catarrh. With the healing of the original sinus trouble such a condition may immediately disappear. Sinus affections can occur in simple chronic lacrymal catarrh (Kuhnt, etc.), but they are uncommon. On the other hand, in the acute forms, and when a fistula is present, an adjoining sinusitis is common (Peters and Hammer).[7] The relationship varies: the inflammation of the sac may spread to the ethmoidal sinus, and vice versa.

From the bacteriological point of view it is noteworthy that, in the

[1] *A. f. O.*, 1861, viii. 105, Bd. 2.
[2] *Ann. di Ottal.*, 1890, xix. 377.
[3] *Rec. d'Ophth.*, 1894, p. 370.
[4] *Ann. di Ottal.*, 1890, xix. 362.
[5] See the dissertation of W. Hoffmann (Königsberg i/Pr., 1896), under Kuhnt, giving statistics of over 3,000 cases of conjunctivitis granulosa.
[6] *Zeit. f. Aug.*, 1906, xvi. 243.
[7] Hammer, Inaug. Dissert., Rostock, 1905.

inflammations of the accessory sinuses *Pneumococci, Staphylococci* and *Streptococci* are by far the most important.[1] A direct passage and communication between a sinus and the lacrymal sac only occurs rarely in phlegmonous dacryocystitis, due to its spreading beyond bounds and forming a fistula.

When the duct is closed, the overflow of infectious secretion must find its way upwards into the conjunctiva; hence the great liability of wounds of the globe to infection. The statement by Hauenschild that such an overflow does not take place unless some special pressure is applied cannot be confirmed, although it is true that an ascending infection of the nasal duct does not generally occur.

If the sac be completely cut off, its contents will gradually become sterile, as is the case in similar conditions of other closed mucous cavities, particularly the accessory sinuses of the nose, which form mucoceles with sterile contents. The bacteria (*Pneumococci*) will finally die out, unless the retention causes a spread to the surrounding tissues, and an acute inflammation with a fistula results.

The results of occluding the canaliculi by cauterization in cases where there is total stenosis of the nasal duct shows that this acute spread is not very common; it is more common to have a retention cyst with sterile contents. The recommendation of Brandenburg that, instead of extirpation, the canaliculi should be cauterized to cut off the sac, is based on sound principles. Complete occlusion, however, does not always follow this method of treatment.

Bacteriological Findings.

In cases of dacryocystitis the extraordinary richness in bacteria of the pus from the sac was long ago the cause of investigations by Leber, Widmark, Sattler, and Schmidt-Rimpler. Purulent infections of the cornea could be obtained experimentally both by the inoculation of the pus and the pure cultures obtained from it; results thus obtained agreed with the clinical evidence in man. Schmidt-Rimpler compared the effect of inoculating with the pus and with the pure cultures, and showed that the lacrymal secretion varies very much in its infectiousness.

Attention was at first directed to the *Staphylococci* and the *Streptococci.* Later, however, from the researches of Gasparrini, Cuénod, Mazet, Uhthoff, and Axenfeld, the most important organism present was shown to be the *Pneumococcus,* which in the majority of cases

[1] See section on 'The Orbit,' and Hoffmann, *Z. f. A.*, 1906, xvi., 'Festschrift f. Kuhnt.'

occurred in large numbers and in a virulent form. (The enormous numbers of *Pneumococci* which can fill the sac are shown in Fig. 52, from a preparation by Stock. This specimen was obtained immediately after death from a patient suffering from trachoma with an untreated dacryocystitis chronica, and was stained by the Gram-Weigert method. The lumen of the canaliculus at the entrance into the sac is filled with *Pneumococci* [blue]. At one point they have begun to break through into the surrounding infiltrated trachomatous tissues.) Rollet, Guignot, D. Smith, Poulard, and Roche have found the same appearances. As these organisms in culture often grow in the form of long chains, we may conclude that some of the appearances which have been described as due to *Streptococci* have really been of this class (Poncet and Redard, Soc. Franc. d'Oph., 1886).

The relative frequency of the different organisms varies in the different series. Gerstenberger (Wurzburg) in 12 cases found *Streptococci* 4 times, *Staphylococci* 5 times, *Pneumococci* 4 times. Gourfein in 40 cases found:

18 times *Pneumococci* (8 pure, 4 with *Staphylococci*, 6 with *Streptococci*).
14 ,, *Streptococci*.
4 ,, *Staphylococci*.
4 ,, *Pneumobacilli*.

In 30 cases of catarrhal dacryocystitis, methodically examined in my clinic by Brons during 1906, the following were the findings:

16 cases contained *Pneumococci* in excess (8 pure, 7 mixed with a few other organisms.—*Staphylococci* 5; *Bac. fluor. liquef.*, *Streptococci*, and *Bac. coli communis*, 1 each).
7 ,, ,, *Staphylococci* in excess (1 with *Diplobacilli*).
5 ,, ,, Gram negative bacilli, 1 influenza (with a few cocci), 1 the *Pneumobacillus* (with a few cocci).

Many of the cases contained stray xerose bacilli in the secretions.

The *Pneumococci* from the lacrymal sac agree in their cultural and morphological features with those obtained from ulcera serpentia, or from the conjunctiva (see p. 183). The variability of their form in cultures and their differential diagnosis from the *Streptococci* is fully given on pp. 184 and 207.

There is a marked difference between the action of the *Pneumococci* from the conjunctiva and those from the lacrymal sac. The former may be quite harmless, with feeble power of growth and virulence; but when they do cause an inflammation, it is typically an acute spontaneously healing conjunctivitis (see 'Pneumococcal Conjunctivitis'). The *Pneumococci* rapidly disappear, and a chronic inflammation from this cause is rare. On the other hand, the organisms in the lacrymal sac do not cause such a reaction; the catarrh here is eminently chronic. Under some circumstances the *Pneumococci* may remain present for years, and that, too, with a greater virulence than they have when obtained from the conjunctiva. This is shown by the malignancy of the corneal lesions produced, and by the results of experimental inoculations with the secretion (Schmidt-Rimpler), and with cultures.

The *Pneumococci* in the sac as a rule are derived from the conjunctiva; they rarely come from the nose. The increase in virulence may be due to the fact that in the sac they are at a higher temperature, one nearer that of the body than obtains in the conjunctiva, and also because they are better nourished than in the conjunctival fluid. Perhaps the lower acidity has an influence. Gifford has shown that the *Pneumococcus*, although a facultative anaerobe, retains its virulence longer when cultivated from the conjunctiva if kept free from acidity (by the method of Buchner). When the growth of pyogenic *Pneumococci* is examined after the extirpation of the sac, we find them rapidly disappearing from the conjunctival secretions (Plaut and von Zelewski), a further illustration of the difference in the nutritive conditions in the two places.

FIG. 52. — CANALICULUS AT THE ENTRANCE INTO THE SAC, IN A CASE OF CHRONIC DACRYOCYSTITIS (STOCK).

Lumen filled with *Pneumococci* (blue); at one place commencing eruption into the surrounding tissues (pericystitis phlegmonosa incipiens).

In the truly acute purulent 'pericystitis' chain-forming cocci are found, having all the characteristics of the *Streptococcus pyogenes*. They are, however, not so common in simple dacryocystitis, where the *Pneumococcus* is the most important. Acute phlegmonous conditions with *Pneumococci* and catarrhal conditions with *Streptococci* do occur, even in one and the same individual (Gabriélidès).

Friedländer's *Pneumobacillus*, or the so-called ozæna bacillus, is found in a smaller proportion of cases, sometimes as the only organism present, sometimes along with other organisms (Sattler, Terson and Gabriélidès, Mazet, Cuénod, Uhthoff and Axenfeld, Gourfein). There was at first an opinion prevalent, and strongly held by Terson and Gabriélidès, that these bacilli were of great importance in the sac, especially in the pathology of hypopyon-keratitis, because ozæna was so commonly present also. Results have not confirmed this opinion; they have certainly been found in many cases of ozæna (Terson and Gabriélidès; Mazet, Lodato), but, as a rule, the hypopyon-keratitis in these cases is caused by the *Pneumococcus*. In comparison with the organism which

we have mentioned, the *Staphylococci* are of very little importance in the secretion from the sac, although they are often enough found there. The indication for the use of the 'staphylase' of Doyen in dacryocystitis, as recommended by Darier and Berard, is therefore very limited.

FIG. 53. — SECRETION FROM A CASE OF DACRYOCYSTITIS WITH INFLUENZA BACILLI (RED) AND XEROSIS (BLUE). GRAM STAIN. × 1,000.

Still more rarely do we find *Bacterium coli* in phlegmonous dacryocystitis (Mircoli, Mazet, Uhthoff, Groenouw, Rabinowitsch). This organism may have been the cause of the abscesses, as when cultivated the bacilli were very pyogenic. Other organisms which have been found are the *Bacillus pyocyaneus* (Sattler, Jaulin), and certain peculiar pyogenic bacilli of variable form, not exactly classified[1] (Sattler, Uhthoff, Mazet). A strain resembling *Proteus* caused a hypopyon-keratitis in the cornea of the rabbit.

The two photographs here reproduced show a pyogenic bacillus of peculiar form which I grew from a case of a dacryocystitis several years ago. *Sarcinæ* and *Actinomyces albus* have been found. Griffiths reports having found the Koch-Weeks bacillus twice in cases of chronic dacryocystitis (in such cases we should be careful about the differential diagnosis from the influenza bacillus).

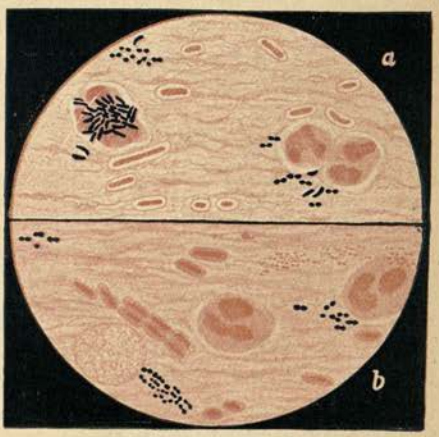

FIG. 54.—PUS FROM THE LACRYMAL SAC CONTAINING PNEUMOCOCCI, PNEUMOBACILLI, INFLUENZA, AND XEROSE BACILLI.

In the glairy non-purulent secretion the xerose bacillus is often prominent (Fagge), and may appear to be in pure

[1] The *Bac. salivarius septicus*, which caused infection in a cataract case of Von Ewetzky and Berestrew, is identical with the *Pneumococcus*, not the *Pyocyaneus*, as Gabriélidès considered.

culture; such a secretion is not necessarily infectious, though it is not justifiable to consider all cases which are not purulent as harmless, as even in them pus-producers may be present. Cuénod found the *Pneumococcus* eight times in ten cases with glairy secretion. In the purulent cases these bacilli are quite subordinate to the pyogenic ones mentioned.

As has been already mentioned in the chapters on 'Influenza Conjunctivitis' and 'Trachoma,' the influenza bacilli are fairly often found in the pus from the sac (the term being applied to those small, short, Gram-negative rods which only grow on media containing blood). These bacilli were certainly overlooked by the earlier examiners. Since turning my attention to this point I have found them very frequently. Brons has established their cultural identity with the influenza bacillus (Pfeiffer). L. Müller was the first to draw our attention to these bacilli in the sac; he has given up his original view that they were a proof of 'trachoma of the sac.' I have found them often enough without any suspicion of conjunctivitis granulosa. Brons rightly draws attention to their frequency in Baden, which is free from trachoma.

A case of diphtheria of the lacrymal sac with diphtheria of the nose, but without any such condition in the conjunctiva, has been reported by Feilchenfeld.[1] Behring's serum rapidly cured it. There was no bacteriological examination.

Darier's statement that he found the *Gonococcus* in the secretions of simple catarrhal dacryocystitis, is not conclusive, as his records contain no differential diagnosis from the other Gram-negative *Diplococci.*

In the secretions of chronic sac affections I have occasionally found Gram-negative *Diplococci.* The essential factors in deciding about these organisms are given on p. 212 in the chapter on 'Gonorrhœa.'

They were usually the *Micr. catarrhalis.* The conjunctiva is only slightly affected by them.

Veillon and Morax have found the anaerobic *Bacillus funduliformis* along with *Streptococci* in a case of gangrenous pericystitis. This is one of the putrefactive organisms which cause gangrene, and is related to the angina bacillus of Vincent; they also found another pyogenic anaerobic bacillus. Besides these organisms we can also find casually many varieties of saprophytes (the *Bacillus mesentericus*) and *Sarcinæ.* Mazet also found non-pathogenic bacilli.

The cases observed by Gallenga of rhinoscleroma of the sac are very unusual, as are cases of glanders, such as that of Gourfein (*cf.* section on 'The Lids,' p. 73).

[1] *Zent. f. Aug.*, 1902, p. 5.

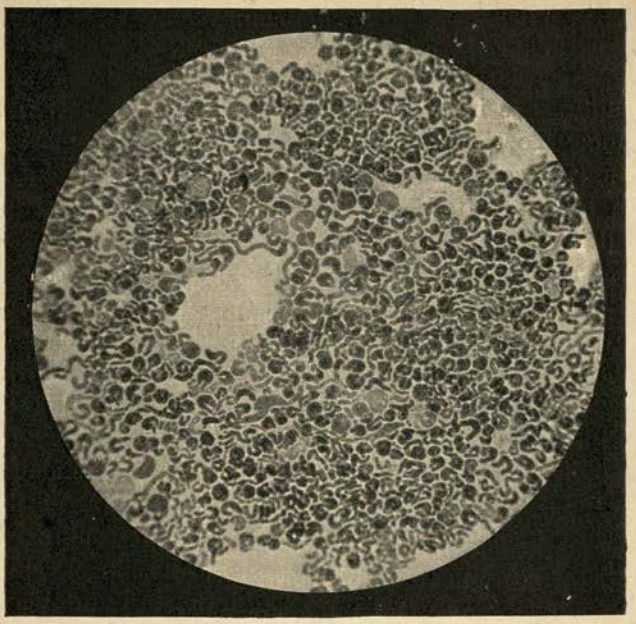

FIG. 55.—PYOGENIC BACILLUS FROM A CASE OF DACRYOCYSTITIS. BLOOD-SERUM. INVOLUTION FORMS. × 1,000.

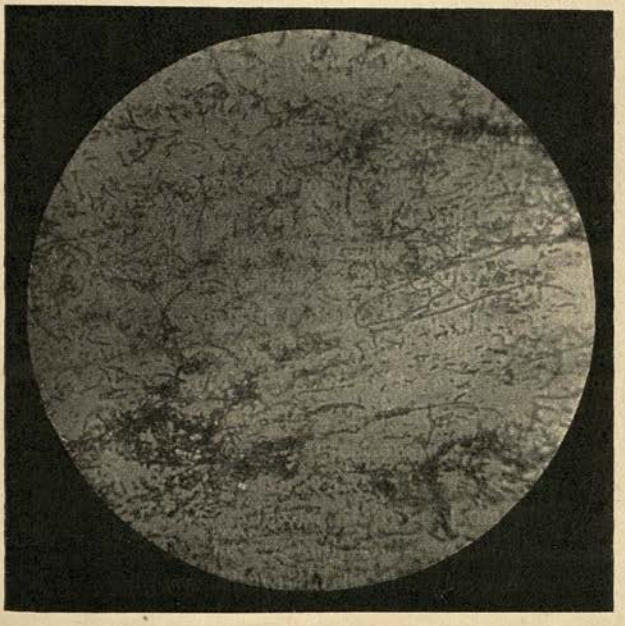

FIG. 56.—SAME BACILLUS AS IN FIG. 55. PURE CULTURE ON AGAR. × 1,000.

It should be noted that the not uncommon form of dacryocystitis in the newly-born, due to delay in the opening of the nasal duct, is generally quite free from bacteria, and is caused by a collection of detritus and mucus in the sac (Michel, Vossius, Cirincione, Terson, Wintersteiner, Topolanski, Rabinowitsch). A secondary infection soon occurs, the secretion becomes more and more purulent, and, as I have often been able to demonstrate, shows no material difference from the dacryocystitis of adults. In many cases I have found *Pneumococci* and *Staphylococci*. Hirch found *Pneumococci*. Valude found the *Tetragenus*. Antonelli found (presumably) *Gonococci* in the intact conjunctiva (his findings in the absence of cultures are not proof of the presence of the *Gonococcus*). Selenkowski cultivated very virulent *Staphylococcus aureus*. Such cases of dacryocystitis or dacryostenosis congenita can simulate a primary purulent conjunctivitis. Peters is right, therefore, in stating that attention should be paid to the duct in all cases of non-gonorrhœal suppuration in the newly-born. Péchin named this condition a 'pseudo-conjunctivitis'—a name against which Fejer protested, as it has nothing to do with the conjunctiva. Care must be exercised in the examination of these cases, as sometimes it is only after deep pressure in the fossa lacrimalis with a glass rod that the pus will be evacuated from the sac. It would be going too far were we to consider all cases of non-gonorrhœal catarrh as invariably of this type. In all cases of gonorrhœa, too, it is advisable to examine the lacrymal passages.

LITERATURE.

ANTONELLI, Dakryocystite congenitale. Soc. d'ophth., 1891.

ARIBEAUD, Pericystite lacrymale. Thèse de Lyon, 1901.

AXENFELD, K. M. f. A., 1903, XLI, S. 128.

BARDOUX, Dacryocystite congénitale ou Pseudo-conjonctivite du nouveau né. Thèse de Toulouse, 1905 (*cf.* here literature).

BASSO, Bactériologie de la Kératite à Hypopionst. Internat. Kongr., Rom, 1894. Also Tracoma delle vie lagrimale. Ann. di Ottalm., 1906, XXXV, p. 621.

CUÉNOD, Contribution à l'étude des affections pneumococciques de l'œil. Compt. rend. du congr. franç. d'ophth., 1895, p. 534.

DARIER (Staphylase), La clinique ophth., 1905, p. 297.

FAGE, Bacille pseudodiphterique dans un cas de dacryocystite. Soc. d'ophth. de Paris. Annales d'oculist., 1896, t. 115, p. 55.

FEJER, Dakr. neonat. A. f. A., 1907, LVII, p. 23.

GALLENGA, Zentralbl. f. prakt. Aug., October, 1899.

GERSTENBERGER, Beiträge zur bakteriolögischen Untersuchung des Tränensackeiters. Inaug. Dissert., Würzburg, 1896.

GOURFEIN (Rotz), Arch. d'ophth., t. 18, p. 699. Rev. Med. de la Suisse Romande, 1902, p. 130.

GUAITA, Le diplocoque de FRÄNKEL en pathologie oculaire. Internat. Kongress in Rom, 1894.
GUIGNOT, Pneumococcie oculaire. Thèse de Paris, 1904.
ISCHREYT, A. f. A., 1903, Bd. 49, S. 102.
JAULIN, Tuberculose de l'apparat lacrymal. Thèse de Paris, 1894.
JOERSS, Beiträge z. A., 1898, XXXV.
LAWSON, Bacteriol. of the lacr. sac. B. M. J., August, 1898.
LEBER und SATTLER, Die Bakteriologie in der Augenheilkunde. Internat. ophth. Kongr., Heidelberg, 1888.
MAZET, Recherches bacteriologiques sur deux cas de tumeurs lacrymales phlegmoneuses. Ann. d'ocul., 1894, t. 111, 3, p. 211.—*Ibid.*, Sur l'empyème du sac lacrymal (étude bactériologique et clinique). Thèse de Paris, 1895, et Compt. rend. du congr. franç. d'ophth., 1895, p. 545.
MORETTI, Dakryo-Adenite. Annali di Ottalm., 1905, XXXIV, S. 3.
MÜLLER, L., Vortrag Heidelberg, 1902, and A. f. A., 1903, LVII, S. 138.
PARINAUD, Conjonctive lacrymale à pneumocoques des nouveau nés. Annales d'oculist., December, 1894, t. 112.
PETERS, Z. f. A., 1899, Bd. II, S. 152.
PLAUT and ZELEWSKI, K. M. f. A., 1901, S. 369.
POULARD, Arch. d'ophth., 1903, XXIII, p. 625.
RABINOWITSCH, Zentralbl. f. A., 1903, S. 482.
RAEHLMANN, Dakryocystitistrachomatose. D. med. Woch., 1901, S. 747.
RICCHI, Annali di Ottalmol., 1899, vol. 28, p. 47.
ROCHE, Péricystite aiguë à streptocoques. Thèse de Paris, 1902.
SATTLER, Über die im Thränensackeiter vorkommenden Spaltpilze. Verhandl. ophth. Ges., Heidelberg, 1885, S. 18; Physik. med. Ges. Erlangen, November and December, 1885.
SCHMIDT-RIMPLER, Sitzungsber. d. Gesellsch. zur Beförderung d. Naturwissensch., Marburg.
SELENKOWSKI, Wratsch, vol. 22, p. 1358, and Westnik ophth., 1901, XIX, p. 1.
SMITH, DORLAND, Arch. of Ophth., 1905 and 1906, XXXIV and XXXV.
TERSON et GABRIÉLIDÈS, Recherches sur l'état microbien de la conjonctive des ozéneux, sans complications apparents de voies lacrymales. Arch. d'ophth., 1894, t. 14, p. 488.
UHTHOFF und AXENFELD, Beiträge zur pathologischen Anat. u. Bakt. der eitrigen Keratitis des Menschen. Vortrag ophth. Ges., Heidelberg, 1895, and Naturforchervers, Wien, 1894. A. f. O., 1896, Bd. 42, 1.—*Ibid.*, Weitere Beiträge zur Bakteriologie der Keratitis des Menschen, insbesondere der eitrigen. A. f. O., 1897, Bd. 44.
VEILLON et MORAX, Annales d'oculist., 1900, t. 123, p. 175.
WIDMARK, Bakteriol. Studien über Dakryocystitis. Hygeia, October, 1895, S. 581, and 1887.
WERNCKE, Zur Ätiologie der Dakryocystitis acuta. Inaug. Dissert., Dorpat, 1900.

MOULD CONCRETIONS, STREPTOTHRICEÆ (ACTINOMYCOSIS) IN THE CANALICULI.

Clinical Appearances. Historical Account.

In the region of one of the canaliculi, generally of the lower, a red swelling slowly develops, accompanied by catarrhal symptoms. In the complete statistics of over fifty cases, most of which were in

women, the upper canaliculus was only four times affected. At its greatest the swelling reaches the size of a hazel-nut, and generally is less. An elongated, firmly resistant mass is felt in the region of the canaliculus, and the corresponding punctum is dilated. The greenish or darkly-stained contents of the canal, when pressed upon, sometimes pass to the opening, but they are not evacuated; either nothing comes out or else only a very little pus. The passage into the nose may not be closed, and fluid can be washed through from the canaliculus. A perforating ulceration of the skin has never been observed in these cases; the clinical appearances remain the same for months; the swelling may increase, but will not exceed the maximum stated. It is not known whether such cases would heal spontaneously or not, as every case which has been observed has been incised and evacuated, with rapid and permanent healing. In a single case reported by Krukow-Kastalsky, when the concretion was removed from the lower canaliculus, a similar one developed in the upper.

When the canaliculus is opened in the usual manner, a peculiar mass either comes out at once or does so with a very slight pressure. Sometimes there are several larger or smaller masses. The mucous membrane of the inflamed canaliculus is very much stretched, but its continuity is quite intact, and the mass is not adherent to it anywhere; it can be removed easily, and with any blunt instrument, and is only retained when the incision has been too small, or the mucous membrane has developed side pouches. There is only a single case recorded in which a loose connexion with the walls could be demonstrated (von Schröder).

The material removed varies in amount from half the size of the lens to that of a bean. Its surface shows fine elevations and clefts at places, and has a waxy appearance. Its colour is mostly greyish-green or greyish-yellow. Many concretions are brown or dark brown; these are older, harder, and less easily teased out than the more recent ones, which are very readily broken up into smaller fragments, which can easily be squeezed out like wax between two cover-glasses. In some cases calcification of the concretions occurs (A. von Graefe, Gruning). The mass of mould seems finally to die, when we have a calcareous body surrounded with debris (Snegirew, Capellini). The microscopical examination by Capellini of these later stages is of special interest. The concretions contained calcium monophosphate and carbonate. In the sections a dendritic netlike structure was very evident, produced by radially arranged needle-shaped crystals; the most peripheral layers of the individual crystalline masses were

stained dark brown. The *Streptothrix* elements were no longer visible; still, the concretion had probably developed on such an organic basis.

When fully developed the clinical appearances are almost absolutely characteristic.[1] The earliest records of this condition are by Cesoni (1670), Sandifors (1779), and Desmarres (1842). Albrecht von Graefe was the first to give a clear description (which still holds good) from ten cases under his own observation. He stated definitely that the contents of the canaliculi must be of organic nature, and this was confirmed by the microscope. Graefe was at first inclined to identify the mould with favus. Conheim, on the other hand, defined it as '*Leptothrix*.' His views were followed by Leber and Waldeyer, the latter because the concretion

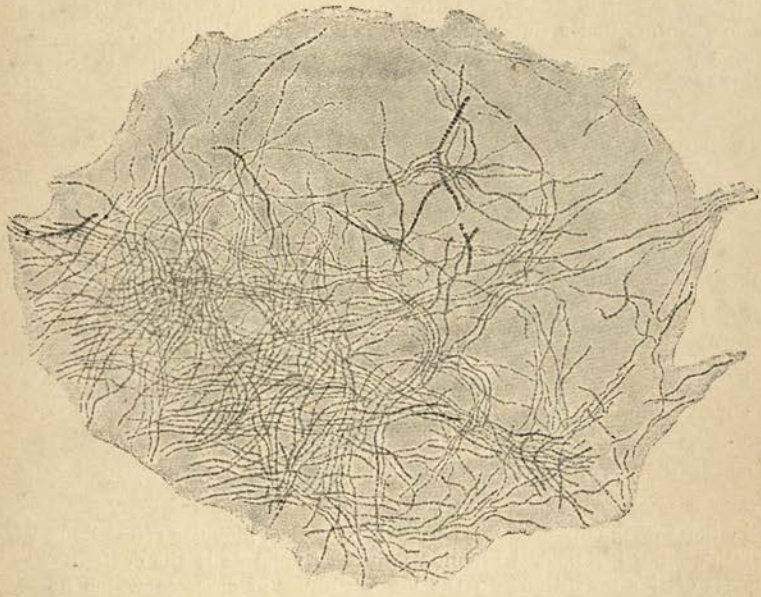

FIG. 57.—CONCREMENTS: DALEN'S CASE.

in his case was dark brown, as is *Leptothrix* in the mouth. Both observers make the reservation that the filaments which they found were here and there branched, and also that they were different from *Leptothrix* in that the characteristic iodine reaction was not obtained. Graefe then adopted the name '*Leptothrix*,' and the disease went under this designation until 1875. The same explanation of the condition is repeated by Camuset and Hirschberg. Ferdinand Cohn differentiates the mould from *Leptothrix* for the reasons already given; he considered that he had to do with a special form, and gave it the name of *Streptothrix foersteri*.[2] He stated that the filaments were of an even thickness

[1] Very exceptionally other foreign bodies are found (Mitvalsky). I have seen syphilis of the canaliculus showing this appearance.

[2] Cazalis is quite wrong in applying this name to a variety of *Streptothrix*, growing on agar as a thick dry mass, and which he obtained from the conjunctiva in trachoma, and which I have also found under the same conditions. These are really examples of the widespread *Actinomyces albus* (Lachner and Sandoval).

like hairs, and under a low magnification appeared homogeneous; they were here straight, there coiled quite irregularly, and they branched, though not freely. They differ from *Streptothrix buccalis*, which is thicker, straight, and stiff, is definitely segmented, and does not branch; the *Streptothrix foersteri* does not give the iodine reaction. The growth is analogous to *Leptothrix* to the extent that the main mass of the concretion is formed of the fungus alone. Von Reuss and Goldzieher undertook a revision of the literature on the basis of Cohn's results. They identified the older cases with those due to the *Streptothrix foersteri*. Since then this name is mostly used in the statistics until in 1894, when Schröder and von Huth applied the name 'Actinomycosis' to the concretions on account of the presence in them of refractile bodies with knotted or clubbed processes. Their communication was anticipated by that of Tommasoli and Bajardi, but these latter were not known in the ophthalmic literature. Goldzieher and von Reuss considered that the earlier cases were *Streptothriceæ*, and von Schröder collects the literature to date under the heading of 'Actinomycosis'—that is, he considers the condition due to a particular form of *Streptothrix*. He identifies the mould with the *Actinomyces hominis seu bovis*, and it must be admitted that in his own cases,

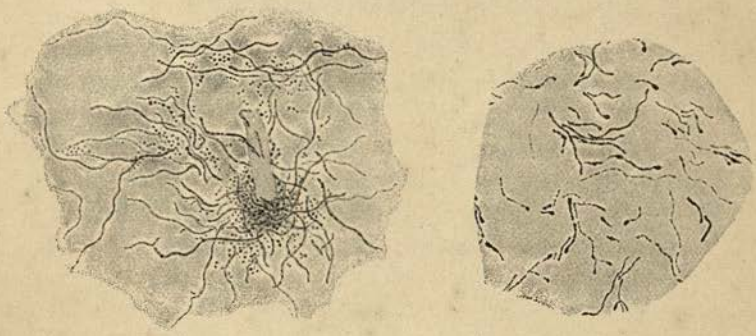

FIG. 58.—DALEN'S CONCRETIONS. AGAR CULTURE.

and in those of the authors who found these typical globular refractile bodies, this conclusion from histological grounds is just as valid as is the customary surgical diagnosis of this organism. In the large number of cases in which no globules were seen, but only fibrils, the variability of the *Actinomyces* is such that its presence cannot be excluded. Boström and Israel claimed that the older cases were Actinomycosis, and Ferdinand Cohn later agreed with them. Schröder considers that the comparatively benign character of the affection, when compared with Actinomycosis in general, is not evidence against such a cause; for this can be explained by the fact that the fungus here lies in an epithelial cavity, and also by the low nutritive value of the tears.[1]

This communication (of Schröder) attracted general attention, with the result that still further statistical records were forthcoming under the title of 'Actinomycosis of the Canaliculi' (Ewetsky, Elschnig, Lange, von Schröder, Mitvalsky, Robert, Terson, Ginsberg, Mackay, Cartais, Awerbach). In one of his later cases von Schröder was able to show that the mould filaments had penetrated the walls of the canaliculus; the clinical picture was, however, the same.

[1] It is interesting to note that Majocchi found a similar concretion in Wharton's duct (*Arch. per le Scienze Med.*, 1892, xvi. 15). Miodowski (*Arch. f. Laryng.*, xix.) found granules like *Actinomyces* in the tonsil; Saxer found a similar appearance in the tonsil.

Doubts as to the correctness of the new view are aroused by the anomalous clinical appearances, and by the general agreement that *Actinomyces bovis* belongs to the family of the *Streptothriceæ*, the members of which can resemble each other very fully in their morphology, though in other respects they are essentially different. Lachner and Sandoval, Axenfeld and Kastalsky, insist that exhaustive examinations of cultures are necessary before these organisms can be defined with certainty. At present it is better to speak of *Streptothriceæ*. If we consider the *Streptothriceæ* as *Actinomycetes*, then the concretions can be spoken of as Actinomycosis. We should not conclude that these organisms have been proved to be identical with the variety *Act. hominis seu bovis*. Van der Straeten goes still further, and considers that this affection is only a pseudo-actinomycosis, because the clinical picture is so different, and the typical refractile bodies are wanting; Bourgeois expresses the same opinion.

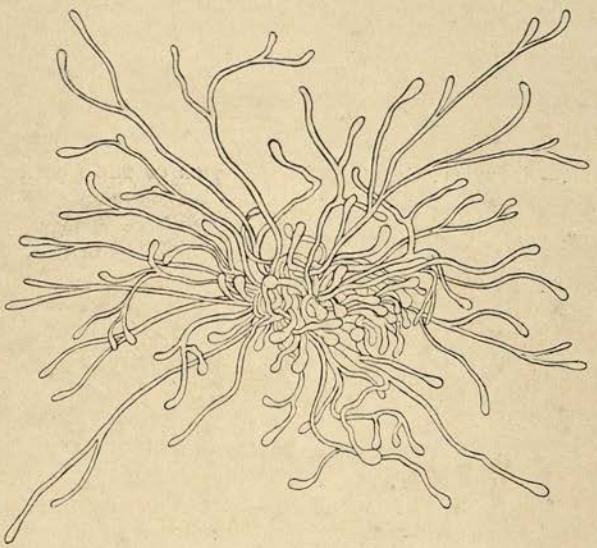

FIG. 59.—AXENFELD, CASE I. ANAEROBIC AGAR CULTURE.

Axenfeld and Cahn have shown that this exclusion of the *Actinomycetes* goes too far in the other direction, for the reasons brought forward by Van der Straeten do not definitely exclude the presence of this organism (see p. 293). The further examination of this case by Awerbach has shown that it agrees with the *Actinomyces bovis* in many particulars, so that the name is rightly applied to it.

The work of Silberschmidt shows that the variety known as *Actinomyces bovis* is not the only one which takes part in the formation of concrements. In 1900 he obtained two series of cultures; till then every attempt at cultivation had miscarried, or else, as in the two first cases of Kastalsky and Axenfeld, was not complete enough for thorough identification.

In fresh and unstained preparations Silberschmidt found fine Gram-positive segmented filaments, and along with them elements resembling cocci. Very few branches occurred, and here and there were slightly thickened ends to the filaments. No radial arrangement of fibres with clubbed ends could be seen, nor were the filaments coiled.

Cultures could only be obtained anaerobically, and growth only occurred after several days in the incubator. At the bottom of the agar tube the colonies developed in the form of round greyish-white smooth granules. In a stab culture the neighbourhood of the stab became cloudy.

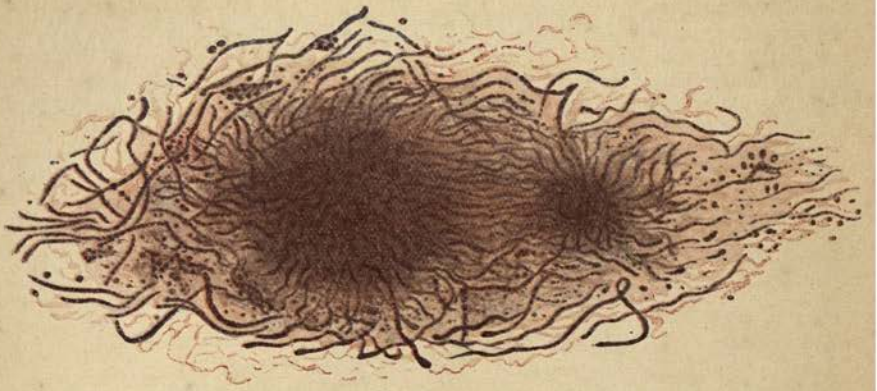

FIG. 60.—AXENFELD, CASE II. PREPARATION OF THE CONCRETION. GRAM-STAINING.

FIG. 61.—AXENFELD, CASE II. ANAEROBIC AGAR CULTURE. POLYMORPHISM; RESEMBLANCE TO DIPHTHERIA BACILLI IN PLACES. GRAM'S STAIN.

At the bottom of a bouillon culture a mulberry mass formed; it was easily broken up, and disintegrated when shaken, the fragments resembling small pieces of cotton-wool.

When freely transferred, cultures from bouillon and agar could be propagated on agar.

Polymorphism was very pronounced in the cultures. The first cultures showed rods like diphtheria bacilli, which occasionally branched. Long branching threads with swellings on them were often very obvious; short rods occurred still more frequently, and in the older cultures cocco-bacillary forms. Long threads were especially well seen when the material was evenly and smoothly spread, and not too much teased out.

Closely tangled bundles of fibres were never observed, nor was there any radial arrangement.

The *Streptothrix* had only a slight pathogenicity for animals; intravenous injection in rabbits produced no result, but intraperitoneal and subcutaneous in guinea-pigs and white mice produced a free local suppuration.

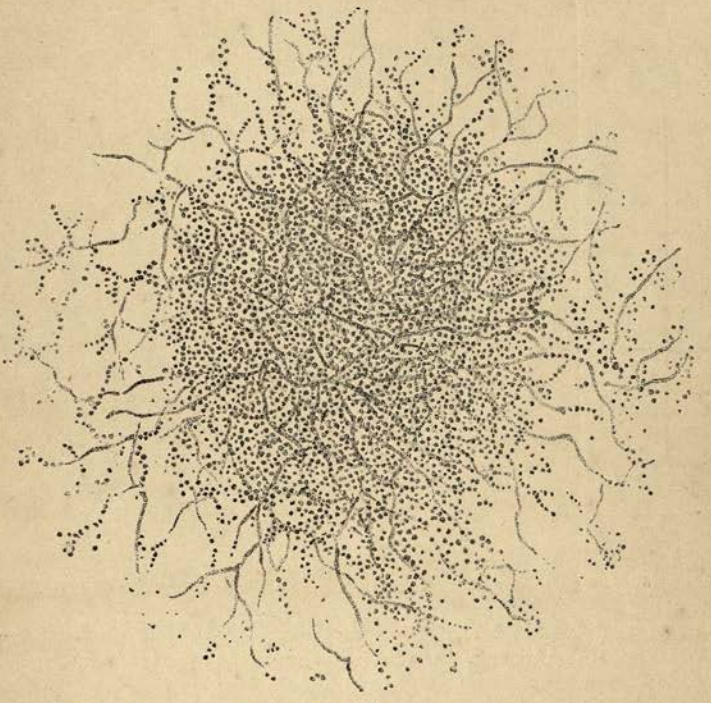

FIG. 62.—AXENFELD, CASE III. SMEAR FROM THE CONCRETION.

This *Streptothrix*, therefore, corresponded neither to the aerobic *Actinomyces* of Boström, nor the anaerobic one of Israel. Of course it is impossible to say to what extent the characteristics determined by Silberschmidt can be applied to the earlier cases which were culturally undefined.

Silberschmidt was very fortunate in having a pure culture of the *Streptothrix* from the first. This is rarely the case. In my five cases which are described in the dissertation by Cahn, there was always from the first an admixture of large numbers of other organisms—*Streptococci* and bacilli (exclusive of the cocco-bacillary forms of the *Streptothriceæ*). These other organisms rapidly grew over the medium in the aerobic cultures, while the *Streptothriceæ*, with their slow growth never appeared. On the other hand, in anaerobic cultures the former were in abey-

ance, and in three cases it was possible to obtain cultures of the *Streptothrix*. Cultural isolation and exact definition of the mould were only successful in two of these cases. In one of them the liquefied anaerobic culture was left for eighteen months, when the *Streptothrix* was still living, the other organisms having died out. This was an undoubted *Streptothrix* without any marked pathogenicity for animals. In the second case successful anaerobic cultures were obtained on a weakly acid medium. In the third failure was due to the excessive growth of the other organisms when the medium was inoculated. In every case cultures should be grown anaerobically on acid media.

FIG. 63.—ANAEROBIC CULTURE, FROM A CONCRETION SENT ME BY PROFESSOR LANGE.

FIG. 64.—SECTION OF THE ANAEROBIC CULTURE.

At the periphery numerous secondary colonies are developing, with radiating branched processes.

I have succeeded in obtaining another pure culture from a concretion sent me by Professor O. Lange (Braunschweig), but its full description is not yet available. The culture and a section of the growth are shown in Figs. 63 and 64.

Dalén has recently succeeded in obtaining cultures from two cases. The fresh concretions did not show any globular bodies, but only a tangle of fibres, which branched very sparsely. Dalén only obtained the *Streptothrix* in deep agar stab cultures. Small nodules developed here, and could be further inoculated for two to three weeks; filaments with sparse branchings also occurred, and in old cultures a free polymorphism. Subcutaneous and intraperitoneal injections were negative. Dalén did not attempt any further classification of the variety of *Streptothrix* present.

Recently the question of whether these are *Leptothriceæ* has again been brought forward—a return to the views of A. von Graefe's time. Hirschberg described

a case in which Kempner gave the diagnosis of *Leptothrix;* the findings were like those of the previous cases, but no branching could be seen in the fine, slightly-coiled filaments. As such branchings can be very infrequent in the *Streptothriceæ*, and may only be obvious in cultures (Axenfeld and Cahn), such an observation is not diagnostic, as the determination of the organism by cultures was not made, and the iodine reaction[1] was not obtained.

Awerbach also considered that the diagnosis of *Leptothrix* in these cases was not justified. The same can be said of Piorkowski's record of a case of Segelken's. This author concludes that *Leptothriceæ* cannot be proved to take part in this affection, especially as in the case referred to radially marked bodies were seen; nor can they be excluded on account of the uncertainty about the exact definition of the members of this family. Smear preparations made from Capellini's highly calcified concretion showed unbranched filaments, which were considered to be *Leptothrix;* but against this view the uncertainty already mentioned must be taken, especially as club-shaped bodies which were taken to be *Actinomyces* occurred. No certain diagnosis was possible in this case. Cultures miscarried. The diagnosis of *Leptothrix*, made from purely microscopical evidence in another case, is marked by Capellini with a query. (Basevi found putrid pus in the lower canaliculus; this contained *Leptothrix* besides *Pneumococci* and *Staphylococci;* the diagnosis, however, was not based on any exact grounds. There was no concretion in this case. The patient had washed his eye in sputum.)

Cannas contributes an interesting communication regarding this question. In the pus from the canaliculi he found, along with bacilli and cocci, spirillæ and filaments which appeared to him to be fragments of *Leptothrix*. The concretions mostly consisted of very fine, long, thickly felted filaments, in which Cannas could find neither branching nor segmentation. They stained by Gram's method, and were violet on the addition of Lugol's fluid.

The culture on gelatine after a few days showed, along with other organisms, a large greyish-white colony with a notched translucent margin, which, when transferred to glycerine agar, rapidly covered the whole surface with a greyish-white membrane. Slow liquefaction occurred in a gelatine stab culture; in bouillon a free deposit occurred after forty-eight hours. Cannas found under the microscope typical clusters of *Leptothrix buccalis*, as they occur in teased preparations. No result on injection into animals. Cannas gave the diagnosis of *Leptothrix* based on Robins's researches (1855).

These findings differ markedly from all the others, and the consensus of opinion is that *Leptothrix* does not grow in this manner. The diagnosis of *Leptothrix* is not consistent with a spirilla. Further, this is the first and only occasion of a positive reaction with iodine. It is also remarkable that only a single colony of the variety grew.

Cannas quoted the researches of Majocchi with regard to the concretions in the salivary ducts, and comes to the same conclusion—that the parasitic elements may vary, so that we can have (1) *Leptothrix*, (2) *Streptothrix Foersteri*, (3) *Actinomyces*. Cannas' results do not seem to me to be at all convincing.

Lately Awerbach has obtained very good results by culture. In the concrements he found globular bodies ('Drusen'), with here and there slight thickenings of the radiating lines. There were no club-shaped swellings. Dichotomous division was frequent.

[1] The iodine reaction is admittedly inconstant in *Leptothrix*. According to the observations of Fricker (*Zent. f. Bakt.*, 1904, xxxvi. 369), it only occurred when a medium containing starch was used. The conditions under which the organism is grown certainly has an influence on this reaction. The most definite characteristic of *Leptothrix* is that it consists of unbranched and uncoiled filaments, and this has not been found in concretions from the canaliculi—at least, not in those cases confirmed by cultures.

Only three direct bouillon cultures were successful from all his cultures; the filaments which he grew were very similar to diphtheria bacilli (*cf.* Fig. 61): inoculation under the abdominal skin of a guinea-pig caused abscess formation; intraperitoneal injection killed a mouse in eight days; in one of the mesenteric glands and in a nodule situated in the liver typical 'actinomycotic new formations' were found, with many granules, presenting the characteristic 'Drusen' with club-shaped swellings.

In another guinea-pig subcutaneously injected the post-mortem section after two and a half days showed an encapsuled abscess, in which typical 'Drusen' with clubbed ends were seen. Awerbach is doubtful about the diagnosis of *Leptothrix* in Hirschberg's case, and rightly considers that it was one of ray-fungus infection. But when Awerbach considers all such cases as 'actinomycosis,' he could only be justified were he to use the term as a family name; it is incorrect to speak of the 'ray-fungus' as one particular organism.

Zur Nedden's first case only yielded anaerobic cultures at first in peptone-glycerine-agar; later, however, it grew in other media, and, after repeated transferences, also in aerobic cultures.

The morphological appearances resembled those of Axenfeld's Case II. Branching occurred, but no club-shaped bodies. On subcutaneous or intraperitoneal injection it was not pathogenic for animals. Under the conjunctiva small nodules developed, in which the organisms continued for a long time. Zur Nedden prefers the general term *Streptothrix*, for the reasons already given.

In a second case the mould grew aerobically, as a thick brown scum on agar, resembling a culture of the *Bacillus xerosis*. Gelatine, milk, and potatoes gave no growth at all. It was not pathogenic for animals. The case was characterized clinically by a chronic lid abscess, which had developed near the canaliculus.

In one of the cases described by Morax the cultures were best obtained under anaerobic conditions and on sugar media. The growth consisted of white masses, slowly increasing; they resembled Fig. 60. No club-shaped bodies were seen, and the '*Bacille filamenteux*' branched. Growth was obtained on glycerinated potatoes and in glycerine water. They would not, however, grow on acid potatoes, or on carrots, on which the other *Streptothricæ* flourished. Morax therefore considered that they were not *Streptothricæ*.

The inoculation of animals was negative. There was an exudation in the anterior chamber after the introduction of large quantities of the material, but no organisms were found in it.

To sum up, we must admit that further exact examinations by means of cultures are necessary before the nature of these concretions in the canaliculi can be determined. The polymorphism of this organism renders its exact determination very difficult.

It can be taken as established that several varieties of *Streptothricæ*

do occur. I use the name *Streptothriceæ* as the family name for the ray fungi, to which group the various Actinomycetes belong. In the eleven cases already cultivated (Kastalsky, Axenfeld, Silberschmidt, Dalén, Awerbach, Zur Nedden, Morax, Velhagen) a *Streptothrix* was always present;[1] the only exception is the case of Cannas, in which a *Leptothrix* is said to have been cultivated, though it did not correspond to the generally accepted characteristics of that organism. It appears probable that a *Streptothrix* is almost always present, as the clinical appearances are very constant, and the microscopic examination of the filaments in the fresh concretions agree very well with each other. Even if in some of the concretions the branching of the filaments was not clearly seen, it must be remembered that in some cases, definitely due to the *Streptothrix* (Silberschmidt, Axenfeld, Dalén, Zur Nedden, and Morax), this branching was very scanty. It appears questionable whether the *Leptothrix* occurs at all frequently.

According to Mertens (*Zent. f. Bakt.*, 1901, xxix. 650), the *Actinomyces hominis seu bovis* of Boström and that of Israel can be transferred into each other; it is doubtful how often they take part in the formation of a canalicular concretion, although Awerbach's case shows that an *Actinomyces bovis* can occur. So long as we have no further information about its cultures—and the above-named authors agree in considering that anaerobic cultures will give the most information—and so long as various questions are still under discussion regarding the *Actinomyces*, the question of the frequency of these various *Streptothriceæ* must remain an open one.

In using the name *Streptothriceæ* as a general term to include various possibilities, I am following the lead of Kruse and others, and I do it more readily as in the historical account this name was first used. Von Petruschky[2] and others reject this as a generic name, and include among the *Streptothriceæ* those moulds which do not form

[1] The interesting nodular (*drusenartig*) 'concretions in the conjunctiva,' described by Fuchs and Wintersteiner as of frequent occurrence in the conjunctiva, at first give the impression that they are fungus masses (*Pilzdrusen*), and certainly these yellow nodules in the conjunctiva do have a certain resemblance macroscopically to actinomycosis. The writers mentioned have proved that these are not parasitic, but are really concretions. The same can be said of the case which Demicheri (*Arch. d'Ophth.*, 1899, xix. 102, 2) wrongly described as actinomycosis. The cases published as actinomycosis by de Vincentiis, von Oemichen, and Magnani (quoted by Zur Nedden), on the other hand, record true cases of actinomycosis of the conjunctiva.

Actinomyces albus, which is occasionally found on the conjunctiva and in the lacrymal sac (Cazalis, Ricchi, Gombert, Axenfeld), and which is so easily cultivated, has nothing to do with these *Streptothriceæ*, and Cazalis is in error in identifying it with the *Streptothrix Foersteri*.

[2] *Cf.* Petruschky, 'Die pathogenen Trichomyceten,' 'Handbuch von Kolle und Wassermann,' 1903, Bd. 3.

any radially arranged bundles. He prefers to call the whole group 'Trichomycetes' (hair moulds). Lehmann and Neumann call them 'Oospora,' Boström and others consider them as 'Pleomorphic' bacteria.'

The important thing to be observed is that the cause of the disease should not be restricted by the name applied to it, and that such a name should not anticipate facts. If we include the whole group under the term *Actinomycetes* (Lachner and Sandoval), we are quite as correct as when we name the disease 'actinomycosis,' and thereby at once imply that the cause is the common *Actinomyces*. Even the name *Actinomyces* is not free from fallacy, for the name implies that the mould can produce ray-formations; it is still to be determined whether that is the case with all these moulds.

It is impossible at the present to decide amongst these hypotheses. By careful examination of future cases we can assist in their elucidation.

LITERATURE.[1]

AWERBACH, Wratsch, 1902, Nr. 49. A. f. A., 1904, Bd. 49, S. 316.

AXENFELD, Bakteriologie des Auges in 'Ergebnisse,' von LUBARSCH u. OSTERTAG 1894-1900.—*Ibid.*, K. M. f. A., January, 1901.

BAJARDI, Jubiläumsschr. f. Sperino. Torino, 1884.

BASEVI, Annali di Ottalmol., 1895, XXIV.

DE BERARDINIS, Ulcera corneale da streptothrix. Ann. di Ott., 1904, XXXIII, S. 385.[2]

BLESSIG, IX. Pirogowscher Arzteverein. Westnik oft., 1904, XXI, Nr. 2 u. K. M. f. A., XLII, II, S. 176.

BOLLINGER, Zentralbl. f. d. med. Wissensch., 1877.

BOSTRÖM, Ziegler's Beitr. z. path. Anat. u. allg. Path., 1891, Bd. 9, S. 1.

BOURGEOIS, Revue de Sud-Est, 1900.

BUGIER, Recueil d'ophthal., 1874, p. 122 (Ref. in Nagels Jahresber. f. 1874, S. 527).

CAHN, Inaug. Dissert., Freiburg, 1903.

CAMUSET, Rev. clin. du Sud-Ouest, 1885, t. 3, p. 217 (Ref. in Nagels Jahresber. f. 1882).

CANNAS, N., Annali di Ottalmol., vol. 31, p. 606.

CAPELLINI, Archivio di Ottalmol., 1906, XIII, S. 238.

CARTAIS, Actinomycose des canalicules lacrymaux. Thèse de Bordeaux, 1904.

[1] The rare true actinomycosis of the orbital tissues presents the appearance of a granulating necrosis (*cf.* section on 'Orbit'). It is interesting to note that the transference of a culture of *Actinomyces* into the anterior chamber of a rabbit often produces no result, but in other animals it will produce a typical inflammation with the formation of 'drusen' (Mertens, *loc. cit.*).

Morax and Manoulian found a filamentous mould, which they took to be *Streptothrix*, in a nodular tumour of the eyebrow.

Leopold Müller's case is a unique example of a miliary metastatic nodule of *Actinomycetes* in the fundus (*K. M. f. A.*, 1903, i. 236).

[2] De Berardinis reports that he has several times found *Streptothricæ* on the surface of a corneal ulcer, and that with them, just as with two strains of the same organism from the lung, he was able to produce in the corneæ of rabbits ulceration varying in severity according to the depth and quantity of the material inoculated.

COHN, Beiträge zur Biologie der Pflanzen, 1878, Bd. 1, 3.
COPPEZ et DEPAGE, Un cas d'actinomycose orbitaire. Journ. med. de Bruxelles. 1903, Nr. 48. (K. M. f. A., 1904, I, S. 271.)
DALÉN, Mitteilungen aus der Augenklinik des Karolinischen medico-chirurgischen Instituts zu Stockholm, 4 Heft, S. 51.
DEL MONTE, Bolletino dell' associaz. dei naturalisti e medici, anno III, 1872, Nr. 6 (Ref. in Nagels Jahresbericht für 1872, S. 434).—*Ibid.*, Ref. Michel-Nagels Jahresbericht, 1872, S. 434.
DESMARRES, Annales d'oculist., 1842-43, t. 7, p. 149, t. 8, p. 85, t. 9, p. 20.
DÜNN, A. f. A., 1898, XXXVII, S. 274.
ELSCHNIG, K. M. f. A., 1895, S. 188.
EWETZKY, Archives d'ophthalm., 1898, p. 508.
FÖRSTER, A. f. O., 1869, Bd. 15, 1, S. 318.
GINSBERG, Medicinsk. Obossenije, 1901, vol. 55, p. 659 (Russian).
GOLDZIEHER, Zentralbl. f. prakt. Aug., February, 1884.
GRAEFE, A. v., A. f. O., 1854, Bd. 1, 1, S. 284.—*Ibid.*, A. f. O., 1855, Bd. 2, 1, p. 224. —*Ibid.*, A. f. O., 1869, Bd. 15, 1, S. 324.
GRIMHUT, Prager med. Woch., 1888, Nr. 23, S. 223.
GRÜNING, Knapps Archiv, 1873, Bd. 3, 1, S. 164.
GUIBERT, La clinique ophth., 1902, S. 351.
GUILLEMIN, Actinomycose des conduits lacrymaux. Thèse de Lyon, 1905.
HAASE, Knapp-Hirschbergs Archiv, 1879, Bd. 8, S. 215.
HIRSCHBERG, Zentralbl. f. A., 1902, Januarheft, S. 7.
HIRSCHLER, Szémészet, Nr. 3 (Ref. in Nagels Jahresbericht für 1874, S. 528).
HIGGENS, B. M. J., October, 1879 (Ref. in Nagels Jahresbericht für 1879, S. 381).
HOSCH, A. f. A., 1904, 49, S. 215.
HUTH, Zentralbl. f. A., April, 1894.
ISRAEL, Virch. Archiv, 1878, Bd. 74, S. 40.—*Ibid.*, ebd., 1884, Bd. 95, S. 140.
KASTALSKY, Beitr. z. prakt. Augenh., 1898, Heft 30, S. 19.
KIPP, Arch. of Ophth., 1902, XXXI, 4, p. 395.—*Ibid.*, Streptothrix im unteren Tränenröhrchen. A. f. A., 1904, Bd. 49, S. 236.
KRUSE (Flügge, Die Mikroorganismen, 1896, Bd. 2).
LACHNER und SANDOVAL, Über Strahlenpilze. Strassburg, 1898, bei L. Beust.
LAGRANGE, Gazette hebdomadaire des Sciences méd. de Bordeaux, November 6, 1904.
LEPLAT, Annales de la société médico-chirurg. de Liége, 1885, t. 24, p. 376.
MACKAY, Ophth. Review, 1901, p. 201.
MAGNANI, Giorn. della acad. med. di Tornio, 1904.
MITVALSKY, Arch. d'ophth., 1898, p. 508.
MOHL, Schlechtendahls Botanische Zeitung, 1865, Nr. 23, S. 187.
MORAX, Soc. d'ophth. de Paris, December, 1904; K. M. f. A., 1905, I, S. 244.—*Ibid.*, Annal. d'ocul., 1905, S. 188.
NARKIEWICZ and JODKO, K. M. f. A., Bd. 8, S. 79.
ZUR NEDDEN, K. M. f. A., 1903, XLI, Bd. 2, S. 329, and February, 1907, XLV, I.
v. REUSS, Wien. med. Presse, February, 1884, S. 202.
RICCHI, Annali di Ottalmol., 1899, XXVIII, p. 17.
ROBERT, Actinomycose des canalicules lacrymaux. Thèse de Paris, 1899.
SCHIRMER, K. M. f. A., 1871, Bd. 9, S. 248.
v. SCHRÖDER, K. M. f. A., April, 1894.—*Ibid.*, K. M. f. A., April, 1896, S. 116.
SEGELKEN, K. M. f. A., Bd. 2, S. 134.
SILBERSCHMIDT, Zentralbl. f. Bakt., 1900, Bd. 27, S. 486.
SNEGIREW, Wratsch, 1902 (Ref. Ophth. Klinik, 1903, S. 24, Konkremente in allen 4 Röhrchen).

STIEHL, Münch. med. Woch., 1895, S. 227; Ärztl. Verein, Nürnberg.
SUSCHKIN, Westnik oftalmol., 1902, S. 374.
TERSON, Clinique ophth., 1901, p. 97.
TOMMASONI, Giornale italiano delle malattie venerée, September, 1893.
VAN DER STRAETEN, Bullet. de la Soc. Belge d'ophth., November 26, 1899, p. 70.
VELHAGEN, Münch. med. Woch., 1907, p. 691.
WOLFF und ISRAEL, Virch. Archiv, 1891, Bd. 126, S. 11.

Infections of the Lacrymal Glands.

Except as regards direct injury, the lacrymal glands are, from their position and by their flow of secretion, especially well protected against external infection. Boch's observations show that occasionally an infection can pass up from the conjunctiva into the gland; he reports partial suppuration of the gland after a traumatic panophthalmitis. When the gland simply swells and does not suppurate, it is still doubtful whether this is due to the actual entrance of organisms, or to simple vasomotor or toxic swelling.

A 'trachoma of the lacrymal gland' (Baquis, *Annal. di Ottal.*, 1894; Ziegler's *Beiträge*, 1894) cannot be considered to have been positively seen.

Even amongst the cases of isolated **purulent dacryo-adenitis**, many instances may be endogenous. Certainly there is a predisposition to many endogenous infections, as, for instance, for the unknown agent in epidemic parotitis. These forms of endogenous dacryo-adenitis are mostly bilateral, and occur during or at the end of an acute febrile condition.

In miliary tuberculosis the *Bacillus tuberculosis* can settle down in this gland (Axenfeld), although in tuberculosis of the conjunctiva of long duration such a condition practically never occurs. In experimental hæmatogenous tuberculosis in rabbits Stock found that the glands were frequently affected.

The bacteriological findings available show that in the acute cases with abscess formation the *Staphylococci*, especially the *Staph. aureus*, are the most important (Orlandini, Jaumé; the older literature is given in these papers). In two cases I have cultivated the *Staphylococcus pyogenes aureus*. In the connective tissues of the gland Boch twice found collections of cocci, whose nature was not more definitely determined.

Gasparrini's case was peculiar in that the inflammation was restricted to the glands of Krause in the lower lid. In the fluid removed by puncture he found *Pneumococci*. Orlandini obtained the same result in the case of a patient with pneumonia. This last case was

probably metastatic. Calderaro and von Krüdener found *Streptococcus pyogenes* and large numbers of influenza bacilli. Moretti observed a suppuration of the lacrymal gland in erysipelas due to the *Streptococcus*. In another case Pes had a negative result.

In the cases of metastatic gonorrhœal dacryo-adenitis, which are mostly double-sided, abscess formation as a rule does not occur (see the literature on this point in the paper by Pes). In the conjunctival secretion of these cases *Gonococci* are not found (Casali, Eteviant, Giani).

Metastatic dacryo-adenitis in influenza is reported by Wicherkiewicz (Antonelli, *Soc. Franç. d'Ophth.*, 1905). There is no record given of the bacteriological findings.

According to the experiments of Valude, De Bono, and Frisco, the lacrymal gland has a comparatively great resistance against experimental inoculation. When bacteria enter the gland by way of the blood-stream, according to the Italian authors, they very rapidly show signs of degeneration. Presumably there is no passage of the bacteria along with the tears.

LITERATURE.

Aubaret et Caignerot, Revue génér. d'opht., 1903, p. 283.

Bock, E., Zur Kenntnis der gesunden und kranken Tränendrüse. Wien, J. Safar, 1896 (*cf.* hier ältere Literatur).

Casali, Ann. di Ottalm., 1906, XXXV.

Calderaro, La clinica ocul., 1902, p. 951.

Causé, Z. f. A., 1904, XI, S. 399.

Etiévant, Revue générale d'opht., 1903, p. 283.

Ferry, Ann. d'ocul., 1902, 128, p. 375.

Giani, Rivista di Ottal., June, 1906.

Gasparrini, La clinica ocul., 1903, p. 1233.

Jaumé, La dakryocystite primitive. Thèse de Paris, 1902.

von Krüdener, Bericht ophth. Ges., Heidelberg, 1903, S. 71.

Lor, Ann. d'ocul., 1901, p. 254.

Maklakoff, Ophth. Klinik, 1901, p. 355.

Moretti, Ann. di Ottalm., 1905, XXXIV, p. 3.

Orlandini, Ann. di Ottalm., 1905, XXXIV, p. 304.

Pes, A. f. A., 1905, LI, S. 157.

Snell, Ophthalmology, 1904, p. 36.

Sourdille, Arch. d'opht., 1900, p. 433.

Stock, K. M. f. A., 1903, Beilageh.; Festschr. f. Manz, und: Tuberkulose des Auges und seiner Adnexe, 1907.

Wicherkiewicz, Arch. d'opht., 1905, p. 347.

CHAPTER VIII

THE CORNEA

CERTAIN precautions, which have been stated on p. 3, should be taken when we collect material from the cornea for bacteriological examination. I would again mention that the causal organism may escape demonstration on account of its deep situation, as in the case of purulent infections certainly due to organisms. In these cases we should not scrape very deeply or firmly.

As in the various forms of conjunctivitis, so with regard to the clinical appearances of corneal inflammations due to organismal infection, no absolutely distinct bacteriological types exist. Here, as in the other situation, variations in the susceptibility, the resistance, and the power of reaction of the tissues, the nature and the depth of the injury or epithelial lesion, along with the numbers and the virulence of the bacteria, influence the clinical appearances, and can modify the symptoms to a varying extent.

Notwithstanding this, it has been established in the pathology of corneal inflammations that the cause of the infection and the clinical appearances, to a certain extent, do correspond; as, for instance, the *Pneumococcus* most commonly produces an ulcus serpens, the Zur Nedden bacillus appears in the form of an infectious marginal keratitis, etc. Just as in conjunctivitis clinical diagnosis is the most important, so is it here in the cornea. And for exactly the same clinical reasons must it be supplemented by bacteriology. One and the same infiltrate may have a different prognosis, may require a different treatment, and present different indications for treatment, according to its bacteriological etiology.

By this I do not merely refer to the attempts at a serum treatment for the ulcus corneæ serpens. These attempts have so far led, in only a very limited extent, to anything of value in dealing with the fully-developed disease.[1] The determination of a pneumococcal

[1] *Cf.* Axenfeld, 'Serumtherapie Infectiöser,' etc.

infection is also of value in those cases where the use of serum has not yet been considered as of value. When an atypical infiltrate is present, it will determine whether the condition is dangerous and requires immediate surgical treatment.[1]

When *Diplobacilli* are present, the case is quite different. Even if a severe purulent process occurs, treatment by zinc properly applied,[2] and combined with other measures of a conservative nature, will almost invariably lead to a successful result. I have never seen a case of diplobacillary infection of the cornea which we have not been able to control by this means;[3] though amongst my cases there have been some which appeared too far gone for even an energetic cauterization, and in which, on account of the size and central position of the ulcer, a Saemisch section would have resulted in extensive adhesion.

These are examples of purulent cases, and in them a method of treatment based on etiology is especially valuable and necessary, on account of their dangerous nature.

Even in the case of the non-purulent or 'simple' infiltrates and ulcers, a bacteriological examination is often of considerable value. Between the 'simple' and the purulent cases there is no sharp dividing line. The severe purulent cases often begin as simple infiltrates. It is very important to establish the cause in the early stages of, for instance, a wound keratitis after a superficial injury; we then know what we have to deal with. On account of some peculiarity in the cornea, or in the situation of the ulcer, the clinical appearances may at first be mild, and in the end malignant. In these cases, which at first are mild clinically, I have been able to convince myself that the virulence of the organism—*e.g.*, the *Pneumococcus*—was high, and that on account of immunity, or some refractory condition of the cornea, this high virulence did not show itself.

A bacterial diagnosis is often of value in many of the cases which are non-purulent during their whole course. In these 'catarrhal ulcers,' or marginal infiltrations, the *Diplobacilli* play an important part; and the corresponding cases are very amenable to treatment

[1] Gabriélidès ('Ophth. Microbiologique,' 1907, p. 254) recommended a peculiar treatment for purulent ulcers of the cornea. Having observed that bile had a bacteriolytic action on the *Pneumococci*, and that these organisms did not grow on media which contain this substance, he freely applied to the cornea a sterile solution of sheep's and rabbit's bile (along with hot compresses and iodoform), and obtained good results. Morax has lately made a similar report concerning the action of rabbit's bile (Congr. de la Soc. franç. d'Ophth., 1907).

[2] Our technique is given in the work of Agricola, *K. M. f. A.*, 1906, Beilageheft, and in the section on 'Diplobacillary Conjunctivitis' in this book.

[3] See Agricola, *K. M. f. A.*, 1905, xliv., Beilageheft.

with zinc, even when there is no marked conjunctivitis present. They are very difficult to treat in any other manner.

In a simple keratitis much valuable information can also be obtained. We will not go so far as to say that every corneal infiltration must be examined bacteriologically; that, indeed, would be hardly possible. But in very chronic cases and those which precede suppuration, or show a very markedly infiltrated border, a bacteriological examination can be thoroughly recommended. When such an infiltrate is centrally placed, we should not be so free in taking material from it as from peripherally situated lesions. The pupillary area of the cornea should not be injured. If all precautionary measures are taken, we should not have any great anxiety.

Scrofulous keratitis should be mentioned amongst the cases which are negative bacteriologically. This affection is considered by many to be a staphylococcal infection (Bach, Straub, Zur Nedden). Further research is necessary to settle this question. Keratitis fasciculosa, with its creeping character, proves to be a progressive infection of peculiar type (due to the tendency of scrofular patients to the formation of vessels); in such cases I have often found the *Pneumococcus*. Addario occasionally found the *Staphylococcus*, and Macnab the *Diplobacillus*. Xerose bacilli have been found in simple infiltrates and in sluggish ulcers, but these were secondary, and with no etiological significance. Even in a case like that of Besio (*Annali di Ottal.*, 1900, xxix. 626) the significance of these bacilli is doubtful.

Purulent Keratitis. Hypopyon-Keratitis. Ulcus Corneæ Serpens.

Purulent keratitis, on account of its clinical importance, very early attracted the attention of the bacteriologist. At first experiments were chiefly directed to the determination of the action of the best-known pyogenic organism, the *Staphylococcus*, in the production of inoculation keratitis in rabbits (Leber, Strohmeyer, Hoffmann, Hess, Fortunati, Silvestri, etc.). These experimental investigations, of which those by Leber were the most conclusive, have furnished much information regarding the development of an infiltrate, and especially of a hypopyon.[1] This information can be applied in general to hypopyon-keratitis in man, although it has been established that the

[1] According to Leber, the hypopyon is caused by the toxic chemiotaxis of the organisms in the cornea; it is therefore sterile until the cornea is completely perforated, even though an early perforation of Descemet's membrane has occurred.

most common cause of that condition in man is not the *Staphylococcus*, but the Fränkel-Weichselbaum *Pneumococcus*.

The earliest researches by culture into the cause of purulent keratitis did not show this organism, but either gave a negative result or showed *Staphylococci* and *Streptococci*. This was due to the same cause as interfered with the etiological study of conjunctivitis and many other infectious diseases—namely, that the highly susceptible *Pneumococci* were only demonstrated when better methods were available. In many of the earlier works on this subject an immediate slide diagnosis was not made. In the corneal pus the encapsulated lancet-shaped *Diplococci* are very clearly seen. Widmark and Pfluger certainly described appearances which may have been due to the *Pneumococcus*, but their exact significance remained unknown.

At the end of 1893 Gasparrini published a paper on the 'Significance of the Pneumococcus in Ophthalmology,' in which, besides giving the results of his experiments on animals, he reported having cultivated the *Pneumococcus* from several cases of hypopyon-keratitis, mostly in a pure condition. These observations were confirmed and amplified by Basso and Guaita.

Completely independent of Gasparrini, Uhthoff and Axenfeld began a research on this subject in 1892, and published their results in 1894. They also found a remarkable frequency of the *Pneumococcus*. In their monograph in the year 1896, in which they reported a series of fifty cases and a number of anatomical investigations, they showed that the bacteriological finding of the *Pneumococcus* corresponded to that form of hypopyon-keratitis known as 'ulcus corneæ serpens,' an ulcer which is characterized by a surface spread especially in one direction so as to form a progressive yellow margin at the same time as it is cleaning and being covered with epithelium from the other side. In the rarer cases which do not present this appearance, but that of an 'atypical hypopyon-keratitis,' with a rapid spread deeply, other pyogenic organisms (*Staphylococci*, *Streptococci*, and pyogenic bacilli) are found; and in this group of the non-serpiginous forms of hypopyon-keratitis we can differentiate sharply an etiologically distinct group—the mould keratitis, or keratitis aspergillina.

Uhthoff and Axenfeld concluded their article by stating that variation of the virulence and number of the organisms, the condition of the nidus (*i.e.*, the pre-existing condition of the cornea), and the depth and extent of the original injury, could cause considerable variation from the typical appearance. Since then they have reported on a further series of sixty-eight cases. In this series they showed that the condition known clinically as ulcus corneæ serpens with the exception of one case due to *Diplobacilli* (probably of the Petit type: *vide infra*) was always produced by the *Pneumococcus*. But they also found, as a matter of fact, that a number of the cases of pneumococcal infection presented an atypical appearance. And for these variations they adduced a number of special reasons.

Deep wounds (*e.g.*, after cataract operation) when they suppurate show by their appearance that the whole thickness is affected, and when the site of an infection is at the vascular limbus of the cornea, the action is modified, as Bach has shown. The vascularization of the cornea, which takes place, for instance, in pannus trachomatous, furnishes a powerful resistance to the infection, and in such cases we find pneumococcal infection taking on the form of a simple infiltrate, without any dense progressive border.

Augstein confirms this, and states that an ulcus serpens with *Pneumococci* is very rare in trachoma, even in cases with dacryocystitis, although in these patients epithelial defects, both traumatic and spontaneous, frequently occur. Augstein considers this as proof that trachoma, or rather its causal agent, must have a direct antagonism to the *Pneumococcus*. His view is not based on adequate grounds. What, then, is the relation between the *Pneumococci* in the sac and on the conjunctiva and the trachomatous process? The irregular epidemiological distribution of the affection shows that other factors may possibly be the cause of the infrequency in Egypt of pneumococcal conjunctivitis compared to other forms of infection. In Italy Gasparrini and others have shown that it is very often

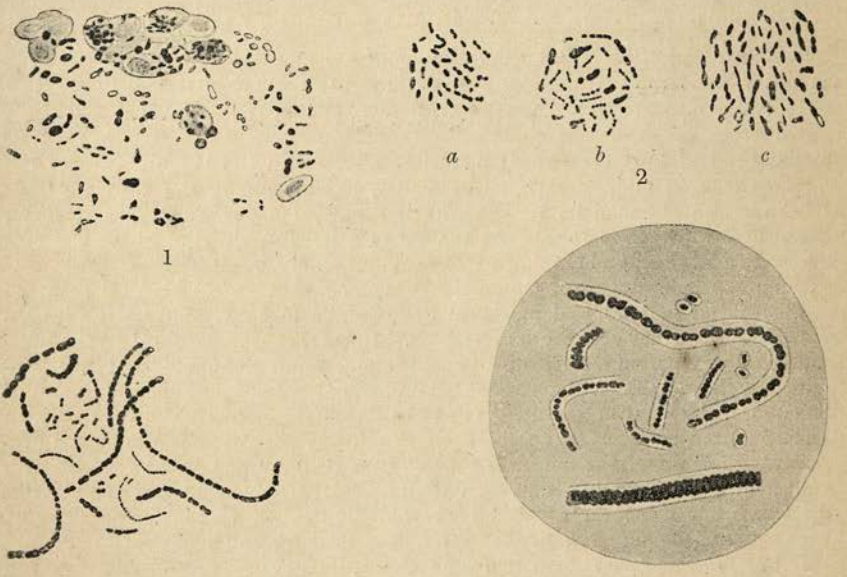

FIG. 65.—UHTHOFF AND AXENFELD: PNEUMOCOCCI FROM ULCERA SERPENTIA. VARIATIONS IN FORM.

1, Pus from the infiltrate in a rabbit's cornea after inoculation, showing phagocytes and involution forms; 2, agar culture (pure) from an ulcus serpens—(*a*) typical *Diplococci*, (*b*) involution forms with short chains, (*c*) pronounced bacillary type; 3, chain-formation in a bouillon culture; 4, unusual formation of capsules and chains in agar, type resembling the *Streptococcus mucosus*.

a complication of granular ophthalmia. And it is quite possible that vascularity of a pannus and cellular infiltration of the cornea may prevent such infections, and perhaps render them innocuous before they have been able to produce the disease.

In scrofulous persons with vascularized cornea, as I have twice been able to show, a pneumococcal infection can produce the appearance of a keratitis fasciculosa—a snail-track ulcer. This peculiar form of keratitis in scrofula is similar to ulcus serpens in its method of advance in one direction, but differs in the absence of a hypopyon, and in its invariable benign course; it never takes on a severe destructive character. Both facts can be explained by the great tendency in these eyes to the development of vessels. A phlyctenule either of the limbus or of the cornea may become

infected with *Pueumococci*. This would explain the origin at the margin; the immediate formation of vessels increases the resistance of the cornea; the progress is therefore centripetal and superficial.

The bacteriological findings in cases of keratitis fasciculosa are not uniform. Addario found *Staphylococci* a few times; A. Macnab, *Diplobacilli*. Further examinations are necessary, and for this we must take material from the very apex of the creeping band, and it must be scraped out, or otherwise the contaminating organisms which lie on the surface can easily cause confusion.

In the literature there are a number of other atypical cases (not superficial) described as due to the *Pneumococcus* (E. von Hippel, Doetsch, Petit, Hertel, Holden, Bach, and Neumann). There are also those cases of perforative keratomalacia in marasmic children, in which Uhthoff and Axenfeld have found *Streptococci;* Loeb, *Pneumobacilli;* Fränkel, Franke, and Schanz, *Staph. pyog. aureus;* and Macnab, *coli* with *Gonococci*.

In these children the rapid penetration of the cornea by the *Pneumococcus* can be understood when we consider how the lowered general condition of the body reacts on the resisting power of the tissues—a reaction known to occur in diseases of the cornea. Similar conditions obtain when infections of the cornea are added to severe conjunctival affections (gonorrhœa, diphtheria).

Since then further research (Secondi, Cuénod, Bach and Neumann, Panas, Hertel, De Schweinitz, Vossius, Petit, Doetsch, Kibbe, Vallaude, Velhagen, Römer, Horsmann MacNab, Angus Macnab, Paterson, Calderero, Zur Nedden, Schmidt, Salvaneschi, Tertsch, Morales[1]) has shown that the ulcus serpens is pre-eminently an infection with the *Pneumococcus*, and that an early infiltrate which contains *Pneumococci* will, if it continues, develop into a serpiginous ulcer.

There are exceptions to this rule. In three cases Petit found a peculiar bacillus which closely resembles the Morax-Axenfeld bacillus, only differing from it in some of its peculiarities of growth (*vide infra*). Since then Macnab and Agricola have reported cases in my clinic, and Erdmann, Rochat, Paul, Augstein, Benedetti, and McKee other cases, in which such bacilli were found; in some of them the Morax-Axenfeld bacillus, and in others the Petit type. After the *Pneumococci* the next most frequent cause of an ulcus serpens is the *Diplobacillus*. On close examination the majority of the cases which I have seen showed not only a serpiginous edge, but also a marked and often deep infiltration of the base of the ulcer.

In my last eighty cases of hypopyon-keratitis fifty-five were caused by *Pneumococci*, and these were all ulcera serpentia; of the twenty-five caused by *Diplobacilli*, about half were serpiginous, and to some extent showed a definite infiltrated border.

Gourfein records the occurrence of Friedländer's bacillus in typical hypopyon-keratitis. In this connexion Gourfein holds the view that it is not because of any special activity of the *Pneumococcus* that it is so often found in an ulcus serpens, but from the coincidence that it is the most frequent organism in the vicinity of the injured cornea, its frequent presence in the ulcer being due to its prevalence in the pus from the lacrymal sac and on the normal conjunctiva. The *Pneumobacilli* and the other suppurative organisms have the same relation to the clinical appearances, only they do not occur so frequently in the immediate neighbourhood of the cornea.

This question is of vital importance. When we consider the available facts, it appears that Gourfein's opinion is not justifiable, although it is quite true that the

[1] In Morales' case we find *Streptococci* very frequently recorded as occurring with *Pneumococci*. It is not quite clear whether this is not merely a culture differential diagnosis (*cf.* p. 183). It is questionable whether the Friedländer *Diplobacillus* which he found in so many cases was not the Morax-Axenfeld or Petit bacillus, especially as diplobacillary cases are not recorded to have occurred in the whole series.

THE ASIATIC SOCIETY OF BENGAL LIBRARY

Pneumococcus is the most common organism in contact with the injured cornea for in the first place Uhthoff and Axenfeld have shown, and Römer has confirmed, that in those cases in which other pyogenic organisms were present along with the *Pneumococci* in the pus from the sac, the *Pneumococcus* alone was constantly present in the ulcer—a proof that either the *Pneumococcus* has a peculiar affinity for the cornea, or that in a mixed infection it will completely overgrow the other organisms present. It has also been established that in those cases which do not contain the *Pneumococcus*, but in which other organisms (*Staphylococcus*, *Streptococcus*, *Bacillus pyogenes fœtidus* (Uhthoff-Axenfeld), *Bacillus pyocyaneus*, ozæna bacillus, *Bacterium coli*, influenza bacillus (Doetsch and Zur Nedden), have been found, the appearances were not those of ulcus serpens, but of an atypical hypopyon-keratitis, even though the determining cause of the infection (the small superficial wound) was the same. Such records appear in the works of the authors above quoted, and also in those of Kalt, Morax, Coppez, Zirm, Hori, Schimmelpfennig, in such numbers that there can be no doubt that the other pus-producers—with the exception of the *Diplobacillus*—only in exceptional cases produce a serpent ulcer typical in every respect.[1] Zur Nedden's results prove that such exceptional cases do occur; he found a pathogenic *Subtilis* in two cases of ulcus serpens, and from another he cultivated the *Streptococcus*. Kruger and Hanke in single cases found a bacillus like a proteus; Bach and Neumann found short rods, which were not fully identified.

It is no idle question to ask why, when they settle down in a superficial wound, *Pneumococci* have a tendency to this superficial spread, and that, too, in one direction; whilst at the same time the part first affected is so rapidly cast off with the formation of fresh epithelium, that the healing process is at work close behind the necrotic spread. Uhthoff and Axenfeld have shown that the *Pneumococcus* in the tissues of the cornea, just as in culture, rapidly loses its virulence when accumulated into dense masses. The organisms are then cast off, and cannot penetrate into the deeper layers of the lamellæ, though they are still able to find their way in the horizontally arranged lymph spaces. Römer does not put this influence completely aside, but he considers that the changes in the affected tissue are due rather to the fact that they have become more susceptible to the fermentative action of the leucocytes, and can be thus cast off. The details of how this occurs cannot be determined in every case.

Uhthoff and Axenfeld have shown that the *Pneumococci* are most thickly intermingled with leucocytes at the progressive border. Enormous numbers of phagocytes are often found here. This is clearly seen in Fig. 66, and is taken by Doetsch to be the explanation

[1] On closer examination I find that two of Gourfein's three cases did not exactly correspond to what we call *Ulcus corneæ serpens*, in that the base of the ulcer was purulent, and the superficial spread was not very definite. In the cultures from one of the cases *Diplococci* were found growing in chains, but not pathogenic in animals; this is often the case with *Pneumococci*. Gourfein does not say whether the secretion was taken from the margin, a precaution necessary in determining the organisms present; he only speaks of 'Sécrétion prise sur l'ulcère.'

why the organisms are often only to be demonstrated when the material is taken from the deeper layers.

To facilitate cultural diagnosis, Römer recommended that the *Pneumococci* should be augmented, so that smaller numbers could be more readily seen; he did this by cultivating the material in a bouillon, to which one-third of its volume of sterile rabbit s serum had been added.

Large numbers of phagocytes have been found in severe cases, justifying the opinion that in this process, just as in fatal cases of pneumococcal meningitis, large numbers of phagocytes may be found. The

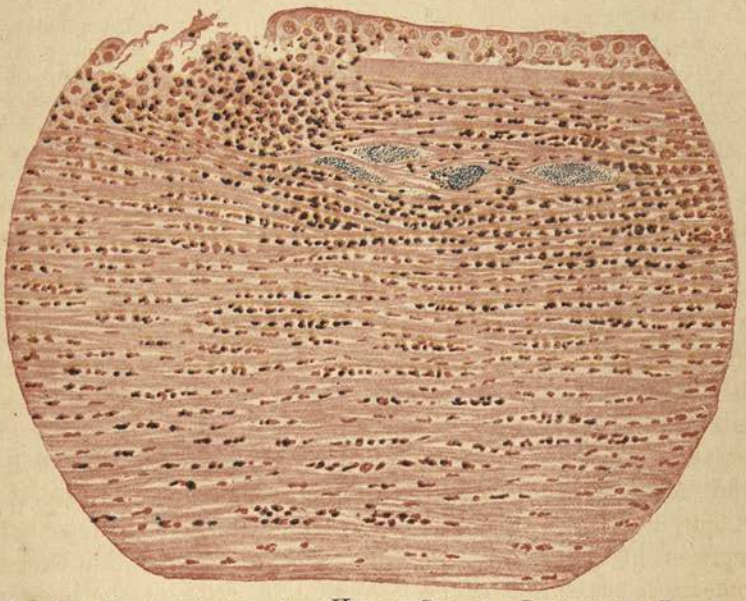

FIG. 66.—PNEUMOCOCCI IN THE HUMAN CORNEA. PROGRESSIVE BORDER. GRAM-WEIGERT STAIN. PNEUMOCOCCI BLUE.

possibility, however, cannot be excluded that active *Pneumococci* may have spread into a part of the cornea which until then was quite healthy. Zur Nedden states that after a Saemisch section he found the healing process going on parallel with the phagocytosis.

The beneficial influence of paracentesis in the course of an ulcus serpens certainly depends on the fact that, after the rupture of Descemet's membrane, bactericidal elements can freely pass forwards at the same time that the nutrition of the cornea is improved. The *Pneumococci* then rapidly begin to show marked involution changes, and cultivations can only be obtained for a short time. The purulent

border then disappears (according to Saemisch, this begins at its upper edge), and the ulcer clears.

(The common histological peculiarities of a purulent keratitis in man will not be discussed here.)

It is a peculiar fact that a typical ulcus serpens has almost never been found in a child. Augstein described a typical case with *Pneumoccoci* in a child of six years. The chief reason for this is that lacrymal troubles are much rarer in them than in adults. Whenever pneumococcal infection of the cornea has been observed in children it has taken the form of keratomalacia, and has occurred in ill-nourished infants (E. von Hippel, Knaebel, Braunschweig, Doetsch, Macnab[1]) in atypical ulceration after measles (Hertel), with an exceptionally severe conjunctivitis in the new-born (Gasparrini), or in very severe pseudo-membranous conjunctivitis (Beckers).

Duane and Hastings state that *Staphylococci* are especially important in the ulceration of the cornea which occurs in catarrhal conjunctivitis. There is no proof that such is the case.

In an ulcus corneæ serpens the *Pneumococci* mostly lie in the yellow progressive margin, amongst the infiltrating leucocytes. If material be taken from this situation, they are found in the smear in large numbers, and with evident capsules. The cultures are characteristic of the *Pneumococci* found in other places, and agree with them in every respect; there is the same difficulty in their culture. Their pathogenicity is generally not great in culture. Uhthoff and Axenfeld came to the conclusion that a diminution of virulence must be presumed to have occurred in these pyogenic *Pneumococci.* Römer agrees with this for the majority of cases, but considers that the factor of adaptation must be considered.

The final proof of the identity of the *Pneumococcus* of ulcus serpens with that of croupous pneumonia is furnished by Römer, who succeeded, by the action of the first organism, in making susceptible animals immune to the latter.

A keratitis can be produced in the cornea of the rabbit, the intensity of which will vary, according to the quantity and the virulence of the material introduced, from a severe hypopyon-keratitis to a simple infiltration (Gasparrini, Cuénod, Uhthoff and Axenfeld, Bach, Noeldeke, De Schweinitz, Veasy, Augstein); a typical ulcus serpens has never been produced. Uhthoff and Axenfeld once obtained a peculiar interstitial ring infiltration, but this was not typical. On the other hand, Römer obtained a typical ulcus serpens in apes.

Römer has undertaken comprehensive tests to produce, by means

[1] In Braunschweig's and in Doetsch's cases *Staphylococci* and *Streptococci* were also present.

of subcutaneous injections of pneumococcal serum, an immunity against the ulcus serpens; he also attempted to show experimentally whether a general immunity could occur from an ulcus serpens. Such was not the case to any appreciable extent.

Ulcus serpens, and, indeed, any severe corneal infiltration, is rare in pneumococcal conjunctivitis. Cases have been described by Petit and Hertel. Gasparrini reports that he has often seen slight (catarrhal) marginal ulcers; this has not been the experience of Axenfeld, Junius, and Gifford.

It is only in very exceptional cases that the object causing the injury also carries in the infection; affections of the lacrymal sac, contaminations with sputum,[1] etc., are the most common infecting agents. In many cases, perhaps, the cocci normally present on the conjunctiva may have some action. A lesion of the epithelium is necessary for the occurrence of the infection, as the *Pneumococci* cannot, like the diphtheria bacilli, loosen the epithelium by the action of their toxins (Coppez). So that we may see a cornea bathed for years in lacrymal pus rich in *Pneumococci* without any damage, until an epithelial lesion is produced by an injury, or in some other way (*e.g.*, by a herpes).

That peculiar infection of old adherent corneal scars, which often progresses rapidly into the interior of the eye, has been shown by the researches of Wagenmann, confirmed by Terson, Dolganoff, and Sokolow,[2] to be of ectogenous nature. The infection finds its way into the scar through an epithelial defect. In sections of such cases Wagenmann demonstrated *Diplococci* and chain cocci most frequently; by cultures I have most commonly found *Streptococci* and *Pneumococci*. Terson records *Pneumococci*.

In a few isolated cases of purulent keratitis, the *Bacillus pyocyaneus* has been proved to be pathogenic for the human eye. The cases recorded by Gallenga, Bietti, Macnab, De Berardinis, Szczbalski, D. Smith, Callan, and A. Ewing, were obviously due to very virulent bacteria; in them an extensive necrosis of the cornea was very

[1] Hotta conducted experiments in Uhthoff's laboratory to determine the action of sputum on superficial corneal injuries in rabbits. A hypopyon-keratitis only occurred when a pocket had been made; it never occurred in a perforating wound, and only once in a superficial erosion. The infectiousness of the sputum varied, and the organisms present in the corneal ulcers varied: in 36 per cent. *Pneumococci*, in 56 per cent. *Streptococci*, in 30 per cent. *Staphylococci* occurred. Mixed infection occurred with comparative frequency in these experiments. Doetsch considers that infection from sputum is rare, especially from the contamination of handkerchiefs, etc., and in those cases where a corneal infection occurs without any sac affection or conjunctivitis, he would consider the condition to be due to the occasional occurrence of *Pneumococci* on the healthy conjunctiva.

[2] *A. f. A.*, 1903, xlvii. 361. See the literature here.

evident, and the base of the ulcer was covered with the necrotic debris of the corneal lamellæ. The process can take on the form of a ring abscess (*vide infra*). The toxins from the cornea so act on the tissues around that the conjunctiva bulbi may swell and give the impression of a panophthalmitis before the deeper parts of the vitreous are suppurating. This is due to the free formation of toxins. Slight cases may also occur; according to Herbert (Bombay), a *Pyocyaneus* obtained from a slight case of keratitis, when inoculated on to the conjunctiva, produced small abscesses and a superficial keratitis without any deep destruction. These experiments, with those of A. Ewing, show that many strains of *Pyocyaneus* can have a pathogenic action on the unwounded conjunctiva, and from there can attack the cornea, first through a digestive action, then by infection; a *Pyocyaneus* conjunctivitis has been described by G. S. Derby. In the cases of severe keratitis quoted above an injury could not be proved to have occurred in every instance.

According to Ewing, a single inoculation with this organism produces an immunity against renewed infection in the cornea lasting for six to eight weeks.

The Bacillus Pyocyaneus (bacillus of green or blue pus) (Plate III., Fig. *IV.*).—A small slender rod, approximately of the same length and thickness as the Koch-Weeks bacillus,[1] either single or in pairs, and in culture forming long filaments; Gram-negative. Freely motile, with a terminal cilium. Grows as a facultative aerobe on the ordinary media even at room temperature. Rapidly liquefies gelatine, causing green fluorescence in the neighbourhood of the growth. Bouillon becomes cloudy and stains a yellowish-green. On agar a whitish-grey scum forms, the medium becoming green to a variable extent and shade; glycerine agar becomes dark blue. On potatoes the growth takes the form of a thick scum, yellowish-green to brown in colour. Blood-serum is rapidly liquefied.

The pigments formed are: (1) pyocyanin—blue, soluble in chloroform, and thus easily extracted from the medium; (2) a pigment insoluble in chloroform, and of a greenish fluorescence. The formation of these pigments is influenced by the nature of the medium.

The differentiation of the two varieties (*B. pyocyaneus*, α and β) is now generally given up, as a definite separation is often impossible.

Many strains of the *Pyocyaneus* freely form toxins, which pass out into the media. Rabbits and guinea-pigs are very susceptible. Wassermann states that both an antitoxic and a bactericidal immunity can be produced. The latter is so intense that the Pfeiffer reaction (as in the case of the cholera vibrio) can be obtained in the abdominal cavity of the immunized animal in a very short time.

Virulent strains have a powerful necrotic and suppurative action (Sattler) in the eye, especially in the vitreous, but also in the anterior chamber or the cornea—so

[1] Seeing that the Koch-Weeks bacillus can only infect the cornea in the course of a typical conjunctivitis, and even then almost never causes a purulent keratitis, such a finding in the cornea as is shown in Plate III., Fig. *IV.*, with a hypopyon-keratitis at once raises the suspicion of *Pyocyaneus*. It can easily be differentiated from the other organisms which produce this condition (*cf.* the plate).

much so that Herrenheiser places them at the head of the pyogenic organisms in the eye. This is only true for individual strains.

(Further records[1] are furnished by Sattler: 'Panophthalmitis after a Perforating Wound'; Terson, 'In Dacryocystitis'; Schanz, 'In Traumatic Panophthalmitis.' In these cases also the remarkable distant action of the toxin was recorded: in a circumscribed abscess of the vitreous the appearance of a complete panophthalmitis can be produced.)

In experimental researches regarding the production of metastatic inflammations, the *Pyocyaneus* has been extensively used in the pathology of the eye. Panas and Moll have shown that *Pyocyaneus* will readily settle down in the eye from the blood-stream.

Stock regularly obtained metastases in the iris, which, in spite of the virulence of the bacilli, healed spontaneously. He also obtained a benign spontaneously healing choroiditis disseminata (*vide* Stock, *K. M. f. A.*, 1903, Bd. I., S. 118).

According to Fuchs,[2] a so-called **ring abscess** of the cornea is caused by a very severe bacterial toxic action from the anterior chamber in cases of injury or metastasis. From the anterior chamber of an injured eye with a ring abscess Hanke cultivated a bacillus which on inoculation into the cornea always produced a ring abscess, and which he regarded as bearing a very close relation to the *Bacillus proteus fluorescens*.[3] Macnab, working in my laboratory, proved that the bacillus of Hanke belongs to the *Pyocyaneus* family, as it formed the characteristic pigments (the chloroform extract gave the blue pyocyanin). The *Pyocyaneus* is a very powerful toxin producer, and therefore is very prone to the formation of extensive necrosis with final ring abscess. Hanke's contention that the separate identity of his bacillus and the *Pyocyaneus* is obvious from their different pathogenic actions is not convincing. Even though he was always able, with an old culture of his bacillus, to produce a ring abscess,—which was not possible with a fresh *Pyocyaneus*,—his argument is invalid, because the toxic activity of the *Pyocyaneus* varies very much, and in no way depends on the age of the culture. Other organisms may cause a ring abscess—for example, *Staphylococci*, *Streptococci*, and *Pneumococci*, acting from the inside of the eye. The latter of these organisms was

[1] Haab, *A. f. O.*, 1897, xliv., I., p. 201. Herrnheiser, *Prager Zeit. f. Heilkunde*, 1893, xvi. Sattler, 'Verhandl. der Heidelberger ophth. Versammlung,' 1892, p. 156. Gallenga-Bietti, *Ann. di Ottal.*, 1899, xxviii.; 1905, xxxiv., Nos. 11, 12. Herbert, Ophthalmic Review, 1901, p. 345. Schmidt, *A. f. A.*, 1902, xlv. 79. De Berardinis, *Ann. di Ottal.*, 1903, xlii. 789. Schanz, 'Die Bakterien des Auges,' Unterrichtstafeln von Magnus, 1897, text. Terson, in Jaulin's *Thèse de Paris*, 1895. Derby, 'Pyocyaneus Conjunctivitis,' The American Jour. of Ophth., 1905, No. 1. Smith, Dorland, Arch. of Ophth., 1906, xxxv., 'Necrotic Hypopyon-Keratitis.' Callan, T. Amer. O. S., 1906, p. 201. Ewing, A. E., '*Bacillus pyocyaneus* in the Eye; its Longevity, and Immunity from it,' T. Amer. O. S., 1906, p. 204.

[2] *A. f. O.*, 1903, lvi. 1. An exact pathological account of the ring abscess of the cornea can be found here, and also in the work of Morax (*Ann. d'Ocul.*, 1904, cxxxii. 409).

[3] According to Ruzicka, the *Bac. fluor. liquefaciens* is closely allied to the *Pyocyaneus* (*Zent. f. Bakt.*, 1898, xxiv. 11). Lehmann-Neumann places it in the *Pyocyaneus* group.

found by Morax and Axenfeld in a case of ring abscess in a metastatic ophthalmia, so that from a bacterial point of view a 'ring abscess' is not a definite infection. Stower[1] found a Gram-negative bacillus of the *Proteus* type, which did not form pigment; an exact cultural determination was not carried out.

In diphtheria the suppuration of the cornea is principally due to the pyogenic organisms; the diphtheria toxin prepares the way for their action (Coppez). The diphtheria bacilli can cause a necrosis, but not a suppuration, in the cornea.[2] Similarly, secondary infections play an important part in gonorrhœal affections of the cornea, though the *Gonococci* can cause a suppurative destruction of the cornea, and even find their way into the iris (Dinkler, Morax). The exceptional severity of gonorrhœal infections of the cornea is emphasized by Butler (Palestine).

Augstein has undertaken a systematic examination of simple infiltrates of the cornea occurring in cases of trachoma. In the large and small grey infiltrates he almost always obtained a negative result. Thirty-five ulcers were examined; *Pneumococci* were found in abundance in four cases which were not ulcera serpentia, and which soon healed with the customary treatment for granular ophthalmia. In one case *Diplobacilli* were found, and in ten the *Bacillus xerosis;* in eighteen cases the findings were negative, though the ulcers were deep and severe. The negative cases, amongst which those with the xerosis were included, were considered to be due to the action of the trachoma virus. The fact that the *Pneumococci* in these four cases did not cause any difference in the appearance of the ulcers is due to the increased resistance of the cornea in this disease. Amongst the rare cases of ulcus serpens in trachomatous patients, some were very mild in their course, even when there was no pannus.

Infection of the cornea with the Koch-Weeks bacillus, fully described in the monograph by Petit, occurring in cases of conjunctivitis due to this organism, does not, as a rule, take on a purulent form; it remains superficial.[3] It is very rare to find these organisms alone in a severe corneal suppuration. A few such cases are given by Petit and by Butler. The infiltrates are most commonly found near the periphery (catarrhal ulcers), and they produce an appearance which resembles the 'infectious ulcer' of Zur Nedden. Zur Nedden himself admits that such an appearance is not necessarily caused by his

[1] Stower, *K. M. f. A.*, March and April, 1907, xlv. 1.

[2] On this subject Tschirkowsky contributes an important article in *A. f. O.*, lxviii., i., 1908.

[3] See the chapter on 'Conjunctivitis.'

bacillus alone; in many cases it is due to the *Staphylococcus* or other organism.

Corneal infections from the influenza bacillus are described by Zur Nedden and A. Knapp.

De Berardinis reports having cultivated *Streptothricæ* from superficial corneal ulcers; in one case there were several varieties. Inoculation experiments with the same organisms also produced superficial ulcerations.[1]

LITERATURE.

ADDARIO, Keratite fasc. Arch. di Ottalm., 1904, XII, p. 1.

ARENS, Keratites suppuratives. Arch. méd. belges, October, 1904.

AXENFELD, Serumtherapie in inf., August, 1905. Further, see UHTHOFF and A. UHTHOFF.

BACH and NEUMANN, Die eitrige Keratitis beim Menschen. A. f. A., 1897, Bd. 34.

BASSO, Internat. Kongr. in Rom, 1894, ferner Cheratite ipopion da bacillus mucosus ozaenae. La clinica ocul., 1903, p. 1479.

BARGETON, Un cas de botryomycose de la cornée. Lyon, 1905.

BENEDETTI, La clinica ocul., 1906, VII, S. 2690.

BIETTI, Il bacillo piocianico nel cherato ipopion. Ann. d'ottalm., 1898, vol. 27, p. 578, also ibidem, 1905, XXXIV, 11.

BROSE, Ulc. corn. serp. The Ophth. Rec., 1904, p. 55.

DE BERARDINIS, Ulcera corn. da bact. coli. Ann. di Ottalm., 1904, XXXIII, p. 18.—*Ibid.*, Ulc. corn. da streptothrix. *Ibid.*, pp. 385 and 914.

BUTLER, T. H., Clinical Features, etc., of Acute Ophthalmia. R. L. O. H. Rep., XVII, i., p. 115.

CALDERARO, Clinica oculist., August, 1903.

COLLOMB, Arch. d'ophth., 1903, S. 129.

COLOMBO and RICCHI, Ann. di Ottalm., 1904, XXXIII, p. 865.

COPPEZ, H., Des altérations cornéennes dans la diphth. de l'œil. Rev. gén. d'opht., 1895, p. 177.—*Ibid.*, Journ. méd. de Bruxelles, August 31, 1899, Nr. 35.

CUÉNOD, Bactériologie et Parasitologie clinique des paupières. Thèse de Paris, 1894.—*Ibid.*, Du pneumocoque en pathologie oculaire. Congrès de la Société française d'ophthalmologie, May 6-9, 1895, t. 5.

DINKLER, Zwei Fälle von Ulcus perforans corneae nach conjunctival-Tripper. (Tripperkokken im Gewebe). A. f. O., 1888, Bd. 34, 3, S. 5.

DOETSCH, Anatomische und bakteriologische Untersuchungen über infantile Xerosis und Keratomalacie, sowie Bemerkungen über die Verhornung des Bindehautund Hornhautepithels. A. f. O., Bd. 49, 2, S. 405, and Ophth. Klinik., 1900, Nr. 18/19.

ERDMANN, Diplobazillen-Keratitis (*cf.* 'Diplobacillary conjunctivitis').

FUCHS, Keratomykosis aspergillina. Wiener klin. Wochenschr., 1892, Nr. 17.—*Ibid.*, Ringabszess d. Cornea. A. f. O., 1903.

GASPARRINI, Il diplococco di Fränkel in pathologia oculare. Ann. d'oftalm., 1893, vol. 22.

GNAITE, Le diplocoque de Fraenkel en pathologie oculaire. Internat. Congress in Rome, 1894.

GOURFEIN, Revue Méd. de la Suisse Romande, 1902, Nr. 2.—*Ibid.*, Bac. subtilis, X. Congrès Intern. Luzern.

[1] There is also a recent record by Zur Nedden, who found an aerobic *Streptothrix* in a case of keratitis disciformis, which went on to suppuration.

HANKE, Zeitschr. f. Augenh., 1903, II, Ringabszess.—*Ibid.*, Zeitschr. X, 1903, S. 373, K. M. f. A., 1905, I, S. 724, and Wiener klin. Rundschau, 1906, Nr. 26.—*Ibid.*, Proteus-infection. Ophth. Ges. Wien, April 17, 1907.

HERBERT, Keratitis punctata (Bombay). Ophth. Review, 1901, p. 335.

HERTEL, E., Über eitrige Keratitis beim Menschen. A. f. O., 1901, Bd. 53, 2.

HIPPEL, E. v., Das Geschwür der Hornhauthinterfläche (Ulcus internum corneæ). Sep.-A. aus der Festschrift zur Feier des 25jährigen Professoren-Jubiläums von Geheimrat v. Hippel in Halle, 1899.

HOLDEN, Examen clinique et anatomique d'un ulcère serpigineux de la cornée causé par le pneumocoque. Ann. d'ocul., 1898, 119, p. 463.

HORI, Zur Anatomie einer Ophthalmia hepatica. A. f. A., Bd. 31, S. 393, and Heidelberger Kongress, 1895.

HOTTA, Infektion der Cornea durch Speichel. K. M. f. A., 1905, XLIII, II, S. 237.

KALT, Ulcération cornéenne dans l'ophthalmie purulente. Mode de propagation des microbes. Société de biologie, December 7, 1895.

KNAEBEL, Keratomalacie. Inaug. Dissert., Tübingen, 1901.

KIPP, Hypopyon ulcer. Amer. journ. of ophth., November, 1904.

KOUN, De la Kératomalacie. Thèse de Bordeaux, 1903.

KRUGER, Z. f. A., 1903, IX, S. 192.

LEBER, Keratomykosis aspergillina als Ursache von Hypopyon-Keratitis. A. f. O., Bd. 25, 2, S. 285.—Die Entstehung der Entzündung. Leipzig, 1893.

LUNDSGAARD, Ein Fall von Hypopyon-Keratitis mit Reinkultur von Hefe. K. M. f. A., January, 1900.

MCKEE, Ulc. of Cornea from M.-Ax. Diplobacillus. Ophth. Record, 1907.

MCNABB, H. HORSMANN, Bact. Exam. of Twenty-five Cases of Serpent Ulcer of the Cornea with Hypopyon. Ophth. Review, 1906, p. 67.

MACNAB, A., Klin. Monatsbl., XLII, 1904, 1, S. 54.—*Ibid.*, Über Infektion der Cornea durch den Bacillus pyocyaneus. K. M. f. A., 1904, XLII, Bd. 1, S. 65.—*Ibid.*, Ulceration of the Cornea. London (Baillière, Tindall and Cox), 1907.

MORALES, A., Ulceras infectiosas de la Cornea. Arch. do oft. Hist. Amer., 1907, VII, p. 147.

MORAX, La Conjonctivite subaiguë, étude clinique et bactériologique. Ann. d'oculistique, 1897, t. 124, p. 5.—*Ibid.*, Ann. d'ocul., 1904, CXXXII, p. 409.

MORAX et PETIT, Considérations cliniques et bactériologiques sur les inflammations aiguës de la conjonctive. Annales d'oculist., 1898.

OLLENDORF, A. f. O., 1900, Bd. 49, S. 455.

PAINBLAN, Contribution à l'étude du rôle du pneumocoque en pathologie oculaire. Thèse de Lille, 1897.

PANAS, Arch. d'opht., 1902, XXII, p. 157.

PAUL, K. M. f. A., 1905, XLIII, I, S. 54 and 154.

PATERSON, Notes on the Bacteriological Investigation of Thirty Cases of Hypopyon Ulcer of the Cornea. The Scot. Med. and Surg. Journ., 1904, S. 505.

PETIT, P., Sur une forme particulière d'infection cornéenne à type serpigineux. Annales d'oculist., 1899, p. 166.—*Ibid.*, Recherches cliniques et bactériologiques sur les infections aiguës de la cornée. Paris, Steinheil éd., 1900.

ROCHAT, Diplobazillen bei Ulc. serp. Nederl. Tijdschrift v. Geneeskunde, 1904, S. 718. (K. M. f. A., 1905, I, S. 524.)

RÖMER, Experimentelle Grundlagen für klinische Versuche einer Serumtherapie des Ulcus corneae serpens nach Untersuchungen über Pneumokokkenimmunität. A. f. O., 1902, Bd. 54, 1.

SALVANESCHI, Annali di Ottalmol., XXXV, 1906.

SCHIRMER, Ein Fall von Schimmelpilzkeratitis. A. f. O., 1896, Bd. 42, 1.

SCHIMMELPFENNIG, W., Über einen Fall von infantiler Conjunctivalxerose mit Keratomalacie. A. f. O., 1897, Bd. 43, 1, S. 41.
SCHMIDT, Arch. f. Augenh., 1902, XLV, S. 79.
SCHUMWAY, Sect. of Ophth. Philadelphia, 1906, Ap.
DE SCHWEINITZ, G. E., Wound of the eyeball. Mikroorganisms. 46. Amer. med. Assoc. Baltimore. Ophth. Review, p. 32, and Ann. d'ocul., 1899, T. 121, p. 136.
SECONDI, Sul cherato-ipopion. Clinica moderna, 1895, 1.
SMITH, D., Arch. of Ophth., 1905 and 1906, 34 and 35.
STOEWER, Ein Beitrag zur Ätiologie der Keratitis. XII. Congrès intern. Section IX. ophth., p. 29.—Über die Wirkung pathogener Hefen am Kaninchenauge. A. f. O., Bd. 48, 1, S. 178.—K. M. f. A., 1905, XLIII, II, S. 142.
SZCZBALSKI, Pyocyaneus. A. f. A., 1905, LI, S. 249.
UHTHOFF, Beiträge zur pathologischen Anatomie des Auges. Partielle Nekrose der menschlichen Hornhaut durch Einwanderung von Schimmelpilzen. A. f. O., 1881-1883, Bd. 29, 3, S. 178.
UHTHOFF and AXENFELD, Bakteriologische Untersuchungen bei eitriger Keratitis, besonders dem Ulc. serp. Naturforscherversammlung in Wien, 1894.—*Ibid.*, Eitrige Keratitis des Menschen. Vortrag des ersteren auf dem Heidelberger Kongress, 1895, der Naturforscherversammlung in Lübeck. Berliner klin. Woch., 1895.—*Ibid.*, Beiträge zur pathol. Anatomie und Bakteriologie der eitrigen Keratitis des Menschen. A. f. O., 1896, Bd. 42, 1 (*cf.* here older Literature).—*Ibid.*, Weitere Beiträge zur Bakteriologie der Keratitis des Menschen. A. f. O., 1897, Bd. 44.
VALLAUDÉ, Thèse de Bordeaux, 1901, S. 78.
VELHAGEN, Münch. med. Woch., 1901.
VOSSIUS, Statistik des Trachoms. Sep.-A. aus den Arbeiten des in Budapest, 1894, abgehaltenen VIII. internat. Kongr. f. Hyg. u. Dermographie, 1897.
WIDMARK, Quelques études de bactériologie ophthalmique. Archives d'ophth. July, 1889.
ZUR NEDDEN, Seltene Infektionskrankheiten der Hornhaut. K. M. f. A., June, 1906, Bd. 1.—*Ibid.*, A. f. A., 1905, 52, S. 143.—*Ibid.*, A. f. O., 1907, XLV, p. 267.

Amongst the infectious forms of keratitis, the **infection with the mould fungi—'keratomycosis'**—merits a consideration quite apart.[1]

Leber's excellent researches have shown that when a rabbit's cornea is infected with the spores of the *Aspergillus fumigatus*, a necrosis occurs around the site of inoculation, and at its periphery a dense infiltration ring is formed. The necrotic mass of tissue riddled with the mould is then cast off *in toto*, like a sequestrum.

Those observers who have recorded cases in human beings (Leber, Fuchs, Uhthoff, Axenfeld, Schirmer, Markow, Basso, Collomb, Gentili, Ball, Wicherkiewicz, Kayser, Ellet, Johnson, Buchanan, Osterroth, Martin, Zade) agree that the strange-looking, dry, slightly prominent, diseased area is separated from the surrounding tissue by a demarcation ring, and is slowly cast off. (In the differential diagnosis it should be noted that Martin, in the *A. f. A.*, 1905, li., p. 141,

[1] Literature: see Kayser, *K. M. f. A.*, 1903, xli., Bd. i., and Johnson, *ibid.*, Bd. 2.

found a grain husk adherent to the cornea, and enclosed in a bacterial mass consisting of the *Bacillus xerosis*. De Bono, in the *Ann. di Ottal.*, 1905, xxxiv., p. 946, found the *Mucor mucedo* in a 'pseudo-membrane' covering the cornea and only loosely adherent to it, which healed without leaving any trace.) In the sequestrum which is permeated with the mycelium the corneal lamellæ are completely necrosed.

In most cases reproductive organs were not seen in the cornea; in Ball's case alone was there any hint of the presence of *Aspergillus*. Recently Zade has reported the occurrence of fructification organs in two cases on the surface of particles taken from the centre of the affected area. The cases were characterized by their special chronicity, and the absence of any sequestrum formation. Eight animals were inoculated with this *Aspergillus*, and in two of the cases Zade found the fructification organs in the centre of the cornea. He states that they could only be obtained with fresh material, and after conservation they readily disappeared. They first appeared at a late stage, about the sixth day, and even then only on the surface and in the centre.

As a rule, the infection is due to earth or some vegetable substance. In the single cases recorded by Uhthoff and Axenfeld, B. Kayser, and Johnson, the foreign body was still visible in the sequestrum. I have shown on other occasions, and would again note here, that there is a *mild form of keratomycosis*, which when only superficially observed appears like a dense infiltrate or a keratitis fasciculosa (see Fig. 68). The three cases last mentioned were considered as such a keratitis, but on closer examination I was able to demonstrate a peculiar small, delimited nodule, in which the suspected mould was found. Martin recorded a similar case.

Cultures made with every precaution showed that these cases were due to *Aspergillus fumigatus*.

The *Aspergillus fumigatus* has the following characteristics: Besides growing on the ordinary media, they will grow well on acid substances (potatoes, bread-infusion, yeast). The young colonies are soft white; when the mycelium forms, the centre becomes greenish, then greenish-grey, and finally the whole culture is smoky-grey, from the formation of large numbers of spores.

The varieties of *Aspergillus* are characterized by variations in the spore-bearing organ. This rises out of the mycelium, and ends in a knob bearing the radially-arranged 'sterigmen,' from which the spores (conidia) bud off (*cf.* Fig. 62). The best method of examining speci-

mens is in hanging-drop, or in some glycerine in which particles taken from the cornea have been squeezed out. The preparation should not be stained. In sections the mould is best stained by the Gram-Weigert method. The aniline dyes are not so good (the basic ones being worst, especially the commonly-used Löffler's methylene blue).

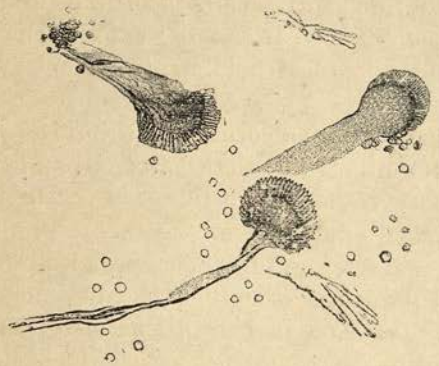

FIG. 67.—ASPERGILLUS FUMIGATUS[1] CULTURE.
Reproductive organs with the sterigmata; conidia fallen off.

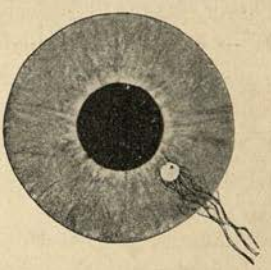

FIG. 68.—MILD FORM OF KERATOMYCOSIS ASPERGILLINA (FREIBURG CASE).

FIG. 69.—KERATOMYCOSIS ASPERGILLINA.
Vegetable foreign body with mycelium. Case from the Freiburg clinic (*cf.* Kayser).

[1] From Plaut, 'Kolle-Wassermann Handbook,' 1903, vol. i., p. 559.

The record by Ellet is inexact. He takes no account of the previous literature, and without any particulars speaks of *Aspergillus niger*. *Penicillium glaucum* is recorded in Wicherkiewicz's case, but it must be considered as doubtful if this mould was really present, as it has never been described as pathogenic. No particulars were given concerning its morphology and cultures, and experiments on animals were not carried out.

From a white, prominent, partly delimited corneal infiltrate Baquis cultivated a peculiar *Hyphomycete*, whose identification was not pos-

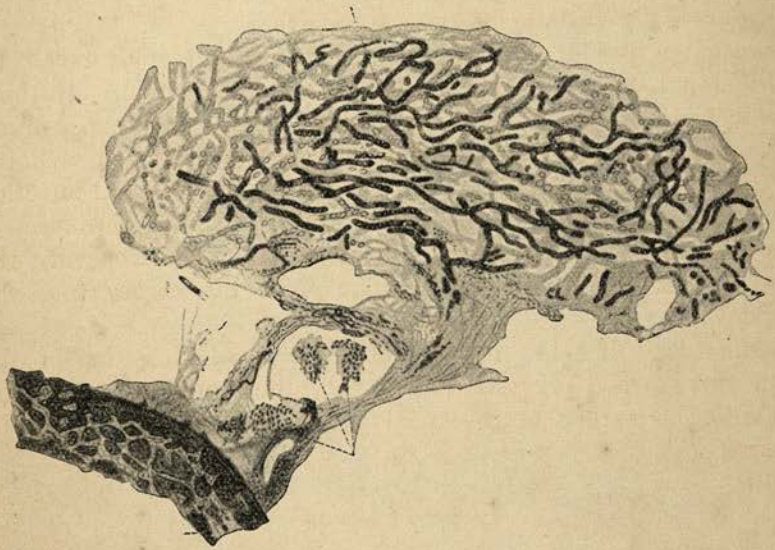

FIG. 70.—UHTHOFF AND AXENFELD, KERATOMYCOSIS ASPERGILLINA.
Vegetable foreign body with mycelium.

sible, as no spore formation was obtained (*Oospora ascoform ? Verticillium rubrum ?*).

Halbertsma also found that the *Aspergillus flavescens* was pathogenic for the cornea of the rabbit. *Aspergillus niger*, *A. ficuum*, *A. wentii*, and to a very slight extent the *A. candidus*, have been described as having a moderate degree of pathogenicity for the cornea of the rabbit, and to a certain extent also for the vitreous and the choroid. *A. glaucus*, *ostianus*, *minimus*, *clavatus*, *varians*, and *novus*, on the other hand, were found to be quite inactive. Buchanan states that many strains of *Aspergillus* and *Penicillium* are capable of pathogenic activity.

The relative rarity of keratomycosis, in proportion to the frequency

of the *Aspergillus*, is explained by the fact that it will only develop in the cornea when it is directly planted into its tissue by a foreign body, or is rubbed into it; otherwise it can only produce a corneal lesion with difficulty.

Best[1] records an interesting case of this variety in both eyes of a young blackbird. In the vitreous, the retina, the choroid, the anterior chamber, and the bone of the sclera, there was a dense felt-work of a mould. No cultures were available. Best considered that an injury, perhaps by pecking, was the cause. He recalled the fact that a general experimental infection of the blood with the spores of *Aspergillus* will readily cause a metastatic infection of the eye.

In man, too, similar infections of the vitreous by moulds have been described by Leber and Nobbe, Römer, and Kampherstein.[2] In these cases there was a necrosis in the immediate vicinity of the mycelium, and around that a suppuration. Leber and Nobbe, as well as Rollet and Aurand, have produced the same result by experimental infection of the vitreous. In the vitreous no reproductive organs were formed. In a phthisical eye Schirmer has demonstrated microscopically the presence of a mould infection passing from the cornea into the interior.

Koellner, in Michel's clinic, described a mould infection of the sclera with partial necrosis. Here, too, there was a sequestrum formed. The nature of the mould could not be determined by cultures.

LITERATURE.

The literature up to, and including, 1903 is given by Kayser and by Johnson in the K. M. f. A., 1903, XLI, I, p. 50, and XLI, II, p. 206.

Baquis, Una nuova forma di cheratomicosi. Annali di Ottalmol., 1905, XXXIV, p. 945.

Buchanan, Mycosis of the eyeball. Glasgow Med. Journ., December, 1905.

Kampherstein, K. M. f. A., 1903, XLI, I, S. 151 (here is the literature of mould infections of the vitreous).

Koellner, Schimmelpilzinfektion der Sklera. Z. f. A., 1906, XLI, S. 441.

Martin, A. f. A., 1904, L, S. 177.

Osterroth, Berl. klin. Woch., 1905, Nr. 7.

Rollet et Aurand, Experiment. Aspergilluskeratitiden. Revue générale d'ophth., July, 1906 (K. M. f. A., 1905, I, S. 774), and Rev. génér., 1907, S. 1.

Rosenstein, Ein schimmliges Geschwür der Lidhaut. Zentralbl. f. A., January, 1901.

Zade, A. f. O., 1907, LXV, p. 41, etc.

[1] *Deutsche Med. Woch.*, 1905, S. 1821.

[2] *Aspergillus fumigatus* occurred in Leber-Nobbe and Römer's cases; in Kampherstein's case the organism was doubtful.

Under the name of '**botryomycosis**' Bargerton described a tumour-like vascular growth in the cornea. It had a broad base and a nodular surface, and developed after an injury to the cornea. Microscopically it consisted of vascular granulation tissue. Dor and Bargerton considered the changes to be identical with the botryomycosis of the skin described in man (which affects the face and the hands, two cases being recorded in the eyebrows). In these cases a fleshy fungoid granulation tissue tumour formed a few weeks after an injury (like the growth in horses after castration); on removal it rapidly healed, and did not recur. The condition was considered by Poncet and Dor not to be due to the *Botryococcus equi*, but to a special *Botryococcus*,[1] an organism which resembled the *Staphylococcus pyogenes aureus* in almost every point, and by many is considered to be identical with it. The chief difference, according to Poncet and Dor, is that their coccus, unlike the *Staphylococcus*, does not form pus, but causes an exudation of lymphocytes. The bouillon culture remains clear (in contrast to the *Staphylococcus*); an orange-yellow mass forms at the bottom. On solid media a thick orange-yellow and slightly wrinkled slime forms, which when examined shows Gram-positive cocci, resembling a typical *Sarcinæ*. In the later stages of botryomycosis of the skin hyaline bodies—'grains muriformes'—should form. (In the granulation tissue in the cornea neither such granules nor the *Botryococci* have been demonstrated. There is no proof that these cases were anything different from what has been described in the literature as 'granulomata.')

Dor and Bargerton consider their case as identical with the one described by Schirmer and Reishaus (*Beitr. Zeit.*, August 31, 1899) as a 'fibroma of the cornea,' in which these authors found appearances which they, with Busse, considered to be saccharomyces Hefæ.

Further investigation is necessary to determine the pathogenesis of these and other corneal growths.

The literature is found in a paper by J. Bargerton, 'Un Cas de Botryomycose de la Cornee,' *Thèse de Lyon*, 1905, and Ten Sietoff, *Weekblad*, 1899.

A rare condition is reported by Lundsgaard (*K. M. f. A.*, 1900, xxxviii., p. 13), Stower (Inter. Med. Congr., Moscow, 1897, vi., p. 29, and *A. f. O.*, 1898, xlviii., p. 178), G. F. Keiper and Severance Burrage (Amer. Med. Ass., 1907, Atlantic City, Ophth. Sec., p. 87), as due to Hefæ.

[1] Identical with the *Micrococcus asciformis* (Johne).

Lundsgaard's case was one of atypical hypopyon-keratitis of moderate severity; the others were severe non-purulent ulcers. Lundsgaard and Stower found *Hefa rosa* in pure culture. The American authors did not succeed in an exact identification, as their organism was mixed with *Sarcinæ*, bacilli, and *Diplobacilli*.

This *Hefa* (Lundsgaard) at first grew at brood temperature, and, just as in Stower's experiments, produced nodules in the iris, from which weeks later the *Hefa* could again be grown. In the vitreous a white membrane was formed. In the cornea of a rabbit a benign rapidly healing inflammation occurred without a hypopyon. After continued cultivation the optimum temperature sank, and in this particular the strain which Lundsgaard grew took on the characteristics of the common non-pathogenic *Hefa rosa*.

These findings remain isolated,[1] so that there can be no great importance ascribed to the *Hefæ* in the etiology of corneal inflammations. The authors quoted consider that *Hefæ* were very probably the cause of the condition present in their cases.

Klein has obtained a nodular inflammation of the conjunctiva and iris through endogenous channels; and Stock carried out in my laboratory a full experimental and microscopic research into the nature of these peculiar hæmatogenous inflammations (*cf.* Ophth. Congr. Heidel., 1907, and Ziegler's *Beiträge z. Path. Anat.*, 1908).

Zur Nedden's Bacillus of Marginal Ulceration.

(*Cf.* PLATE III., FIG. *IV.*)[2]

Superficial corneal ulcers, marginal in position, develop by the breaking down of infiltrates; these may be single, or multiple when they tend by their confluence to the formation of trough-shaped ulcers. In the floor of such marginal ulcers, and more rarely in centrally-placed processes, Zur Nedden[3] found a bacillus which differed from any known organism. From its frequent occurrence, and its pathogenicity for the cornea of rabbits, he rightly considered it to be the cause of these ulcers.

The bacillus has been found in the same hospital in a case of neuro-

[1] In the sections of a so-called fibroma of the cornea, stained with Busse's *Hefa*-stain, Schirmer found fuchsinophile granules which presented the appearance of *Hefæ* (*Beit. z. Aug.*, 1899, xxxi.). This peculiar finding is analogous to that in the chronic granulation tissue tumours which can be produced by the action of the pathogenic *Hefæ*.

[2] The drawing is from a direct preparation from an ulcer; the preparation was sent me by Dr. Zur Nedden.

[3] *A. f. O.* 1904, Bd. lix., S. 360; also *K. M. f. A.*, 1906, xliv., Bd. i., S. 479.

paralytic keratitis,[1] and in London by Macnab.[2] A clinical point of great interest is that the bacillus has only been found in cases of inflammation of the cornea. In such cases they can be found in the

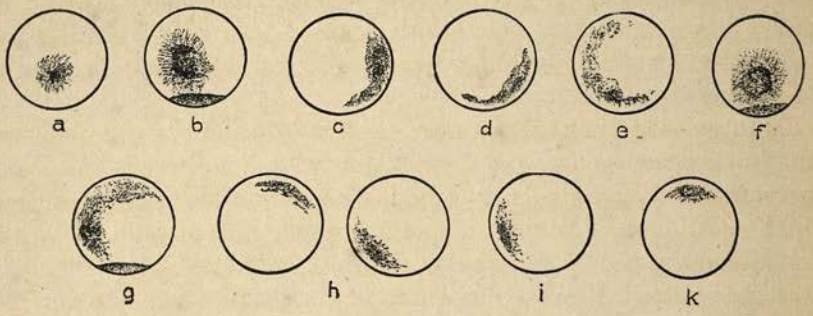

FIG. 71.—CLINICAL SKETCHES OF CASES OF ZUR NEDDEN'S MARGINAL ULCERATION (FROM ZUR NEDDEN).

conjunctival sac, from whence they have passed into the cornea. In a pure conjunctivitis they have not yet been found.

The clinical appearance is so far typical in that the Zur Nedden's bacillus alone has been found in any quantity in these conditions, provided that they are not incidental in the progress of other conjunctival infections (Koch-Weeks, diplobacillary, pneumococcal, or staphylococcal).

FIG. 72.—ZUR NEDDEN'S BACILLUS: TWENTY-FOUR HOUR GLYCERINE AGAR CULTURE. × 1,000.

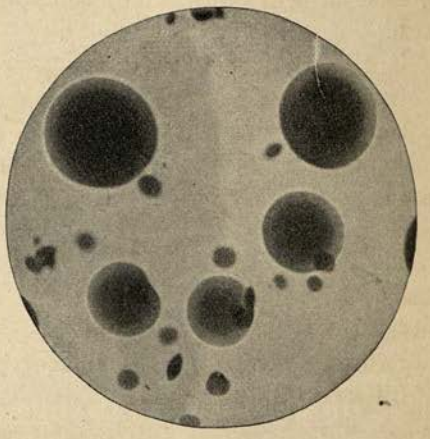

FIG. 73.—ZUR NEDDEN'S BACILLUS: AGAR PLATE CULTURE.
Large superficial and small deep colonies.

[1] Haupt, Inaug. Dissert., Bonn, 1902. Here are also given the full bacterial findings in this affection.
[2] 'Ulceration of the Cornea,' London, 1907.

Morphology.—Rods, either straight or slightly curved, lying very often in pairs; individuals are 0·7 μ long, and 0·6 μ broad. Smaller individuals and filaments are rare. Their ends are rounded. Clearer areas (vacuoles) can be seen at their ends, and sometimes also at their centres, when they are faintly stained. In many features the bacilli resemble xerose bacilli. Gram negative. No chain or capsule formation.

Cultures.—The colonies on agar are 2 to 7 millimetres in diameter after twenty-four hours, and by transmitted light appear bluish and translucent; they are slightly raised, with round and sharp margins. They tend to run together, and form a thick mucous slime. When the medium is poured out in Petri dishes or plates, small round or whetstone-shaped colonies develop in the substance; on the surface, however, they are large, round, and have a small dark central area. In transmitted light they are concentrically marked. In the deep layers of the agar they do not grow at all; they are obligate aerobes.

Colonies on gelatine plates are transparent, bluish, and homogeneous. In gelatine stab culture growth takes place only in the upper part, with the formation of a flat nailhead.

In sugar-agar there is no formation of gas, but the medium becomes acid.

Cow's milk is coagulated.

In bouillon slight growth, without indol formation.

On potatoes a thick, yellowish-brown growth.

On human blood-serum or Löffler's serum a thick greyish-white scum.

No motility.

The temperature optimum is that of the body; still, there is a scanty growth at 10° and 40° C. After three-quarters of an hour at 55° C. the bacillus is killed.

Resistance against dryness is very slight.

Differential Diagnosis.—On account of the characteristics given above, Zur Nedden rightly differentiated his bacillus from those of the *Coli* group, the *Bacillus typhosus*, the *Bacillus dysenteriæ*, the aerogenous group, and rightly also from the other bacilli found in the eye. In their cultures and morphology the *Diplobacilli* are quite different. The Zur Nedden bacilli may lie in pairs here and there, as, indeed, may be the case in any bacillus. The bacilli are readily seen in smear preparations from the central, rarer ulcers, which resemble ulcera serpentia, but without their tendency to spread out on the surface. The drawing on Plate III. is made from such a case. In

marginal infiltrates and ulcers, on the other hand, the bacilli are scanty, so that in the smear preparation single examples are only seen with difficulty. In the bacteriological examination of marginal ulcers cultures are essential if the Zur Nedden bacillus is to be sought for.

Prolonged culture has not succeeded in making the bacillus approximate any further to any other bacteria. The statement by Lehmann and Neumann that the bacillus belongs to the group of Friedländer's bacillus cannot be confirmed.

Phlyctenules commonly occur at the limbus. There is no true conjunctivitis. Zur Nedden therefore considers that the infiltrates and ulcers were primary corneal affections, and that they were not catarrhal; they were also almost always unilateral. Any irritation of the conjunctiva was secondary. In the secretion of such cases the bacillus could be demonstrated by cultures.

The ulcers did not usually progress; hypopyon was rare, but relapses were not uncommon. The disease was more common in the winter.

Zur Nedden found the bacilli along with *Pneumococci* in a case of ulcus serpens, and also in a case of neuroparalytic keratitis.

He never found it in any other circumstances, in spite of numerous examinations of conjunctival and lacrymal affections.

Inoculations. — If an agar culture be diluted with water and a trace of the fluid injected into the cornea of a rabbit, a keratitis of varying severity is produced. In many cases it takes on the form of a hypopyon-keratitis, and may lead to a perforation;[1] in others it remains as a benign infiltrate. Cultures which are older, and have been repeatedly subcultivated, have a much weaker action. The bacilli remain for a long time in such corneal infiltrates, and can be again grown in a pure condition. When, however, they are injected into the interior of the eye, the vitreous, or anterior chamber, they cause a transient reaction of varying severity in the connective tissues, and within twenty-four hours they die out. This result is due to the need of oxygen. Inoculations on other animals, and in other parts of the body, produce no reaction. The Zur Nedden bacillus is therefore a bacillus which is only pathogenic in the eye, and one too, which has a stronger action in the cornea than in the vitreous.

It is only in exceptional cases that an injury has preceded the ulceration; the bacillus must therefore have the power of attacking the uninjured cornea from the conjunctiva. This it does in the marginal

[1] A purulent destruction of the cornea, due to a pure infection with this bacillus, has never been observed in man. The formation of a hypopyon even is rare.

zone and in old people, as in them the superficial layers of the cornea are especially liable to changes (arcus senilis).

Up to the present Zur Nedden (Bonn) alone has given detailed accounts of these bacilli. In four years he observed sixty-five cases, and concluded that the disease is common in the Rhine Valley. On account of the difficulty in the demonstration of the bacillus, it is possible that cases occur in other places, but have not been recognized. Macnab[1] has found the bacillus in three cases in London. Paul records having found it in a few cases in Breslau.

In his 'Maladies de la Cornée' Morax gives a figure of the bacilli from a case of keratitis. In spite of specially directing attention to the point, we have never found this organism in Freiburg, even in cases whose clinical appearances resembled those of Zur Nedden's cases.

We have no information as to the occurrence of the bacillus in Nature, or the source of the infection of the eye. Zur Nedden is of opinion that it does not cause a keratitis in every case in which it occurs on the conjunctiva, and that with careful searching it will be found on the normal conjunctiva. He is very probably correct.

As to **treatment,** the common conservative procedure for keratitis is usually successful; even in the most severe cases the galvano-cautery was seldom necessary.

Herbert's Intra-Epithelial Capsulated Bacilli in Keratitis Punctata Superficialis.

Some time ago the director of the eye hospital in Bombay, Lt.-Col. Herbert, I.M.S., sent me several preparations for an opinion. They contained quite peculiar bacteria, which had been only once briefly described in the *Ophthalmic Review*, 1901, p. 339. The case was one of keratitis punctata superficialis, and closely resembled the affection described in the years 1893-1894 by Fuchs, Reuss, and Nuel. There was only the slight difference that the initial irritation of the conjunctiva in Herbert's cases was less obvious, and that in India the disease almost always remained unilateral, and healed in the comparatively short space of three weeks. The disease occurred in an epidemic form, although the process of infection could not be demonstrated.

When Herbert scraped the slightly uneven epithelium from the punctate spots, he found in the epithelium large numbers of peculiar bacilli, which were only stained with great difficulty, in the ordinary

[1] Macnab, 'Ulceration of the Cornea,' London, 1907.

aniline stains were merely hinted at, and were only demonstrable on account of their well-developed capsules.

With the ordinary Gram's method they practically did not stain, and it was only in overstained Gram preparations that they were occasionally visible. Fig. 74 is drawn from such a preparation. The bacilli lie quite irregularly in the protoplasm; they are rather thick, about 3 μ in length, and 1·5 μ in breadth; there are no long filaments. The form of the bacilli reminds us of the group of Friedländer's bacillus (*B. mucosus capsulatus*), to which the ozæna bacillus and the rhinoscleroma bacillus belong; they differ from this group, however, in their staining and their cultures. The etiological significance of these bacilli for this keratitis punctata superficialis is very probable, on account of their large numbers in the epithelium and the regularity of their occurrence in cases where only a few cells filled with bacilli could be found, even though cultures with the most varied media and methods have never yet been successful. It was only to be expected, considering the superficial situation of the lesion, that the ordinary saprophytes (xerose bacilli and *Staphylococci*) would be also found along with these capsulated bacilli. The bacilli can very readily be overlooked on account of their difficulty of staining. On this account, therefore, the fact that Nuel[1] did not describe any such bacilli in his sections cannot be taken as certain proof of their absence. As the anatomical cause of the opacity, Nuel described peculiar networks of threads and spirals formed of hyaline fibrin, which were grouped close together under Descemet's membrane, so as to form corneal granules. It is quite possible that these formations were produced by the intra-epithelial bacilli.[2] Such is the opinion of Wehrli,[3] who microscopically demonstrated small inflammatory nodules. I do not consider it certain that the Indian keratitis can be

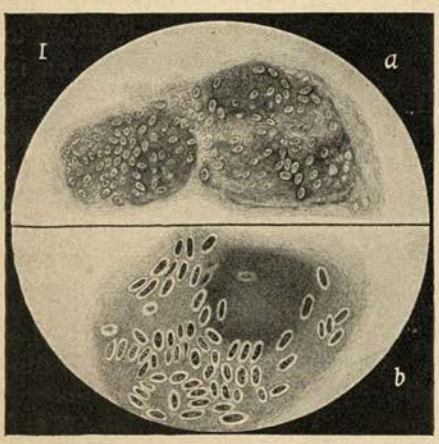

FIG. 74.—HERBERT'S INTRA-EPITHELIAL BACILLI FROM INDIAN KERATITIS PUNCTATA SUPERFICIALIS. GRAM OVERSTAINED. *b* × 1,200.

[1] *Arch. d'Ophth.*, 1894, xvi., p. 145; and 1896, xvi., p. 725.
[2] *Ann. d'Ocul.*, 1897, 117.
[3] *K. M. f. A.*, 1906, Bd. xlvi., 2, p. 224.

identified with the European, but Herbert's results should stimulate similar search for intra-epithelial bacilli in the early stages of the affection in Europe.

Nuel[1] has since pronounced the hyaline spirals to be derived from bacilli, and emphasizes their similarity to cilia (twisted cast-off flagellæ of bacteria). This contention cannot be accepted. In another case of punctiform infiltrations due to ammonia, he found granular masses which corresponded to the opacity; these he considered to be masses of cocci. The bacterial nature of these appearances is not certain, and Valude[2] is not justified in considering that the punctate infiltrations which may develop and rapidly heal during a streptococcal conjunctivitis are masses of *Streptococci.*

The **ulcus corneæ rodens** (Mooren), though resembling an infectious process, has till now not shown any bacteria which signify. The bacillus which Andrade[3] found in two cases (once with the *Staph. pyog. aureus*) is reminiscent of *Subtilis,* and has not been found by any other observer. It was a spore-forming, motile, Gram-positive bacillus, which liquefied blood-serum and gelatine, formed a thick white scum on agar, a diffuse cloudiness in bouillon; it caused a transient infiltration in the cornea of the rabbit, passing off without suppuration.

De Berardinis (*Ann. di Ottal.*, 1906, xxxv., p. 835) cultivated a pyogenic tetragenus, which, however, could only have been a secondary infection, as it was not found in other cases (*cf.* Hilleman's *A. f. A.*, 1896), where the ordinary pus-forming organisms were present.

Keiper, D. G. Levy, F. R. Spencer (Amer. Jour. of Ophth., 1896, xxiii., p. 176) have cultivated an organism which resembled the Zur Nedden bacillus from cases of **keratitis dendritica.** They found short bacilli, mostly in pairs, non-motile, Gram-negative, growing on all media as greyish-white, round colonies, and not liquefying either gelatine or blood-serum. In gelatine stab culture they formed a flat-headed nail growth. There was no gas formation, and no spores developed; they were not pathogenic for the rabbit's cornea.

That this bacillus is the cause of keratitis dendritica is not proved. In other cases examined by Uhthoff and Axenfeld the result was negative or indifferent (xerosis); in one case, where a dendritic keratitis passed on to a hypopyon-keratitis, large numbers of *aureus* were found in the cornea. This was certainly a secondary pyogenic infection.

We have no information certainly pointing to a micro-parasitic

[1] See notes [1] and [2] on preceding page.
[2] *A. f. O.*, 1900, xlix., p. 455. The whole literature is there given; also see Haupt, Inaug. Dissert., Bonn, 1902.
[3] *Ann. di Ottal.*, 1900, xxix., p. 654. The literature is there given.

etiology of the **herpetic affection of the cornea** to which keratitis dendritica belongs. The similarity of these conditions to the inoculation keratitis in rabbits, which is produced by the action of the virus of variola or vaccinia, should be noted. It would be of interest to compare the findings in the epithelium in the two conditions.

Opinions have varied very much concerning the rôle of micro-organisms in that much-discussed condition, **neuroparalytic keratitis.** In opposition to the pure neurotrophic, and the traumatic or desiccation theory, Eberth and Balogh emphasize the point that a trigeminal lesion only leads to a depreciation of the epithelium, which, again, allows of the entrance of the organisms, the bacteria being the true cause of the inflammation. According to E. von Hippel, bacteria are always at work in the purulent cases, but in the others they are not regularly found. Ollendorf,[1] at the instigation of Leber, has gone into the matter again, and came to the conclusion that a keratitis—and that, too, a purulent one—can occur in rabbits without the presence of any organisms, and due entirely to desiccation. He does not, however, deny that in man desiccation alone is but rarely the cause, and that in the human eye micro-organisms play a part. Bacteriological examinations above suspicion of fallacy, of cases in man, are very few, and their results vary. Treitel and E. von Hippel found cocci, and Zur Nedden found his own bacillus.

Ollendorf was quite unable to convince himself that an inoculation keratitis, in cases with lesions of the trigeminal, had any different course than the same keratitis in a normal eye. This is opposed to the views of Krause, Angelucci, Spallita, according to whom the cornea has a lowered resistance in the latter cases. Spallita states that in this respect the sympathetic and the trigeminal are antagonistic; for extirpation of the sympathetic in the neck raises the resistance, previously reduced by section of the trigeminal, to the normal. This finding requires control. Seydl, on the other hand, has observed neuroparalytic keratitis in cases of sympathetic paralysis. Davis and Hall have lately described bacilli resembling *B. xerosis*, which they considered to be of etiological importance in neuroparalytic keratitis.[2]

It is well known that the corneal epithelium of various animals (rabbits and guinea-pigs) is a most suitable medium for the inoculation and the growth of the virus of **variola** and **vaccinia** (not for that of varicella).[3]

[1] *A. f. O.*, 1900, xlix., p. 445. *Cf.* here the whole literature; also Haupt, Inaug. Dissert., Bonn, 1902.

[2] *British Medical Journal*, January, 1908.

[3] *Cf.* Salmon, *Soc. de Biol.*, February 12, 1905.

The corneal epithelium of the rabbit is considered to be the most suitable site for the inoculation of the 'variola protozoa,' those much-discussed cell-inclusions,[1] which Pfeiffer and Guarneri, and more recently Wasielowski,[2] Jürgens,[3] and others, have considered to be parasitic (*Cytorrhyctes*, Guarneri). By continued subinoculation Pfeiffer and Wasielowski were able to demonstrate these cell-inclusions to the forty-eighth generation, and therefore they considered that their etiological significance was probable. The clinical appearance on inoculation resembled that of many forms of herpes and keratitis disciformis, also keratitis dendritica. The cell-inclusions pass from the epithelium into the parenchyma.

Inoculations of the epithelium with vaccine, after the method of Schirmer,[4] produce in the guinea-pig an appearance which resembles that of the **keratitis disciformis** of Fuchs. Just as in the case of variola, the infected epithelium can be further inoculated on to the cornea of other animals. In connexion with vaccinal affections in the human eye, Schirmer observed the occurrence of similar conditions. Zur Nedden[5] has lately cultivated an aerobic *Streptothrix* from a keratitis disciformis, which passed on to suppuration. This *Streptothrix*, when inoculated on rabbits, caused an ulcerative keratitis (*cf.* De Berardini's inoculations, p. 313). It was Gram-positive, and formed filaments: the organism grew aerobically on the usual media as soft, flat, granular colonies, which soon died out. When inoculated on the cornea of a rabbit, they caused a hypopyon-keratitis of moderate severity. The probability of the infectious nature of this peculiar form of reaction following on small injuries, and designated as 'abscessus siccus' since the time of Arlt, is therefore increased.

SERUM TREATMENT OF CORNEAL INFECTIONS, ESPECIALLY PNEUMOCOCCAL INFECTIONS.

1. Serum Treatment in the Corneal Complications of Diphtheria[6] (Diphtheria Bacilli, Streptococci).

Although a conjunctivitis caused by Löffler's bacillus is influenced very beneficially by the use of Behring's antitoxic serum, the infiltrations of the cornea which are present at the time of the serum injections

[1] See the critical review by Paschen, *Münch. Med. Woch.*, 1906, p. 2391.
[2] *Zeit. f. Hyg. u. Inf.*, 38, p. 312; also Kolle and Hetsch, 'K. and W. Handbuch,' 1903, Bd. iii., p. 896.
[3] *Charité-Ann.*, 1905, xxix., p. 127.
[4] *A. f. O.*, 1904, lix., i., p. 133. Protozoa (cell-inclusions) are claimed by Pfeiffer and Clarke as the cause of the reaction in vaccinia.
[5] *K. M. f. A.*, February, 1907, xlv., Bd. i.
[6] *Cf.* the corresponding conjunctivitis.

do not disappear so rapidly. This agrees with the statements first made by Coppez, and so often repeated in the literature, that the curative action in corneal complications is very uncertain. Even in spite of the healing of the conjunctival lesions, the cornea can go steadily on to destruction; this is due to the fact that the inflammation and ulceration are not due to the diphtheria bacilli, but to secondary infections with pyogenic organisms. These are not directly overcome by the action of the serum, but only indirectly influenced by it to this extent, that the subsidence of the conjunctival diphtheria favourably influences the nutrition of the cornea, and the neutralizing of the toxin in the conjunctival sac prevents a further toxic action on the corneal tissues.

In general it cannot be stated that destruction of the cornea occurs from the action of the diphtheria bacillus. Certainly by experiment on animals we may succeed in producing a severe keratitis by the introduction of a large number of very virulent bacilli into a central pocket in the cornea. No condition similar to this has ever been observed clinically in diphtheria in man. Coppez' experiments, which were confirmed by Morax and Elmassian, showed that repeated instillations of diphtheria toxin into the conjunctival sac, without any action of the pyogenic organisms, can in the end cause a necrosis of the cornea, especially when there is a defect of the epithelium; these results, however, cannot be applied to man. It has recently been disputed by Dugast[1] that this is even the case in animals; it is doubtful if he is right, as it is very possible that Coppez may have worked with a more potent toxin than Dugast, who gives no details on this point. Coppez' results are confirmed by Römer,[2] who injected minute quantities of diphtheria toxin into the tissues of the cornea, and thus obtained necrosis in non-immunized animals, while immunized ones suffered no damage.

For these reasons we may, when suppuration has already commenced, give a streptococcal serum, such as the polyvalent serum of Menzer (Merck[3]), as well as the diphtheria antitoxin. But even when the infection of the cornea is due to the *Streptococcus*, it is questionable whether such a procedure can save the cornea. In conjunctival streptococcal diphtheria I have succeeded in curing the conjunctiva and improving the general condition, and still the cornea went on to destruction. Only an early exhibition of the streptococcal serum will benefit, and even then not with the certainty of the antitoxic action of the diphtheria serum against the infection with the diphtheria

[1] *Thèse de Paris*, 1905. [2] *A. f. O.*, 1901, liv., p. 164.

[3] This is obtained from as many fresh strains as possible of the organism obtained from man. The Marmorek serum, which is so much used in eye diseases in France, and is specially recommended by Boucheron, is made from cultures which are kept up to their virulence by passage through animals. The antistreptococcal sera of Höchst, of Moser, and of Ahronson, combine these two methods in varying degrees. Tavel's serum is a polyvalent horse serum, containing many strains which are pathogenic for man (from T. D. Kredel, Berlin, Gerichtstrasse 12, 13). All these sera are accompanied by exact directions as to their manner of use.

bacilli; the conditions are complicated in a way similar to those interfering with the use of pneumococcal serum. Perhaps in 'aggressin immunity' we may find assistance.

Behring's diphtheria serum is well known to be an antitoxic serum of the type which does not kill the bacteria themselves, but neutralizes their products of metabolism—their toxins—by some chemical process, rendering them innocuous.

That this is so has often been shown in ophthalmology. Diphtheria bacilli can be found on the conjunctiva of persons who have suffered from conjunctival diphtheria, and have been cured by the action of the serum, just as is so often the case in the throat. The bactericidal serum of Wassermann[1] may perhaps accelerate their disappearance.

The action of the antitoxic sera is comparatively certain, because, in the first place, the serum can be consistently and with certainty standardized by Erlich's method; and secondly, the combination of the toxin with the antitoxin occurs without any activity of the body, just as it would occur *in vitro*. An active serum of this variety also counteracts the toxins of all diphtheria, whatever their origin.

2. Serum Treatment for Pneumococcal Infections. (Ulcus Corneæ Serpens.)

The extraordinarily convincing action of the antitoxic diphtheria serum in animals and its applicability to man assured its immediate use in ophthalmology.

The conditions are very different in that much more common and, from a practical point of view, much more important infection with the *Pneumococcus*. Although experimental immunization and treatment with serum had for some time been attempted with relation to man, it was not till the work of Römer appeared that any notice was taken of them in ophthalmology. They were not incorporated in any form of treatment, because the experiments had produced very little convincing result, and also because we were in possession of a very good method of treatment for most of these dangerous cases—that of the galvano-caustic and the Saemisch section. On account of the immense importance of this infection in ophthalmology, I will shortly review the question of pneumococcal immunity.[2]

[1] *Cf.* Vogelsberger, 'Über die Anwendung eines neuen Serums bei Diphtherie,' Dissertation, Berlin, 1905.

[2] The full literature is to be found in the article by Weichselbaum in 'Kolle und Wassermann Handbuch,' 1903, Bd. v.; also in Marikowsky, *Zent. f. Bakt.*, 1904, xxxiv., Ref. S. 481, and Römer (*loc. cit.*)

It must be admitted that the natural susceptibility towards infection by the *Pneumococcus* varies, not only in the sense that strains exist which are pathogenic for animals, but still have no action on man,[1] and vice versa, but also in the sense of a variation in the susceptibility of man to infection. The variation in susceptibility to the secretion of a pneumococcal conjunctivitis is evidence of this, and has already been discussed.

It is quite certain that the personal factor plays an important part in the resistance of the cornea to pneumococcal infection—*i.e.*, the ulcus serpens. As an illustration of this, the following case from my own experience will serve: In the cornea of a man fifty years of age, having a dacryocystitis with *Pneumococci* in the secretion, a subcentral ulcus serpens had developed after a superficial injury. The ulcer would have been described clinically as unusually benign; it increased very slowly, and, untreated, in three weeks had only reached the extent of 4 millimetres wide and 2 millimetres high, remaining quite superficial. The nasal margin was slightly infiltrated, and formed a thin yellowish-grey curved line; the rest of the ulcerated area was clear, and appeared covered with epithelium. The hypopyon was small. In spite of this, *Pneumococci* were taken from the margin of the ulcer in large numbers, and they were found to have a high virulence and rapidly killed susceptible animals when the original culture was used.

Such cases are rare, and can be called chronic ulcus serpens. We can presume that those *Pneumococci* which, immediately they were taken from the ulcer, showed a high virulence for animals, had also a considerable pathogenicity for man.[2] If this be true, then the relative mildness of the corneal process must be due to a peculiar want of susceptibility. At least this is one of the factors which, along with the virulence and number of the organisms and the nature of the injury, must be taken into account to explain the variations in the intensity of the clinical appearances of the ulcer.

As the *Pneumococci* were able to retain their power to produce the disease for such a long time, they must have had a pathogenicity for man. It is remarkable that the struggle between the cocci and the cornea was not settled sooner in one or the other way. It is obvious that susceptibility can vary in one and the same person.

The blood-serum of animals convalescent from a pneumococcal infection can protect against an artificial infection; a pneumococcal affection must therefore leave a certain degree of immunity.

In man the period of the immunity passes quickly by, and it is of very slight degree, as is shown by the recurrences. Such recurrences after comparatively short intervals are to be seen in pneumococcal conjunctivitis (Gifford), and occasionally after ulcus serpens. A pure local pneumococcal immunity of the eye either occurs to a very limited extent or not at all.

The meaning of the results obtained on the artificial immunization of animals is much more obvious.

Fränkel (the discoverer of the *Diplococcus lanceolatus*), Foa, Bordone and Uffreduzzi, demonstrated the immunity of animals, who have suffered from a pneumococcal infection. The experimental animals, in response to the first infection, formed protective substances by developing an active immunity.

The artificial production of immunity can be obtained in several ways: Foa,

[1] The brothers Klemperer have inoculated themselves with doses which were fatal for rabbits, without causing any damage. Römer and a doctor in the Wurtzburg clinic have also demonstrated the same on themselves.

[2] This probability can only be assumed when the virulence has been tested immediately after the material has been obtained, and the same is the case with regard to *Streptococci*. After long cultivation with interpolated passages through animals, a strongly pathogenic strain need not show a corresponding pathogenicity for man.

Bordone and Uffreduzzi, Kruse, Pansini, and others, used attenuated or dead cultures; Foa and Scarbia used bacterial extracts; Netter, Vassale, Montanaro, and Klemperer introduced pneumococcal exudations and affected organs; Emmerich and Wassermann introduced small quantities of very virulent cultures. Combinations of these methods have been used. Others (Klemperer, Bonome, etc.) injected filtrates of cultures or tissues, following Kitasato and Behring, who obtained, with such filtrates, practical degrees of immunity to diphtheria and tetanus. It was soon obvious that the conditions were quite different in the case of the *Pneumococcus*, and that this last method (with filtrates) would lead to no results of value, as the active substances lay in the bodies of the bacteria. The method, therefore, will not be discussed.

The results which the various observers obtained with the active method mentioned did not quite agree; the degree of the immunity, its time of entrance, and its duration, were influenced to a varying extent by variations in the virulence and the strains of the cocci.

Soon after the discovery of passive immunity in diphtheria, Emmerich and Fawitzky, Bunzel and Federn, Foa and Carbone, F. and G. Klemperer, commenced experiments in the year 1891 to passively immunize animals against *Pneumococci* by the use of the serum of other immunized animals. Emmerich used the serum of rabbits, so highly immunized by the intravenous injection of very diluted highly virulent *Pneumococci*, that they were able to withstand 25 to 30 c.cm. of a highly virulent bouillon culture. With the serum of these animals he obtained a certain amount of curative action on animals already infected.

Foa and Carbone made the first attempts at the treatment of pneumonia patients, and they attempted to immunize animals with the serum of a convalescent from pneumonia. They observed that an immunity against all the varieties of *Pneumococcus* could not be produced with the one strain.

G. and F. Klemperer report attempts at treatment with their serum.

This curative action of rabbit's serum for pneumococcal diseases in man was not confirmed by many observers, and, considering the variable course of these diseases, especially pneumonia, the apparently favourable results are not convincing. This method of treatment was, at any rate, unable to make further progress.

Washbourn, with others, utilized the power of a serum to make the *Pneumococci* in a tube sink to the bottom as a measure of its activity. He obtained better results by using the larger animals, especially horses, for the purpose of obtaining serum. Since then Mennes and Pane have used goats, cows, and donkeys. These animals were inoculated with very dilute, highly virulent *Pneumococci*. Pane especially obtained exceedingly high immunization in rabbits by the intravenous injection of donkey's serum.

During the nineties attempts were made on many sides to cure pneumonia by the injection of Pane's and other similarly prepared sera. Amounts from 10 to 150 c.cm. were used, and the exhibition of very large doses appeared useful. Many reports were favourable (Pane, Fanoni, de Renzi, Eyre and Washbourn, Janson, Pignatti, Goldsborough); others were less so (Canteiri, Spolverini, Sears, Hughes and Carter, Bautin, Pieraccini, Huber, Blumenthal). Snivelly collected from the literature 106 cases, and Goldsborough 395, some of which were treated with Pane's serum and some with the serum of pneumonia convalescents. The series only gave a mortality of 5 per cent. Both the authors express satisfaction with this result.

In spite of this, Weichselbaum came to the conclusion at the end of his critical monograph (1903) that, considering the variations in the course of a pneumonia, and the fact that it often heals spontaneously, the curative action attributed to the serum could only be demonstrated when a still larger number of cases was tested.

The varying results of the different authors might be due to differences in their methods, the unequal virulence of the strains used for immunizing purposes, and to the degree of immunity not being determined.

De Renzi has lately (1905) reviewed the results of the previous ten years' treatment of pneumonia with Pane's serum, and expresses his appreciation of it. Panichi similarly refers to the Tizzoni-Panichi serum, and testifies to its value. Therapeutical attempts have recently been made in pneumonia with the polyvalent serum of Römer (Knauth, *Deutsche Med. Woch.*, 1905, No. 12; Pässler, *Deutsches Archiv f. Klin. Med.*, 1905, Bd. lxxxii.; Lindenstein, *Munch. Med. Woch.*, 1905, p. 1874). The results are given by these authors as favourable, especially with regard to the subjective condition. It is interesting to note that Knauth and Pässler gave large doses up to 60 c.cm., which were quite harmless; while Lindenstein states that 10 c.cm. given early is quite sufficient. Jürgens (*Med. Klin.*, 1907, p. 273) reviews the question, and states that an authentic curative action in pneumonia has not yet been demonstrated. We must wait until a much larger material is available before coming to any conclusion.

The collected observations regarding ulcera serpentia are not applicable in every particular to pneumonia, nor are those of pneumonia to ulcus serpens.

The opinion we have quoted as held by Klemperer, that pneumococcal serum, like diphtheric, was antitoxic, and counteracted the pneumotoxin which collected in the blood, is erroneous; on the contrary, the material is one which attacks the bacteria themselves. (The substance, according to the work of Wassermann, is produced in the marrow, in the blood-serum and the thymus, to a much smaller degree in the spleen and the lymph-glands, and not at all in any other organ.) The toxic power of *Pneumococci* is due to *endotoxins*, which remain in the bodies of the bacteria, and therefore can only be affected by the action of bactericidal substances. All the 'bactericidal' sera—in the widest sense of the word—are considerably less efficient than the antitoxin.

Until recently the pneumococcal immune serum has been considered as a bactericidal one, in the sense that the antibodies (amboceptors) attached to the bacteria, with the assistance of the 'complements' (alexines) derived from the body of the man or animal, produced the destruction of the cocci. For such to occur it is necessary that the antibodies and the complements must suit each other. On account of the specific variation of different strains of *Pneumococci*, it is possible that the serum produced by one strain will be complemented by one species of animal, but not by another; and it is also possible that an amboceptor (Erlich) may have an affinity to one strain, but may not possess any for a *Pneumococcus* of another origin.

As, however, a bacteriolytic activity has not yet been proved for pneumococcal serum, either in the peritoneal cavity (analogous to the cholera experiments of Pfeiffer) or in a reagent glass with the addition of the complement, we must agree with Neufeld that no such bactericidal power as has been attributed to this immune serum exists. The assistance of the leucocytes generally is necessary; by phagocytosis they render harmless the bacteria previously altered by the serum. Neufeld called this action 'bacteriotropic,' as it brought about the conditions under which the leucocytes could attack the bacteria after the receptors of the bacterial toxin were satisfied by the antibodies.

Where a bacteriolysis from immune serum and complement was never obtained, immune serum, on the other hand, immediately caused an intense phagocytosis if leucocytes were present. These results tend in the direction of the well-known teaching of Metschnikoff, though his opinion that the leucocytes are directly stimulated to phagocytosis by the immune serum is not correct.

These observations regarding the 'bacteriotropic activity' of pneumococcal serum

agrees to a very great extent with the opsonic teachings of Wright. He defines the opsonic power of the serum as the power by which the phagocytosis of the bacteria is promoted.

Treatment by pneumococcal serum is made difficult by the fact that the various strains of *Pneumococci* show specific differences with regard to the antibodies which they produce.

Kindborg,[1] in a paper from Fränkel's Institute, by sufficiently diluting the immune sera which they had produced, showed that each individual strain of *Pneumococci* only formed an agglutinin for itself. The agglutinating serum obtained by one strain did not agglutinate the other strains.

This specific division of the individual strains of *Pneumococci* was of importance in the immunizing experiments of Kindborg. The immune serum which was obtained by the intravenous injection of large doses of dead cultures protected white mice only against that same strain. Against other strains it was ineffectual.

Kindborg therefore preferred to speak of 'the *Pneumococci*' rather than 'the *Pneumococcus*,' using the analogy of the *Streptococci*.

Scholtz[2] examined the mutual agglutinating power of various strains of *Pneumococci* from ulcera serpentia, and did not find so sharp a distinction between them; still, he did find some difference, and his records must be considered.

Römer has attempted to meet these individual variations of the various strains of *Pneumococci* by means of a polyvalent serum produced from as many strains as possible (just as is the case with Menzer's streptococcal serum). But the result has not been satisfactory in the majority of cases.

This last-mentioned difficulty, which Römer tried to obviate by means of his polyvalent serum, and which is so great a factor in the inconstancy of serum treatment, is alleged to be of less influence in the 'aggressin immunity' discovered by Bail.[3] Bail found that if the peritoneal exudate due to typhoid, when the bacilli had been removed by the centrifuge and filtration, were injected into another animal, it had the power of enormously increasing the susceptibility of the second animal to typhoid; a very much smaller dose of the bacilli was then fatal. He named this power which the exudate possessed 'aggressin.' If now such bacteria-free exudate be repeatedly injected, an 'anti-aggressin' is formed, causing much higher immunity against the bacilli than could be obtained by any of the other means of bactericidal immunizing. A relatively powerful passive immunity can be produced by injections of the serum of such an animal.

Hooke[4] applied this method to the *Pneumococcus*.

Römer[5] attempted to apply it to ulcus serpens. It would have been especially important could we have confirmed his hypothesis that the aggressin immunity produced by one strain was capable of protecting against infection with strains of varied origin, and from different ulcera serpentia. Strains of high virulence (for the serum animal), and not merely those pathogenic for man, could then be used in the production of the serum. The methods of treatment by 'polyvalent serum' heretofore used have only shown partial success, but by this (aggressin) method a better result seems to be more simply obtainable. These expectations have not been realized.

Wassermann has shown that an analogous action can be produced by living bacteria, to which distilled water has been added (autolysis), or which have been treated with other extracts.

[1] *Zeit. f. Hyg. u. Infekt.*, 1905, iii., p. 97.
[2] *A. f. A.*, 1906, lvi., p. 84.
[3] *Zeit. f. Hyg. u. Infekt.*, 1904.
[4] *Wien. Klin. Woch.*, April, 1905, No. 14, 'Über Diplokokkenaggressine.'
[5] Heidel. Cong., 1905, rev. *K. M. f. A.*, September, xliii., Bd. ii.

For the production of aggressin, it is not essential, as Bail thought, to have an exudation that is produced by living tissues; it can be obtained directly from the bacteria themselves.[1] It therefore seems very doubtful whether in this aggressin treatment we obtain any results essentially different from those obtained by the 'active' method of immunizing; probably the preliminary solution of the bacilli frees the aggressive substance or endotoxin before the injection, so that the body will react immediately and perhaps more strongly, while in the other case after the injection the first solution of the bacteria must occur in the body. Accepting Wassermann's point of view, and provided that an aggressin method for *Pneumococci* of practical utility can be evolved, we may anticipate that the action may be perhaps gradually increased, though it does not present any features different from the methods already in use.

Amongst the pneumococcal infections of the eye with which we have to deal, we can leave pneumococcal conjunctivitis out of the question of serum treatment, as it is a benign affection which generally heals by crisis, and is amenable to the usual treatment for conjunctivitis. At the very most it can only come into question in the exceptionally severe cases.

The same is true for the very common pneumococcal dacryocystitis. In cases where it cannot be cured by probing, etc.—that is, in old and severe cases, especially in the working classes, where for social reasons such a treatment cannot be carried out—the sac can be extirpated, and thus the disease radically removed.

The rarer pneumococcal infections of the orbit and metastatic pneumococcal ophthalmia are only very rarely available for serum treatment.

As we have already said, pneumococcal infections of the cornea are of the greatest importance.

Seeing that, as Römer has shown in his work,[2] the ulcus serpens itself, on account of the feeble absorptive powers of the cornea, does not form any appreciable quantity of specific antibodies in the blood, the body requires a therapeutical increase of its resisting power. To achieve this, Römer first recommended a passive immunization with polyvalent serum. He was able to prove that such was not without action even in the avascular cornea, and demonstrated that an infection of the cornea of an immunized rabbit with a small dose of virulent *Pneumococci* had no result, though in a control animal it produced a suppuration. An application of the serum six to ten hours after the corneal infection had a definite action, the process being rendered milder.

[1] This is similar in many respects to the attempts with bacterial extracts referred to previously. Pneumococcal extracts have been previously utilized which, besides living bacteria, also contain their aggressins. The results were unconvincing.

[2] It should be noted that Gatti (*Ann. di Ottal.*, 1902, xxxi., p. 3) worked in the same direction, but obtained negative results. He stated that in animals the eye took no part in the pneumococcal immunity. This was so far correct in that the aqueous contained practically no bactericidal substances; but in the cornea, with which Gatti did not experiment, the conditions were different.

The participation of the cornea in a general bacterial immunity, as has been demonstrated by Römer for *Pneumococci*,[1] and by Löffler for the organism of mouse septicæmia, is the basis of all further attempts to influence this corneal disease by means of a serum treatment. In the case of other bacteria, however, this statement is not so applicable.

On the basis of his preliminary experiments Römer began the treatment of ulcus serpens. He considers prophylactic action as most important; this can be obtained in cases of injury where the conjunctiva is septic, a dacryocystitis present, or in the early stages of a traumatic corneal infiltrate. He placed the curative action in fully developed and widespread ulceration in a very secondary position to this preventive action.

There is nothing to be said against the surgeon injecting prophylactic serum in cases of recent corneal wounds with septic surroundings.

It is absolutely necessary that the cases are not considered as protected and saved; the patient should be seen daily, and on any advance of the inflammation immediately admitted to hospital.

It is quite different when the patient comes with an infective inflammation. In such cases the exhibition of an active serum is to be recommended, but every such patient should at once be sent to an oculist, for the following reasons:

1. The present serum is shown by the clinical records given later to be unreliable in advanced cases. This applies in a marked degree to the passive method of application; perhaps not so much so to the simultaneous method, but even then its action is uncertain. Valuable time may thus be lost. Whether better results can be obtained by the 'aggressin method' remains to be seen.

2. Although the great majority of cases of hypopyon-keratitis are due to the *Pneumococcus*, still there are some which are due to other infections, especially *Diplobacilli*.

Römer has also demonstrated mixed infections, which in my experience are rare. For such cases the serum treatment is naturally inefficient.[2]

On the other side, it must be admitted that many surgeons, from a want of experience, fail in obtaining results when they take material for the diagnosis of an ulcer. The scraping of such infiltrated places, too, may be detrimental to the patient. The lamellæ are loosened, and the contaminated point of the instrument may infect the cornea more deeply, as I have seen in some patients. I consider it possible that the art and manner of obtaining the material has an influence in deciding whether the ulcer will progress or not,[3] and desire to call attention to this point. It has, therefore, been the rule in my clinic for many years that suitable treatment must at once follow every scraping of the cornea. In diplobacillary

[1] *A. f. O.*, 1903, l., S. 99; also *A. f. A.*, 1905, lii., S. 83, and *Verhandl. der Ophth. Gesellsch.*, 1905.

[2] Failure of the serum, with exacerbation and further progress, may in some cases be due to the fact that other organisms may have infected the cornea secondarily, and these are not influenced by the pneumococcal serum.

[3] The eye must be kept steady while the material is being taken. Fixation forceps should be used in unruly patients. The point of a sterile needle is carefully passed along the progressive margin. Römer uses a platinum needle. Zur Nedden has needles of a special pattern.

THE ASIATIC SOCIETY OF BOMBAY LIBRARY

suppuration frequent instillations of zinc solution suffice; in staphylococcal and other cases the cautery should be at once applied. In cases with *Pneumococci* an active serum can be used along with the older methods. When the affection has fully developed, there may be some assistance obtainable from serum, but with the sera recommended up to the present this is uncertain.

At the Heidelberg Conference in 1903, Römer gave his clinical results with passive immunizing. With the method which he then recommended, the injection of 10 c.cm. of serum and its simultaneous local application, he obtained healing in each of twenty ulcers in the earliest stage (*vide supra*). In forty-eight advanced cases 80 per cent. were brought to a standstill by means of the serum. This very favourable result was not maintained, though the results in Wurtzburg remained much better than those recorded in the literature as having been obtained elsewhere.[1] Römer was therefore impelled to try for further improvement. By careful experiment he demonstrated that, by the active method, the injection of a dead bouillon culture (25 c.cm. of a bouillon culture concentrated to 1 c.cm.), produced an efficient and durable immunity in the experimental animal. He utilized the agglutinating action of the serum as an approximate indication of the formation of the antibodies in the system. It was proved that after intramuscular injection of the cultures the agglutinin was formed earlier and remained longer, on account of the more rapid absorption from the muscles. As this formation of agglutinin is not a certain test, control tests of the opsonic index of the blood should also be made (*cf.* chapter on 'Tuberculosis').[2]

Römer found that a combination of the active with the passive method was more efficient, and he therefore gave up the purely active method.[3] In this simultaneous method the injection of the culture has to precede the serum by some time.

I will not here go into a detailed analysis of the records of other authors;[4] that will be found in my 'Serumtherapie infectiöser Augener-

[1] The fact that strains found in the vicinity of Wurtzburg were used in the production of the serum might be considered to explain the more beneficial action of the serum in that locality. Regional peculiarities have not been shown to be present in the bacteria of this group.

[2] Römer has done this (Heidelberg Congress, 1907), and considered that opsonic examination was not applicable to pneumococcal serum.

[3] Sattler (Leipzig) was not satisfied as to the value of purely active immunization. Only very early cases were arrested; those of moderate severity appeared sometimes to stop, and then break out again rapidly.

[4] Römer states that no accurate conclusion as to the value of serum treatment can be formed from small series of cases. It is true that an extensive material alone allows us to determine what are the best possible results. Even then, in comparing the experience of years, great differences in the cases may render comparison difficult. The question which the clinician has to deal with in ulcus serpens is, Can I expect the new method to give such

krankung, Freiburg,' 1905, and in the reports of the International Medical Conference in Lisbon. By searching the records, and from personal observation, I have added to the literature[1] 120 cases treated with serum; from the collected material of about 200 cases, the following conclusions must be drawn:

In the preventive treatment of corneal abrasions with septic surroundings, Römer's serum (which will keep) can be tried along with injections of dead cultures. The cases, however, should also be carefully treated on general principles.

For an established pneumococcal affection of the cornea, serum treatment alone is only justifiable in the very early stages; we are not justified in depending on its action. Severe cases should be cauterized at the outset.

If the serum treatment be undertaken, further successive doses are indicated, and even should an advance take place, the condition may still be checked. In such cases we cannot even rely on doses of 30 c.cm. Enormous doses, even if they do in the end produce an arrest of the process, are no improvement on the use of the cautery, as the final scar will be very extensive. And even by their use there is no certainty that the process will be arrested. Delay may be fatal, and destruction result.

In cases of ulcus serpens of moderate or marked severity treatment with any of the present sera alone must be abandoned; even the assistance of active immunization is insufficient, except in cases which are relatively benign, though extensive, and in which an expectant treatment would otherwise appear admissible.

---

good results as to justify my laying aside, and replacing, the present efficient method which I possess? Even a small series may supply the answer to this question: The comparison of two apparently similar cases, the one treated with serum and the other without (Sattler), is not without value.

[1] Pflüger, *Korresp.-Bl. f. Schweizer Ärzte*, 1903. Sanz Blanco, 2 Span. Ophth. Kongr., 1904 (*Kl. M. Bl.*). Castresana, *K. M. f. A.*, 1905, xliii., ii., S. 289. Alvarado, *Archivos Hispano-Amer.*, 1904, iv., S. 662. Oliveres, *La Clin. Ophth.*, 1905, S. 179. Darier, *ibid.*, S. 29. Calderaro, *La Clin. Ocul.*, 1904. Schnege, Inaug. Dissert., Königsberg, 1904. Zur Nedden, *K. M. f. A.*, 1904, xlii. Schleich, Zeller, Wanner, *Württ. Korresp.-Bl.*, 1904, 1905. Paul, *K. M. f. A.*, October, 1905, ii., and January, 1906, i. Diehl, Inaug. Dissert., Giessen, 1905. Sattler, Heidelberger Kongr., 1905, Disc. Mayweg, 'Vers. rhein.-westfäl. Augenärzte,' *K. M. f. A.*, 1906, ii. Heilbron, *Berliner Klin. Woch.*, 1906, No. 21. F. Cohen, 'Zwang. Abhand. von Vossius,' 1907, vii. 4. Vossius, *Med. Woch.*, 1906, vii., No. 6.

Darier (*Clin. Ophth.*, 1905) and Fromaget (*Ann. d'Ocul.*, 1907, p. 59) claim to have obtained good results in the treatment of pneumococcal infection of the cornea by the use of diphtheria serum. No definite proof is furnished by their scanty material.

Deutschmann lately reported having obtained healing, in cases of hypopyon-keratitis where the cautery had failed, by the use of a heta serum (Ruete-Enoch, Hamburg). Further confirmatory reports must be awaited.

My tables also contain cases by Sattler, Peters, Fuchs, von Michel, Bach, Cramer, Seigrist, Mayweg, Schleich, Zur Nedden, Saemisch, Bjerrum, Stoewer, Dimmer, Axenfeld.

Where the older treatment cannot be used or is inefficient, especially in cases of great responsibility (single eye, etc.), serum can be used as an assistance to other means.

Its utility is therefore very limited. With more efficient methods, it may perhaps be possible to further advance the use of sera in the treatment of corneal infections.[1]

Quite recently[2] Römer reported that he had given up the use of the polyvalent serum, and that he was preparing a new serum which would be issued by the Hoechst Seruminstitut; this would not be a polyvalent serum, but one prepared from strains pathogenic for animals.

This serum is not yet available, and when it does appear will require to be tested with the greatest care and critically examined to see whether it really is any better than the other sera available. Till it is available for testing, it is better to postpone the account of the properties which Römer ascribes to it.

At present we can only form an opinion about the polyvalent serum of Merck; it is the only one which is on sale. Its advantages and disadvantages have already been considered.

[1] Concerning the use of serum in the prevention of wound infections, *cf.* p. xx *et seq.*
[2] Heidelberg Congress, 1907.

CHAPTER IX

LEPROSY, TUBERCULOSIS, AND SYPHILIS OF THE EYES

Leprosy of the Eye.

Leprosy is very frequently localized in the lids. The same characteristic disposition of the lepra bacillus is found in the lids and in the tissues of the eye as is met with in other parts of the body. Lyder and Borthen's work (Leipzig, Engelmann, 1899) contains a full account of the pathological anatomy by Lie, in which the method of spread and the demonstration of the lepra bacilli in the eye are discussed. The following works can also be consulted: Jeanselme and Morax ('Des Manifestations Oculaires de la Lepra,' *Ann. d'Ocul.*, 1898, p. 312); Francke and Delbanco (*A. f. O.*, 1900, l., p. 380); Ulenhuth and Westphal (*Zent. f. Bakt.*, 1901, xxix., p. 233); and Meller ('Keratitis Punctata Leprosa,' *K. M. f. A.*, 1905, xliii., p. 16). From these records and my own examination of preparations I come, in brief, to the following conclusions:

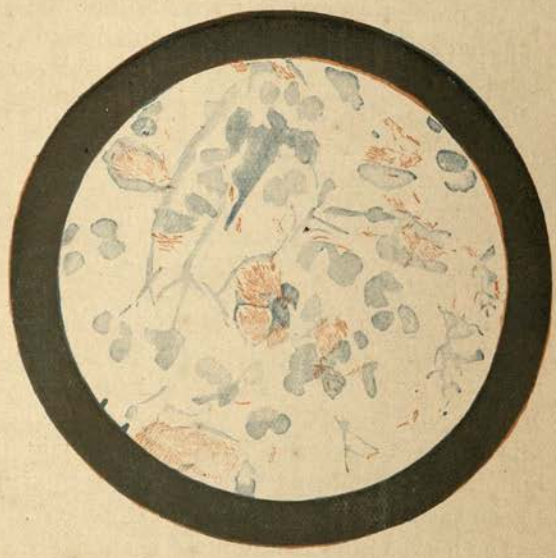

Fig. 75.—Lepra Bacilli:[1] Lepra Cells.

Large numbers of the lepra bacilli are to be found in the early stages

[1] Hansen, 'Handbuch von Kolle-Wassermann,' 1903, ii. 193.

of the tubercular form of leprosy. On account of their predilection to the early occurrence of the nodules and the spots, the eyebrows are the common site for diagnostic excisions. In the tubercular form the diagnosis is completed by an incision into the infiltrated tissues, and the examination of the expressed fluid for the lepra bacilli. (For staining methods, see p. 17.)

The nodes begin in the middle layers of the corium. Generally, but not invariably, a blood or lymph vessel can be seen in the middle of the node; the bacilli mostly lie in the cells of the intima, less often in the leucocytes. The reaction begins in the tissues after the bacilli have found their way through the vessel walls, and is usually less marked than in the case of tuberculosis. The bacilli spread into the neighbouring cells, but do not show such a destructive effect upon them as do the tubercle bacilli, and well-nourished cells showing karyokinetic figures may be found with lepra bacilli in their immediate neighbourhood. The lepromata present the appearance of being true solid tumours. Large epithelioid cells containing many bacilli are common, and are considered by Lie to be derived from wandering cells; these form the so-called lepra cells, and are always very plentiful in the central oldest part of the nodule.

The muscle cells (often pigmented) of the tunica media of the blood-vessels are generally much freer from bacilli than are the overgrown and sclerosed cells of the intima and adventitia. In general, muscle and elastic fibres are poor in bacilli.

In the leprous nodules, especially in the cornea, a new formation of vessels is often observed.

Here and there a small nerve may be seen in the middle of an avascular nodule, and numerous bacilli will be found in its endo-neurium, perineurium and sheath of Schwann. Those in the sheath of Schwann often lie in spindle-shaped clusters. According to Lie, this arrangement is not due, as many maintain, to the bacilli being in lymph spaces, but, as can easily be shown, in teased preparations, to the bacilli lying in the cells of the nerve.

The nerves thus retain their normal structure for a long time, and the nodules their normal sensibility. After a considerable time they certainly become just as anæsthetic as the spots in the anæsthetic form.

The nodules gradually coalesce, and thus diffuse nodular thickenings are formed.

The epidermis of the skin remains intact for a relatively long time. As soon as the rete mucosum is attacked, there is a defective forma-

tion of new cells, a free formation of scales, and in the end ulceration and secondary infection occur.

The cells of the rete mucosum are very often filled with granules of brown pigment. Spots without pigment (*morphœa alba*) are much less common, and are usually the result of burns, etc.

The roots of the hairs are destroyed by the free formation in their neighbourhood of new leprous tissue; the bacilli rarely pass into them, but are commonly found amongst the cells of the root-sheaths; they may even pass along the hair to the surface of the skin. By this means the bacilli can reach the exterior even when the skin appears intact.

The sebaceous glands, the arrectores pilorum, and even the sweat glands, are affected in the same way as the hairs. Lie states that the bacilli are rarely found in the sweat glands.

In Lie's opinion, though the bacilli are more prevalent in the cells, they can occur in the lymph spaces. He takes up a middle position in this much-discussed question. He considers that the well-known 'globi' (lepra cells) are principally cells laden with bacilli, but the very large ones, which can almost be seen with the naked eye, he considers not to be cells.

The Lids and Conjunctiva.—The actual skin of the lids remains unaffected till late in the disease, even when the eyebrows are filled with nodules. After a time it is affected, and then chiefly at the border; the hairs here begin to fall out, just as we have described. This loss of hair not infrequently occurs without any demonstrable change in the lid margins. Lie explains these cases by the presence of the lepra bacilli in the conjunctiva.

The nodules in the conjunctiva tend to form scales, and subsequently ulcerate. The newly-formed leprous tissue occurs in two layers, immediately under the epithelium and in the deeper layers. The cylindrical epithelial cells disappear, being partly destroyed by ulceration, and partly replaced by round cells; along with this papillary outgrowths and epithelial down-growths are commonly seen. The tarsus is affected by the deeper infiltration.

The conjunctival affection often takes the form of a diffuse catarrh, with numerous papillæ, very rich in cells.

The Globe.—A direct spread of the diseased process from the neighbouring parts is rare. Infection is much more common from the blood or lymph stream, and in this the peculiar arrangement of the vessels at the corneo-scleral margin and its neighbourhood takes an important part. It is here that bacilli are most commonly found.

As the cornea is avascular, it cannot be primarily attacked; but according as the bacilli pass in from the deep or the superficial vessels, a form of pannus or an interstitial change will occur.

Primary nodules often occur at the limbus of the conjunctiva; they agree in all particulars with those in the conjunctiva (*vide supra*). Lie considered that the nodes which occurred in the cornea or sclera, secondary to these conjunctival ones, consisted entirely of leucocytes, as he never found karyokinetic figures in the fixed corneal cells. The epithelium of the cornea remains intact for a long time, and when changes do occur, they so resemble those of the conjunctiva that Lie leans to the opinion that the peculiar corneal nodules which result consist of conjunctival or episcleral tissue which has invaded the part. E. Meyer and Berger record a case which shows what remarkable tumour-like growths are possible in the cornea (*A. f. O.*, 1888, xxxiv., p. 4). The leprous tumour was taken to be a sarcoma until Leber stained it for the lepra bacillus.

Besides growths of this form, the bacilli can spread in the lymph spaces of the cornea, where they are found in small masses between the lamellæ; they often lie in small clusters cut off from their original point of entrance. Lie thought that the bacilli in this situation had been taken up by the cornea cells. Jeanselme and Morax have given similar records. Ulenhuth, Westphal, and Greef found large numbers of bacilli throughout the cornea, although no changes could be demonstrated in it except a slight granulation at the corneo-scleral margin. From this we must conclude that the bacilli can lie in tissues which clinically are still transparent. The reaction which finally results at these points produces the flecks in various layers of the cornea, even where it is not thickened. Meller's case, resembling a keratitis punctata superficialis, belongs to this class. The bacilli lay in small clusters immediately under Bowman's membrane. This form of leprous infiltration can occur in those eyes which show no sign of a marginal leproma.

The corneal lamellæ resist the action of the leprous nodules for a time; in the end they are destroyed, but only in the immediate neighbourhood of the nodule. This accounts for the disappearance of the flecks, without leaving any marked opacity.

Lie considers that the bacillary clusters can disappear without leaving any trace and without any destruction of the tissues around.

Descemet's membrane resists still longer. The nodules which are found in the anterior chamber are derived from the uvea through the angle of the chamber.

In the same manner the episclera and the sclera can be affected. The frequency of an affection of the uvea is of great importance in many cases of leprosy. The commonest starting-point is the root of the iris, in the angle of the anterior chamber.

Lie never saw isolated nodules in the iris unconnected with the angle. In the ciliary body the bacilli commonly lie along the pigmented muscle fibres, whose radial and circular arrangement is shown in the distribution of the bacilli. A spread to the choroid occurs along the radial fibres. The free occurrence of the bacilli in the nerves of the suprachoroid appears very remarkable, as is also their connexion with the vessels of the stratum proprium and the choriocapillaris.

Generally the leprous changes in the choroid cannot be seen with the ophthalmoscope, as they are usually in its anterior part; and in those cases where the choriocapillaris, and with it the retina, is more severely affected, the changes which have taken place in the anterior segment of the eye are so great that the ophthalmoscope cannot be used. As a matter of fact, choroidal nodules are very rarely seen in lepers ophthalmoscopically. (Bistis, *Zent. f. Aug.*, November, 1899; Trantas, *Bull. de Congrès Franç. d'Oph.*, 1899, p. 275.)

Changes in the retina are uncommon, and not obvious. Occasionally masses of exudation occur in the ora serrata, and the lepra bacilli are enclosed in them and lie in the pigment cells.

The rest of the retinal destruction is due to changes in the choriocapillaris.

Lie found the lepra bacilli in the optic nerve only once, in the absence of other changes.

The lens is often secondarily cataractous, but the bacilli are never found in it; nor do they occur in the vitreous.

The ciliary nerves are often affected with a leprous neuritis, considered by Lie and Levaditi to be ascending.

In comparison with the characteristic and readily determined features of the tubercular form, the *maculo-anæsthetic form* very poorly repays examination, being only available for research in a later stage, when the bacilli are no longer to be found in the nerves and the spots.

Lie, and also Franke and Delbanco, however, were fortunate in having the opportunity of examining a comparatively recent case of this variety. In Lie's case it was a keratitis pannosa.

In the conjunctiva bulbi there was a diffuse infiltration with numerous bacilli, which also lay amongst the desquamating epithelial cells.

The anterior three-quarters of the cornea was infiltrated, with scanty

spindle-shaped clusters of bacilli between the corneal lamellæ; the walls of the new-formed vessels were less invaded by bacilli than is usually the case in the tubercular form. The changes in the iris were less marked, but the ciliary body was very rich in bacilli, and was atrophic. The bacilli passed from the ciliary body into the choroid, which also obtained some bacilli through the sclera, and from there they passed to the anterior part of the eye. In the posterior part of the eye bacilli were only found in the optic nerve, and that structure did not show any reaction.

Nothing abnormal was found in the retina, optic nerve, and lens. Bacilli were found in the lacrymal nerve and the ciliary nerves as they passed through the orbit.

Lie concluded from this case that in the pure maculo-anæsthetic leper the bacilli could live and flourish for a long time.

In this case, too, an endogenous origin was probable, as the pannus began long after the onset of the disease. Jeanselme and Morax confirmed this view of the endogenous origin of leprosy in the eye.

Francke accepts the view that the lepra 'cells' which are diagnostic in the histology of the condition are not cells, but are the outflow from the lymph vessels. He states, in agreement with Lie, that in tuberculosis fewer bacilli are found in spite of the greater reaction, and that exactly the reverse is the case in leprosy.

Kobner, Damsch, and Vossius have made experimental inoculations with leprous material of the eyes of rabbits (Rep. Heidel. Confer., 1884, p. 27). An exudation formed around the masses introduced, and in it the lepra cells long remained, and were transferable to other animals. In opposition to the others, Vossius maintained that in the rabbit's eye the bacilli could certainly multiply and pass into the surrounding tissues. He also reports having observed a gradual spread of the bacilli into the cornea.

Tuberculosis.

We are not concerned with the various ways in which tuberculosis can affect the eye. Points of bacteriological technique in the diagnosis of the bacilli alone will be considered. In Europe tuberculosis is much more important and more common in the eye than leprosy, and the methods of its demonstration and its spread can be more shortly put. The demonstration of the bacilli in this disease is not possible in nearly so many cases, nor is it so easy; and many cases of tuberculosis are diagnosed clinically and microscopically in which the

bacilli cannot be demonstrated. The clinical signs give more information than the bacteriological examination. The inoculation of suspicious material on a rabbit or guinea-pig is much more valuable as a differentiating test than is the demonstration of the bacilli.

1. Inoculation.

In making an inoculation with material from a superficial lesion, the ulcerated part is first excised or cauterized with the galvanocautery, so that the pyogenic bacteria may not ruin the test. If we have to do with compact matter, a portion is introduced into the anterior chamber. It is better not to attempt this operation on the luxated eye of the rabbit, as the rise in the tension may cause difficulties. The eye is cocainized, and then, without fixation—in fact, often without any assistance whatever—a small incision can be made up and out, about 1 millimetre from the corneal margin, the globe being merely steadied through the lids. (A deposit on the iris is more easily obtained from a peripheral incision, and makes the test more delicate.) After the escape of the aqueous, some more cocaine is dropped on the site of the incision. In two to three minutes the iris is so anæsthetic that the material can be introduced with a stylet; the material must not be left too near the incision, as it may be again extruded. The lens must not be injured.

If pure tuberculous material be introduced, the initial irritation soon disappears, and when the test is positive the well-known nodules appear in fourteen days at the earliest, and sometimes only after three or four weeks; the nodules are followed, as a rule, by general tuberculosis.

If the material be very friable, it is better to mix it with physiological salt solution and inject obliquely into the anterior chamber after the aqueous has been allowed to flow away through the cannula. The fluid can be injected into the peritoneal cavity of a guinea-pig; many consider that this latter method gives a more delicate test. It certainly has the advantage that much more material can be introduced, though the former method has the advantage that the resulting process can be much more easily observed.

Gourfein, Morax, and Chaillous recommend, in the diagnosis of the tubercular nature of an iritis, that the aqueous be drawn off with a syringe and injected into the anterior chamber a rabbit. They report positive results. We have definitely shown that this may fail in cases whichar e certainly tubercular.

Although the positive evidence is so strong, a negative result is no

proof that the case is not tubercular. I have repeatedly inoculated the anterior chamber, without result, from conjunctival and lacrymal sac tuberculosis, which, clinically and microscopically, were typical.

In such cases either the bacilli are too scanty in number, or their virulence is too slight, or their pathogenicity for the animal is insufficient to produce infection.

2. Examination for the Tubercle Bacilli.

(*Technique, cf. p.* 16.)

We hardly get the opportunity of examining the conjunctival secretion for tubercle bacilli in the same way as the sputum. The secretions from the various forms of conjunctival tubercle, which in this respect resemble lupus, are shown by the microscope not to be rich in demonstrable bacilli; tears still further dilute them. The examination of the secretion for the bacilli cannot be recommended, and is never made. A diagnostic excision gives far better results in doubtful cases of tubercle of the lids and conjunctiva.

As Morax has shown, the pus from the lacrymal sac can show tubercle bacilli, and thus a tubercular dacryocystitis can be diagnosed. Such an examination can be thoroughly recommended in doubtful cases. We cannot expect to demonstrate the bacilli in every case. Granulation forms occur in which there is hardly any secretion.[1] When a secretion is present, and no bacilli are found, it would be very risky to exclude tuberculosis.

Pus from a tubercular caries (malar bone), like other cold abscesses, may not give any definite result.

In ophthalmology stained smear preparations are of little value.

The demonstration of the bacilli in sections (*cf.* 'Technique,' p. 16) often presents great difficulty, as most of the cases of tuberculosis of the eye, especially when they are available for examination, are very poor in bacilli. Examination of serial sections will usually give a positive result; the examination of a small number of sections is not sufficient.

When acid-fast bacilli are found in the superficial layers of a superficial process, the possibility that they are 'tuberculoid' must be considered—that is, that they are allied bacilli not etiologically identical (*cf.* 'Technique,' p. 17). But when the bacilli are found in tissues which histologically show typical tubercular lesions, they may be considered to be tubercle bacilli.

[1] *Cf. Biol. Klin.*, 1907, p. 344, 'Haut-tuberculose.'

In many cases the characteristic histology is more important than any bacteriological test which can be made. When the other methods fail, we must insist on the presence of the typical tubercle, and not accept as such a few epithelioid and giant cells.

A necrosis at the centre is especially important; slight degrees are sufficient for a diagnosis.

There is a form of chronic tuberculosis of the conjunctiva and the lacrymal sac, in which the picture is not typical, though the tubercle bacilli can be found by the inoculation test. Such cases clinically present great difficulties in diagnosis; they were described by Wertz,[1] and Sulzer[2] (lacrymal sac). Stock[3] found atypical appearances in many stages of intraocular tuberculosis of the uvea, not only in rabbits, but also in the human eye.

The introduction of a pure culture of the *Bacillus tuberculosis* into the anterior chamber, provided that the strain is pathogenic for the animal used, produces a caseating inflammation, which passes on to liquefaction and perforation. It is only when minute quantities are introduced that the appearance is that of a tubercular iritis. This inoculated tuberculosis of the iris, with its local and general results, is often used for the determination of the tubercular reaction (Baumgarten, Zimmermann, and later by von Hippel and Schiek).

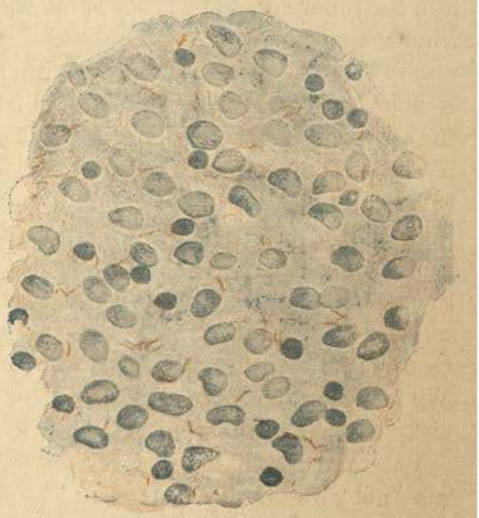

Fig. 76.—Tubercle Bacilli in Section.[4]

According to the experiments of Haensel, Panas, Bach,[5] Greef and Nakagawa,[6] tubercle bacilli in the cornea produce only slight and transient changes. It is interesting to determine which elements commence the formation of the corneal tubercles. The fixed corneal corpuscles are first affected (Marchand and Goecke, 'Experiments on

[1] *K. M. f. A.*, April, 1907, i. [2] *Soc. d'Ophth. de Paris*, February, 1907.
[3] *K. M. f. A.*, 1907, Beilageheft, and *A. f. O.*, 1907.
[4] Cornet and Meyer, 'Kolle und Wassermann,' 1903, ii. 121.
[5] *A. f. A.*, 1896, Bd. xxxii.
[6] *A. f. A.*, 1903, Bd. xlix., S. 191 (the literature is there).

Pigeons'), the wandering cells take a part later. (Regarding the occurrence of the bacilli in primary tuberculosis of the cornea in man, and for the literature, see J. Schmidt, Inaug. Dissert., Leipzig, 1903.) Wehrl considers that the so-called 'Knotchenförmige keratitis' (nodular opacity of the cornea) is tubercular.

The experiments of Lagrange,[1] Friedrich, Noeske, and particularly Stock, show that, on injection of virulent bacilli into the jugular vein of a rabbit, scattered hæmatogenous deposits occur in the choroid of both eyes. In spite of the high susceptibility of the choroid, this only leads to multiple healing nodules. In the iris and ciliary body the lesions are more severe, and recurrences more readily occur, although even here a very free resorption is possible.

Stock showed by the positive results of inoculation that even in this stage of remission and cicatrization bacilli were present in the iris tissues, and these, when inoculated on another animal, could cause an inoculation tuberculosis. There was, therefore, no attenuation, nor was there any destruction of the bacilli, but a resting stage had been produced by encapsulation.

These experimental results correspond to the clinical fact that the choroid is very often affected in miliary tuberculosis. They also show to what an extent the uvea is a site of election for tubercular deposits. They furnish a variety of clinical pictures of those chronic deep inflammations of the uvea, sclera, and cornea so freely corresponding to the obscure chronic inflammations of these structures, long ago designated by Michel as tubercular, and which have such variable courses, often being quite benign.

Deyl (*Akad. d. Wissensch.*, 1894, Prag) first demonstrated the action of dead tubercle bacilli when directly introduced into the eye.

Leber and Bruns (*A. f. O.*, 1904, lviii., p. 439) produced endogenous inflammatory nodules in the conjunctiva by the injection of dead bacilli. The nodules did not resemble either true tubercles or phlyctenules.

In Stock's experiments the lacrymal gland was often affected by endogenous tuberculosis. This agrees with my own observation that in miliary tuberculosis in man this gland may be the site of a fresh deposit of tubercle, although it is not affected by ectogenous means, even though there may be a long-continued tuberculosis of the upper conjunctiva; the infection seems unable to pass freely against the stream. In tuberculosis of the gland the demonstration of the bacilli is usually difficult, as they are very scanty (*cf.* Plitt, *K. M. f. A.*, 1905, Beilägeheft). It is important that it should be carried out on account of the differentiation from many lymphoid processes.

In spite of the accessibility of this mucous membrane to the air, the influence of endogenous infection in the etiology of tuberculosis of the conjunctiva and lacrymal sac is even greater than that which used to be attributed to external factors. (*Cf.* Lafon, *Thèse de Bordeaux*, 1904; Reis, *K. M. f. A.*, February, 1907, xlv.—both papers on 'Tuberculosis of the Bulbar Conjunctiva'; also Axenfeld, *Med. Klinik*, 1904; and 'Le Catarrhe Printanier,' Paris, 1907 [Steinheil]; and Wirtz, *K. M. f. A.*, April, 1907, xlv., on 'Tuberculosis of the Lacrymal Sac.')

[1] *Bull. du Congrès de la Soc. Franç. d'Ophth.*, 1898, p. 96.

Diagnosis and Treatment with Tuberculin.

Since Zimmermann, A. von Hippel, and Schiek showed the value of the application of tuberculin in tuberculosis of the eye, its use, which had been considered as ineffectual, has been increasing in diagnosis and treatment. For the typical tubercles of the iris, about which there is no doubt, the treatment is freely applied. It is also gradually being more freely applied to those chronic affections of the globe which, though they are not certainly known to be tubercular, from their whole course appear to belong to that group which, from clinical analogy (von Michel, Manz, etc.), and from Stock's experiments, can well be tubercular.

The following points should be noted in the diagnostic injection of tuberculin:

1. Is there any local reaction in the affected organ?
2. Does any characteristic general reaction occur?

Local reaction, recognizable by increased injection, pain, and an exudation, is definite proof of the tubercular nature of the affection. Unfortunately, this is not constant even in undoubted cases of tuberculosis. In many of my own cases only a transient injection occurred. After the injection a renewal of the precipitates, with exacerbation of the iritic symptoms, may occur. This has been observed by Michel, Haab, Manz, Uhthoff, Hess, and Stock. My own experience, which agrees with numerous other authors, is that this is exceptional.[1]

The absence of a local reaction in the cases of tubercular iritis may be due to the fact that the necessary conditions were not present, or were so to only a slight extent. Wassermann and Bruck were able to prove that antituberculin is formed in the tubercular eyes, and that its action on the tuberculin injected causes the reaction. When there is no antituberculin present, according to their theory the reaction would fail. By others the local reaction is attributed to the injected tuberculin increasing the reaction of the tuberculin already present. Others, again, hold that the tuberculous organs are especially susceptible to the action of the tuberculin.

When the reaction fails, it cannot be concluded that the process is non-tubercular.

Under these circumstances the occurrence or the failure of the *general reaction* can often be turned to account. The conclusion is, however, very uncertain, and the following points crop up:

1. Can a general tuberculin reaction always be expected from a tubercular lesion in the eye? Is the failure of a febrile reaction to be taken as meaning that there is no tuberculosis in the eye?

No definite conclusion on this point can be formed at present, especially as the

[1] *Cf.* the collected literature to 1905 inclusive, by G. Weiss, in the *Zentralblatt f. Grenzgebiete der Med. u. Chir.*, 1906, p. 401. For the ophthalmological literature, see Zimmermann, *Bull. du Congr. de la Soc. Franç. d'Ophth.*, 1898, p. 70; Schiek, *A. f. O.*, 1900, l. 2; also Groenouw, II. Aufl., Graefe-Saemisch, 1904; Hess, 'Tuberculose des Auges,' Leipzig, 1904; A. von Hippel, *A. f. O.*, 1904, lix. 1; Gamble and Brown, Jour. Amer. Med. Assoc., October, 1905; Kayser, 'Sammelreferat,' *K. M. f. A.*, 1905, i. 119; also in Stock, 'Exper. u. Klin. Studien über die Tub. des Auges,' *A. f. O.*, 1907, xlvi.; also Enslin, *Deutsche Med. Woch.*, 1903, Nos. 8 and 9.

diagnostic dose used in ophthalmology is, in the opinion of many bacteriologists, not sufficiently large to allow of a decision as to whether or not a fresh or active progressive tuberculosis is present. Koch and many others consider that when a negative result is obtained the dose in an adult should be increased to 10 milligrammes, and only when no reaction then occurs should active tuberculosis be excluded.[1]

To my knowledge such doses have hardly been used in ophthalmology. In the Freiburg clinic at first we only exceptionally went as far as 5 milligrammes; we now increase to 10 milligrammes, and in many cases obtain a positive result.

There are appearances which, throughout their whole course, give the impression of tuberculosis, but occur in persons who will not react to tuberculin. Are these tubercular or not?

It is of great importance to take notice of this point. A case of tuberculosis of the eye, confirmed either by inoculation or by histological examination, which would give no reaction even with these large doses, would be of great value in settling this question.

2. The second question is, Having obtained the general reaction, to what extent, and with what degree of certainty can we conclude that the case is one of tuberculosis of the eye, there being no local reaction?

Considering the enormous prevalence of tubercular lesions in other parts,[2] it possible that a general reaction may occur, even though the eye condition is not tubercular. If the clinical appearances of the eye are very suspicious of tubercle, this suspicion will be very much strengthened by the general reaction being positive. But without a local reaction we can only assert a greater or less probability according to individual judgment. In spite of this, when other means have not had the desired result, we may carry out the tuberculin cure, so as to provide for a possible etiology. Many valuable results are thus obtained in cases of chronic uveitis, and they are the more permanent the longer the treatment has been carried out. Recurrences are, however, not excluded.

The following are the methods of diagnosis and treatment used in the Freiburg clinic, which have been elaborated by Stock on the basis of the work of A. von Hippel:

I. The Diagnostic Injection of Old Tuberculin (Koch).

The whole body should be examined before an injection for tubercle. If an active tubercular process, of the lung especially, be found, the diagnostic injection should not be made, on account of the danger of a renewed outbreak of the disease. The two-hourly temperature should be taken for two days before the injection.

If there should be any abnormality of temperature, an injection cannot be recommended.

The best time for the injection (1 milligramme) is about eleven o'clock in the morning, when an evening rise in temperature will not interfere with that of the reaction.

The two-hourly temperature chart is continued after the injection.

[1] This is also of importance in the decision of the question, To what extent can the so-called phlyctenular (eczematous) changes occur in non-tubercular patients without the scrofulous diathesis. Reuchlin (*K. M. f. A.*, 1906, i. 352) did not obtain any tubercular reaction with 3 milligrammes in some of these cases, and therefore concluded that they were non-tubercular. We have had a patient in the Freiburg clinic with kerato-conjunctivitis phlyctenulosa, who only reacted when 10 milligrammes had been given, but did so very acutely and typically. Further tests are necessary.

[2] Naegeli examined 100 bodies in Zurich, and found tubercular changes in 90 per cent.

The rise in temperature will commence in the early morning. The first record must, therefore, be taken at five o'clock.

The height of the reaction occurs from eighteen to twenty-two hours after the injection. Rises in temperature may occur for forty hours. An interval, therefore, of forty-eight hours must intervene between two injections. If there be no result from the first injection, after two days 5 milligrammes are injected.

If a slight objective or subjective reaction has been obtained, which cannot be called positive, another 1 milligramme should be injected after forty-eight hours. Only after this injection has a negative result should we proceed with 5 milligrammes and 10 milligrammes. If still no marked reaction occurs, the result can be considered as not positive, but by this the tubercular nature of the process is not excluded.

A *general reaction* is considered as positive when—

1. A rise of temperature to at least 37·5° C. (99·5° F.) occurs.

2. There is a well-marked subjective reaction, such as headache, with malaise and loss of appetite.

In a few cases a *local reaction* in the eye, consisting of a severe ciliary injection, and an increase of the inflammatory symptoms occurs. The injection fluid used is a solution of 1 c.cm. of old tuberculin, 50 c.cm. phenol, and 100 c.cm. of distilled water: $\frac{1}{10}$ c.cm. of this lotion contains 1 milligramme of the old tuberculin.

II. Therapeutical Injection of the New Tuberculin T.R.

Method of von Hippel:

The first dose is $\frac{1}{5000}$ milligramme of the dried substance. A second injection is made every second day, and at each the dose is increased by $\frac{1}{5000}$ milligramme. When $\frac{1}{500}$ milligramme is thus reached, the increment is raised to $\frac{1}{500}$ milligramme, and from $\frac{1}{5}$ milligramme onwards the increase should be $\frac{1}{10}$ milligramme, always provided that the temperature does not rise above 38° C. (100·50 F.). More than 1 milligramme should not be given. This dose should be continued until the disease is completely healed. If the temperature rises above 38° C. with a smaller dose, that dose, or the next lower, should be repeated until there is no reaction.

In 1898 Zimmermann, as the result of his experiments, stated that the initial dose should be $\frac{1}{5000}$ milligramme, and that it should not be raised above 0·02 to 0·03 milligramme.

In many patients the dose cannot be increased to 1 milligramme.

The individual maximal therapeutical dose must be discovered for each patient—that is to say, that dose which will just avoid a reaction. Such a dose will continually change, as the patient becomes used to the medicament. It should also be noted that the susceptibility of the body at first rises—that is, there is a cumulative action of the drug.

Three solutions of increasing percentage are used as injections:

I. A solution of 2 : 1000;
II. „ 2 : 100;
III. „ 1 : 10.

A. Beginning with $\frac{1}{10}$ c.cm. of solution I. ($\frac{1}{5000}$ milligramme), the dose is increased by $\frac{1}{10}$ c.cm. ($\frac{1}{5000}$ milligramme) up to 1 c cm. ($\frac{1}{500}$ milligramme).

B. $\frac{1}{10}$ c.cm. of solution II. ($\frac{1}{500}$ milligramme) is then used, and this dose is increased by $\frac{1}{10}$ c.cm. ($\frac{1}{500}$ milligramme) up to 1 c.cm. ($\frac{1}{5}$ milligramme).

C. Continue with $\frac{1}{5}$ c.cm. of solution III. ($\frac{1}{5}$ milligramme), increasing by $\frac{1}{10}$ c.cm. ($\frac{1}{10}$ milligramme) up to 1 c.cm. (1 milligramme).

Method of preparing the solutions:

One c.cm. of the tuberculin as sent out contains 10 milligrammes of the solid substance.

Solution I.	0·02 c.cm.	of the original solution	+ 10 c.cm.	glycerine;
„ II.	0·2 c.cm.	„ „	+ 10 c.cm.	„
„ III.	1·0 c.cm.	„ „	+ 10 c.cm.	„

The tuberculin content of the solutions refers to the solid substance.

Perfectly clear and fresh solutions should alone be used. Solutions which are older than fourteen days are cloudy and no longer efficient.

Von Hippel and many other ophthalmologists state that, following this plan, a cure can generally be arrived at, and that it can be done without any risk of damage. The good results which have been recorded by different authors are so numerous that many see no necessity to control the treatment by complicated bacteriological methods.

Such an extension of the treatment is strongly recommended by Wright, the introducer of the 'opsonin theory,' and by many English practitioners. They insist that continued tests should be made to see whether the tuberculin has raised the opsonic power of the blood-serum of the patient, or has maintained it at a high level.

On account of the interest which Wright's teaching has aroused, and the increasing attention which it is receiving, I will shortly give the principles underlying it.

The tuberculin is injected with the intention of producing an increased reaction in the blood,[1] and a curative effect in the diseased focus. Wright attempted to influence local infections of varying origin by introducing the dead cause of the inflammation into the blood-stream, and thus induce the formation of antibodies, especially to cause an increase in the phagocytic action or 'opsonic power.' The diseased organ, which cannot form antibodies for itself, is thus assisted, and healing is promoted. It is an active bactericidal immunization with dead bacteria such as has already been discussed in reference to pneumococcal serum treatment, which obtains in those infections where no antitoxic serum treatment (as is possible in diphtheria) can be carried out.

Wright describes methods by which the phagocytic power of the body, and its variation when tuberculin or dead cultures—vaccines—are injected, can be measured and controlled.

By 'opsonin' Wright means that substance in the blood which, coming into contact with the bacteria, so changes them that they are taken up by the poly-nuclear leucocytes and destroyed. The normal serum possesses a certain amount of this opsonic power, varying with the individual and the particular bacteria.

When an infection occurs, this power will fall under the influence of the bacteria which have entered. When the infection is not too strong, there will be a reaction and an increased production of opsonin (a substance belonging to the group of the 'bactericidal' antibodies). When the infection has passed away, or has been overcome, the opsonic power of the blood is higher than it was at first, and above the

[1] Antituberculin is found in the circulating blood after the injection of tuberculin though it does not occur there in cases of localized tuberculosis (Wassermann and Bruck).

normal. This is especially the case for an immunized animal. Immune serum taken from such an animal, on account of its opsonin contents, has the power of raising the opsonic power of another individual, thus causing a passive immunity. Similarly the body will itself actively form opsonin when small doses of dead bacteria are introduced into it.

The new tuberculin (Koch) contains broken-up and dead tubercle bacilli.

If a small dose be injected, the phagocytic power is reduced by the poison introduced, as is the case for all injections of this kind, and a negative opsonic phase begins. This will be followed by an increase in the formation of opsonin, provided that the infection be not too severe. The phagocytic activity—the opsonic power—increases, and the conditions are in general more favourable for the healing of the local affection in question.

Wright lays special importance on the hypothesis that no new injection should take place during the negative phase or period in which the opsonic power is sinking, otherwise this power may be successively reduced. Only during the positive phase is a new dose to be injected, and the amount should be regulated according to the 'opsonic index.'

The term 'opsonic index' is used by Wright to mean the proportion between the opsonic power of the individual affected and that of a normal man. It is determined in the following manner:[1]

1. Under aseptic precautions some of the blood of the patient is drawn off in a capillary pipette and centrifugalized. The cell-free serum is collected.

2. Blood is taken from a normal individual, mixed with isotonic 10 per cent. citrate of soda solution to prevent coagulation, freed from serum, and then washed with saline. An equal quantity of the solid elements of the blood (red and white corpuscles) is added to the serum obtained in process (1) from the patient.

An equal quantity of a dilute suspension of the bacteria to be tested (here the *Bac. tuberculosis*) is then added.

The mixture (patient's serum, normal corpuscles, and bacteria) is then placed in the incubator for fifteen to twenty minutes at 37° C. From the mixture evenly-spread smears are made, dried, carefully fixed in the flame, and stained. The polynuclear leucocytes are examined in various fields, and the number of bacteria contained in 60 to 100 of them is determined; the leucocytes tend to collect at one end of the preparation. The number of these bacteria divided by the number of the cells is the 'phagocytic index.'

An exactly similar examination is made of the serum of a normal individual, and the phagocytic index then obtained is compared with that of the patient.

$$\frac{\text{Phagocytic index of the patient}}{\text{Phagocytic index of a normal man}} = \text{Opsonic Index.}$$

This opsonic index or opsonic power of the affected person informs us whether the resistance is raised or lowered. The index must be worked out for the individual bacterial strain. All estimations must be made by the same person, so as to reduce the personal factor.

The 'opsonic power' can be raised by the various methods of immunizing—the injection of immune serum (passive), the injection of bacteria or their toxins (active)—which can induce in the body the active formation of antibodies, in this case opsonins. In the discussion of the pneumococcal serum treatment (p. 331) it has been stated that the action here is not a direct bactericidal one, but a 'bacteriotropic' (Neufeld and Rimpau). This view corresponds to a great extent with the 'opsonic'

[1] For further details, see the publications of Wright and his pupils.

theory of Wright. The same holds, to a greater or less extent, for immunization and treatment for *Streptococci, Staphylococci, Gonococci*, and other organisms.

By the injection of small doses of the dead bacteria, Wright sought to increase the opsonic power, and thus to produce general and local cure. As far as possible the organisms used were taken from the patients themselves, with the great advantage that the vaccine was suitable to the cause of the disease. From patients with furunculosis or acne the *Staphylococci* were cultivated from a pustule, cooked to 60° C., and then in small doses injected hypodermically—a method of treatment which is very highly thought of by many, and one which can be used for chronic cases of blepharitis ulcerosa, etc.[1]

Wright does not now insist on this for the *Staphylococcus;* he does not consider that the race differences are so important in the case of this organism. For *Pneumococcus* and *Streptococcus*, however, it must be taken into account.

With regard to tuberculin treatment, Wright has come to the conclusion that very small doses are sufficient to raise the opsonic index to its maximum: $\frac{1}{5000}$ to $\frac{1}{2000}$ of a milligramme is sufficient to produce a reaction, and a larger dose is not necessary. The dose should be repeated every three weeks. It is still to be proved whether such a dose is sufficient in tubercle of the eye. From the clinical point of view it is quite certain that von Hippel's method of dosage, already described, has been innocuous in many cases, and has given many good results in ophthalmic practice. It would be very interesting if the opsonic index of a case treated in this way was worked out, to see if the clinical course of the disease might be compared with this varying power of the serum. It would then be obvious to what extent the purely clinical dosage was correct from the opsonic standpoint.

It is impossible in every case to carry out such complicated and tedious processes as are necessary in opsonic work, especially when skilled assistance is not available. When a sufficiently large number of cases have been worked out, the correct dosage may be ascertainable, without the necessity of always controlling it by the actual opsonic index. It must first be shown whether the bacterioscopic results furnish a reliable index of the progress of recovery in the various forms of tubercle of the eye.[2]

Certainly Wright's method of scientific estimation and control of active and passive serum treatment (*e.g.*, in pneumococcal serum treatment) deserves further and more extensive application.

[1] Nias and Paton (Lancet, 1906, p. 1500) have determined the opsonic index for tubercle in cases of phlyctenular eye affections during treatment (local and general, but not tuberculin), and state that, on the healing of ulcers, the index, which had at first been very low, rose; the index for *Staphylococci* in these persons was from the first unchanged.

[2] It is possible that in the positive phase, which Wright states to be the time suitable for further injections, the freshly introduced tuberculin may be attached to the anti-tuberculin already present.

Syphilis.

Until the present syphilitic lesions of the eye (hard sore, secondary and tertiary affections) have given no opportunity for their bacteriological examination. If the *Spirochæta pallida* is confirmed as the cause of syphilis, and the signification of the silver impregnation method be established, the determination will be of enormous value to the ophthalmologist.

Zur Nedden and Puccioni found *Spirochætæ* in the fluid drawn off from the anterior chamber in acute iritis (Heidel. Congress, 1906, and *La Clin. Ocul.*, 1906, vii., p. 2682); and Stephenson (the Ophthalmoscope, 1907, p. 143, 'The Cornea in Keratomalacia in Syphilitic Children'), Stock, Peters, Römer, Bab, and Stargardt, have demonstrated the *Spirochæta* in the cornea of prematurely born syphilitic children, using the silver method of Levaditi.

According to Stargardt, the *Spirochætæ* are freely found in the deeper layers of the cornea in syphilitic children. They are best seen in tangential sections, in which they are often arranged in parallel or crossed rows (with them wandering cells tend to invade the cornea). In stillborn cases, such as that of Bab's, a post-mortem impregnation from the amniotic fluid, or from the interior of the eye, was possible. A deep ring infiltration in a syphilitic child examined by Reis showed no *Spirochætæ*. Perhaps this keratitis was only a toxic reaction caused by the amniotic fluid.

Bertarelli (*Zentralblatt*, 1906, Beiheft, S. 111) injected an emulsion of a chancre into the anterior chamber of a rabbit, and in fourteen days was able to demonstrate numbers of *Spirochætæ* by the silver method. They lay between the normal and infiltrated portions of the cornea.

In the iris no *Spirochætæ* could be found. A pure corneal infection (by a pocket) did not give a positive result. In a further paper (*Centr. f. Bakt.*, Orig., xviii., 1907, p. 448) Bertarelli states that the virus can be transferred from one cornea to another, and that the virulence rises. The inoculated virus produced syphilitic symptoms in apes, and in the end was pathogenic for guinea-pigs.

Scherber inoculated the rabbit's anterior chamber, and obtained a deep inflammatory reaction in the cornea, resembling a keratitis parenchymatosa. Small nodules had previously formed at the pupillary margin of the iris (*Wien. Klin. Woch.*, 1906, No. 24). These results are open to the objection that the *Spirochætæ* demonstrated may only have been those originally injected. In the experiments of

Greef and Clausen (*Deutsche Med. Woch.*, 1906, No. 36) such a small quantity of material was inoculated, and the *Spirochætæ* were found in such numbers in all the layers of the cornea that an active proliferation must be admitted. (Their inoculations consisted in scarifying the iris with the injecting needle, in rubbing syphilitic material into epithelial wounds, and in introducing small pieces of material from buboes into the anterior chamber.) In the eye into which the piece of tissue was introduced a central corneal perforation occurred; when the other method of inoculation was used, a deep keratitis occurred after five weeks' interval, and numerous spirals were found in tangential sections (Greef and Clausen quite exclude all possibility of the appearances being due to fibrous tissue or nerve-endings).

Further confirmatory inoculations of the same nature are recorded by von Growven (*Deutsche Med. Woch.*, 1907, Vereinsbeilage, p. 911), Tomaczewski (*Münch. Med. Woch.*, 1907, p. 1023).

The experiments quoted[1] show that it is possible to infect rabbits' eyes with syphilis. Haensell (*A. f. O.*, 1881, xxxvii., 3) described such inoculation changes clinically and histologically, and Schultze (*K. M. f. A.*, 1905, Bd. ii., S. 252, and *Berl. Klin. Woch.*, 1906, No. 82) experimentally proved and recorded its inoculation. In one respect the inference from his experiments was quite different from that of the former authors. He does not report having found the *Spirochæta*, which, with Siegel and Saling, he considered a casual contamination, or else an artifact in the connective tissues (silver *Spirochætæ*). He reports finding the so-called *Cytorrhyctes luis* (Seigel). For the details of Schultze's paper, the original in the *K. M. f. A.*, 1905, must be consulted.

Weighty reasons are given by Levaditi, Gierke,[2] and other competent authors for the rejection of these arguments of Schultze and Salings. Their statement that more attention should be paid to nerve fibres in silver preparations is quite right.

Preparations are made of the exudations from the tissues, or the tissues themselves. In the case of non-ulcerative processes, we can aspirate or apply a vesicatorium, and then use the contents of the vesicle produced.

Spirochætæ have only been found rarely and sparsely in gummatous lesions. When the *Spirochætæ* have uudergone an alteration for a

[1] Schucht (*Münch. Med. Woch.*, 1907, p. 110), by corneal and anterior chamber inoculations, often obtained a keratitis parenchymatosa after nineteen to forty-three days. Iritis could be developed from the anterior chamber, and also from the vitreous; later, a keratitis parenchymatosa, with *Spirochæta* (according to Giemsa and Levaditi), resulted. On several occasions gummatous or condylomatous changes were developed in the iris.

[2] *Berlin. Klin. Woch.*, 1907, p. 75.

generation, it is possible that they, like the *Trypanosomæ*, will not show their usual form in many of their stages.

Spirochætæ are scanty in the Giemsa preparations; a considerable number of them must therefore be stained and examined. In superficial processes, according to Schaudinn, another *Spirochæta* is occasionally found, the *Spirochæta perfringens*. This stains much more clearly with the ordinary aniline stains, and with the Giemsa method is blue and has no flagellæ.

According to Schaudinn, the *Spirochæta pallida* is between 10 and 15 μ in length (by the silver method still longer spirals can be found), and of an even breadth of only $\frac{1}{4}\mu$. The ends are pointed, and have each a cilium. The coils are sharp, regular, short, and about 1 μ long.[1] (For methods, see 'Technique.')

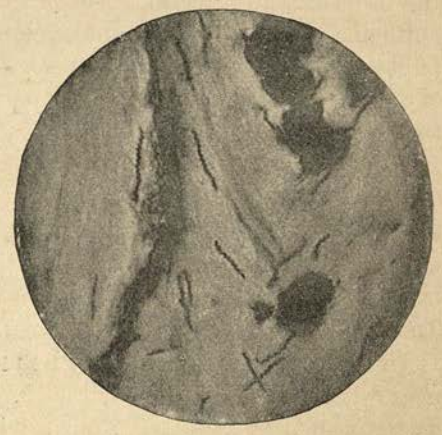

FIG. 77.—'SPIROCHÆTÆ' IN THE CORNEA OF A RABBIT: TANGENTIAL SECTION.

Microphoto by Hoffmann and Bertarelli; silver method.

Positive inoculations can be made on apes; the skin of the eyebrows and the lid margins, as well as the genitals, is specially suitable for inoculation. The surface is scarified, and the syphilitic material is rubbed in. In two to seven weeks a hard sore results, and the usual symptoms follow.

[1] Full details of the appearances and the differential diagnosis are to be found in the monograph by E. Hoffmann, 'Die Atiologie d. Syphilis,' Berlin, 1906 (J. Spinger).

CHAPTER X

ENDOGENOUS INFECTIONS

Endogenous Infections of the Conjunctiva

(*Cf. section 'Conjunctivitis, General,' p.* 108).

Endogenous Infections of the Cornea.

THE avascular cornea can only be reached by the pyogenic organisms from the blood-stream indirectly. An isolated corneal metastatic abscess, in the sense that such an irritant can settle down and show activity in the transparent cornea away from the margin, is impossible; the organism produces its irritation at the spot where it leaves the walls of the vessels. It cannot spread into the avascular tissue of the cornea, and then form an abscess at some distance.

On the other hand, it is quite possible that the cornea may suppurate from a septic embolism of a marginal vessel, as in the case of streptococcal sepsis anatomically examined by Leber and Wagenmann.[1] Michel reports a similar case. A suppuration of the cornea is also possible as the final event in a panophthalmitis resulting from metastatic infection of the interior of the eye. A ring abscess of the cornea may develop, even when the bacteria are not in the anterior chamber, if the site of the suppuration is deep, and the toxic action is conveyed by the aqueous. I have seen a case of commencing suppuration of the cornea, due to a remote agency, in which an anatomical investigation showed that the *Pneumococci* were restricted to the vitreous and the parts behind it. In other cases (and this is always the case in actual suppuration) the pyogenic bacteria are active in the anterior chamber; this occurs at an earlier stage when septic metastases have taken place in the iris or ciliary body (*cf.* Morax's pneumococcal case). Saltini's[2] anatomical examination shows that the organisms can finally destroy Descemet's membrane, and penetrate into the substance of the cornea.

[1] *A. f. O.*, 1888, xxxiv., 4, p. 251. [2] *Rassegna di Scienze Med.*, 1894.

In these cases, just as in many ectogenous infections of the cornea, the clinical appearance of a ring abscess results from the concentrated action of the toxin from behind on the central layers of the cornea.

In benign and milder cases of metastatic ophthalmia we naturally can have minor corneal affections.

That peculiar affection of early life the **ulcus corneæ internum**, which appears clinically related to keratitis parenchymatosa, and leads to secondary hydrophthalmos, is referred by E. von Hippel[1] to an endogenous infectious action from behind. The type of virus which causes the lesion is not determined. It cannot be any of the known pyogenic organisms, as these could not fail to produce severe intra-ocular changes if they acted so destructively on the cornea. (The interesting researches of Leber and Addario[2] show that intra-uterine metastatic changes can occur in the eye. They found a suppurative inflammation, apparently commencing from the retina, in the eyes of two newly-born goats, and in the exudate there were many Gram-positive bacilli, showing polar staining, which from their shape evidently belonged to the group of the pseudo-diphtheria bacilli.)

Keratitis parenchymatosa[3] is a chronic endogenous inflammation of the cornea, and is much more important; the most important factors in its etiology are syphilis, tuberculosis, and leprosy, and these are so important that it is a matter of dispute whether in those cases which have been ascribed to other agencies a combination with syphilis or tuberculosis was not present.

We have to consider whether this condition is due to a pure toxic action or to an infection of the cornea. The old idea, which was supported by Panas, that the whole affection was purely toxic, and the result of a general dyscrasia, without the deposition of any organisms in the eye, was shown to be unlikely when Michel, Bongartz, Bach, Zimmermann, Burstenbinder, and E. von Hippel proved that in the tubercular form actual tubercles were formed in the cornea.[4] The examination of the syphilitic cases for *Spirochætæ* may throw light on this subject. Stargardt, Bab, Peters, and Römer[5] have demonstrated the *Spirochætæ* by the silver method in the corneæ

[1] 'Das Ulcus Corneæ Internum,' *Festsch. f. A. von Hippel*, Halle (Marhold), 1899. Peters (*K. M. f. A.*) considers that the condition is due to a failure in development. Hippel's findings can quite well have been due to inflammation.

[2] *A. f. O.*, 1899, xlviii., 1, p. 192; *cf.* also Hoppe, *A. f. A.*, xliv., p. 225.

[3] For literature, see sec. 'Path. des Auges,' Lubarsch-Ostertag, 1894-99, Axenfeld; 1900-1905, Stock; also Dissertation by Rabiger, Berlin, 1906.

[4] Wehrli considers that 'nodular opacity of the cornea' is a tubercular form of lupus (*Z. f. Z.*, 1905, xiii. 322, and *K. M. f. A.*, 1906, Bd. ii.; also Heidel. Congr., 1907).

[5] See *Ophth. Gesellsch.*, Heidelberg, 1906.

of congenital syphilitics, though not in cases of marked interstitial keratitis.[1] Reis was unable to demonstrate their presence in the cornea of a new-born syphilitic suffering from keratitis annularis parenchymatosa.

The inoculation experiments on the cornea of the rabbit (*cf.* section 'Syphilis,' p. 357) indicate that the *Spirochætæ* can settle down in a cornea which is still intact clinically, just as can the lepra bacilli. Different conditions obtain for these pathogenic agents than are present in the case of the pyogenic. The lepra bacilli (and perhaps also the *B. tuberculosis*) can leave the vessels and spread into the avascular cornea without the localizing action of an inflammation, and without producing any changes at the site of entry. These organisms appear to be able to collect in a cluster in the transparent tissues, and thus form, away from the margin, a nodular opacity, which later becomes vascularized. This condition is especially associated with a toxic action from the aqueous, corresponding to that obtained in the experiments of Leber, Mellinger, and others who produced deep inflammation of the cornea by injection of toxic material into the anterior chamber, and also by mechanical irritation of the endothelium.

Stock has shown that parenchymatous inflammation can occur from the toxic action of the infected aqueous; in his experiments tuberculosis of the iris was accompanied by a simple inflammatory infiltration of the cornea. It remains to be seen to what extent this is the case in man, and whether, in those cases where there is no diffuse cloudiness, but only a well-marked deep keratitis, we really have to do with a corneal infection. Elschnig's researches[2] regarding recent keratitis parenchymatosa syphilitica show that the central, deeply-placed infiltrates need not have any connexion with the anterior chamber.

We can quite understand how motile organisms—*e.g.*, *Spirochætæ*—can wander in and concentrate in the avascular cornea. It is more difficult to explain in the case of lepra bacilli how a cluster can occur in this situation (*cf.* section 'Leprosy,' p. 340); we can hardly consider that there is a centrally directed lymph stream (Gruber, Leber). Perhaps the fixed cells of the part may have a phagocytic action.

Some recent researches are of especial interest regarding this point; Stock,[3] Römer,[3] A. Leber, Stargardt,[3] Morax,[4] have experimentally produced a parenchymatous keratitis by infection with **Trypanosoma,**

[1] The lesions found in macerated or stillborn fœtuses are not conclusive evidence with regard to intra-vitam localization and distribution of an affection. *Cf.* cases by Schlimpert (*Deutsche Med. Woch.*, 1906, p. 1942) and Bab (*ibid.*, p. 1946). The conclusions which these authors draw from their findings are not free from fallacies.

[2] *A. f. O.*, 1906, lxii. 481.

[3] Ophth. Cong., Heidel., 1906.

[4] *Ann. d'Ocul.*, 1906, cxxxvi. 437.

a protozoon belonging to the group of the Flagellatæ, and which, according to Schaudinn and others, is closely related to the *Spirochætæ*. In this we have discovered a means of producing keratitis parenchymatosa experimentally from the blood; with it is associated a severe inflammation of the uveal tract, especially of the iris and the ciliary body. Stock has demonstrated *Trypanosoma brucei* in the aqueous of dogs; he also found them in sections of inoculated mice, but not in the cornea. In these cases the keratitis appears to be due to a toxic action of the aqueous, in the same way as was the hæmatogenous tuberculosis of the iris in Stock's experiments. Stargardt found the *Tr. evansii* in the cornea of the guinea-pig, and Morax reports similarly on the *Trypanosoma* in the goat. Stargardt states that the *Tr. evansii*, like the *Spirochæta pallida* in syphilitic infants, when occurring in association with an iritis, is most commonly found in the deeper layers of the cornea. Stock, on the other hand, has since found the *Tr. brucei* in the anterior layers of the cornea without an iritis. Keratitis can occur alone, due to the *Trypanosoma* (*Ann. de l'Instit. Pasteur*, January, 1907, xxi.; *Münch. Med. Woch.*, 1907, No. 21; *Soc. d'Ophth. de Paris*, March, 1907.)

In smear preparations from the aqueous or from the blood, the demonstration of the *Trypanosoma* is best accomplished by means of the Giemsa stain (*cf.* 'Technique,' p. 18). In sections it is best to use the polychrome methyl-blue method (Stargardt stains for twelve hours, rapidly dries, and then immerses in absolute alcohol for a very short time). The most certain method is to inoculate a mouse with the material (aqueous fluid), and later to examine its blood for the *Trypanosoma*.

It was known, as Stargardt and Morax have shown, that not only blepharoconjunctivitis, but also severe inflammations of the globe, occur in diseases of animals, which we now know to be due to *Trypanosoma* (Nagana, Surra, Suma, Mal de Caderas, Dourine, the Syphilis of horses). Morax reports that he found many *Trypanosomæ* in the secretions of this form of conjunctivitis, when not purely secondary to an infection of the globe; Stargardt only found the organisms in the tissues. The results varied in different animals and in different *Trypanosomæ*, similarly in the inflammations of the globe, which usually occur several weeks after an infection.

In sleeping sickness, the trypanosomiasis of man, such changes in the eye have never been observed; there has been at most a lid œdema. By direct inoculation of the virus of this disease, the *Trypanosoma gambiense*, into the anterior chamber, Römer and Leber have produced keratitis parenchymatosa. The method of action from the blood-stream has not been determined.

Seeing that the *Trypanosomæ*, according to Schaudinn, are closely related to the *Spirochætæ*, these experiments are of great interest in the discussion of syphilitic changes. Spielmeyer (*K. M. f. A.*, i. June, 1907), working with *Trypanosoma*, has produced changes in dogs which closely resembled tabes and paralysis, and in which a well-marked optic atrophy could be demonstrated.

LITERATURE OF METASTATIC CORNEAL ABSCESSES.

AXENFELD, A. f. O., 1894, XL, 3, S. 89.
FUCHS, A. f. O., 1903, LVI, S. 1 (previous literature).
v. HIPPEL, E., Das Ulcus corneæ internum. Festschr. f. A. v. HIPPEL. Sammlung zwangl. Abhand., Marhold-Halle, 1899.
LEBER-WAGENMANN, A. f. O., 1888, XXXIV, S. 251.
v. MICHEL, Discussion on Axenfeld's communication, Naturforscher-Vers. Nürnberg, 1893.
MORAX, Ann. d'ocul., 1904, CXXXII, S. 409.

Endogenous Inflammation of the Globe

(METASTATIC OPHTHALMIA).[1]

Although purulent inflammations only differ from non-purulent in degree, and although we know that the causal agents of the former under special conditions can cause non-purulent, serous, or plastic inflammations; yet the purulent hæmatogenous inflammations arising in the eye can be put into a special class, for we know with certainty that in every case pyogenic organisms have settled down in the affected part of the eye. We cannot infer, in an endogenous purulent inflammation, that the toxins, which were circulating in the blood, have settled down at one spot; the hypothesis that such a microbe-free metastatic ophthalmia exists is quite without proof.

The fact that in this or that case no organisms could be found in the globe is not conclusive, for in many cases the germs rapidly die out in the exudates,[2] and in others their microscopic demonstration is difficult, and perhaps it has not been attempted at the right place. The whole mass of the exudate need not be septic; for example, sterile pus may form in the anterior chamber, due to the distant influence of infection in the vitreous.

The experimental examination of apparently endogenous toxic wound suppuration is not conclusive; we have shown this in the section on 'Wound Infection' (*cf.* p. 103).

The question—Toxic or bacterial metastatic?—is more difficult in the case of the milder endogenous inflammations, which are non-purulent.

[1] The collected older literature is given by Axenfeld, *A. f. O.*, 1894, xl. 3, 4; also in 'Ergebnisse,' Lubarsch-Ostertag, 1895-1900, Axenfeld.

[2] *Cf.* later, p. 367.

Localized inflammations in other organs (joints, kidneys, etc.) are recognized as due to circulating poisons, and the gouty affections of the eye are of chemical nature.

From these examples of endogenous inflammation from the localization of some definite poison we cannot draw any general conclusions regarding other poisons. With regard to infectious diseases, and the participation of the eyes in them, it is still more important to consider each infection by itself. As to the circulating toxins of the septico-pyæmic conditions, we only know that they will produce certain

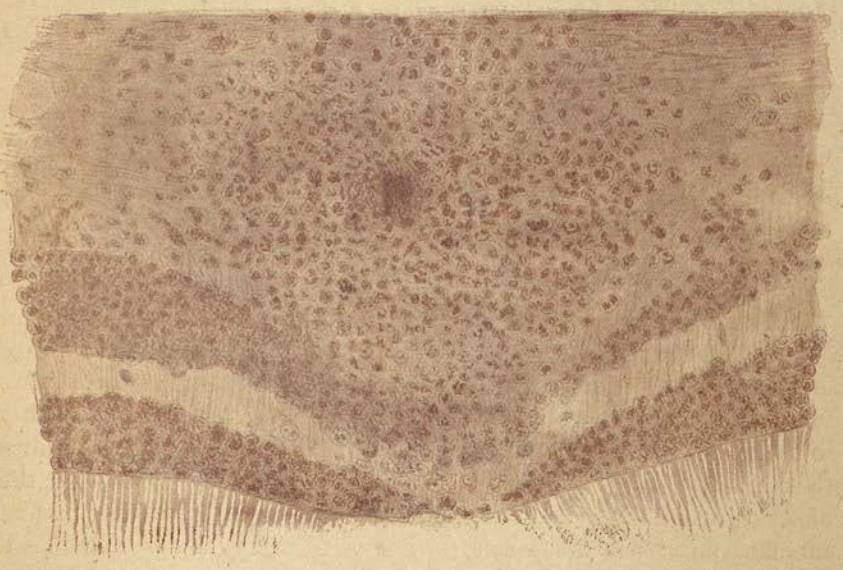

FIG. 78.—BENIGN METASTATIC NODULE IN THE RETINA. GRAM-WEIGERT STAIN.

In the centre a degenerated mass of *Pneumococci* surrounded by phagocytes.

changes in the eye, the so-called retinitis septica (Roth), consisting in hæmorrhages and nodules of swollen ganglionated nerve-fibres and fatty degenerated cells.[1]

Axenfeld and Goh have shown that hyaline and laminated thromboses may be formed in the vessels of the choroid and the retina.[2]

[1] In exceptional cases of typhoid (Paul, *K. M. f. A.*, July, August, 1906) pure toxic changes in the retina occur. In close association with these forms of septic retinitis are the changes which occur in many of the severe forms of anæmia (pernicious, cancerous, anchylostomiasis), where the blood is being destroyed and toxic material is present, and also the changes which occur in diabetes, nephritis, etc.

[2] In rare cases, such as those which were examined by Goh and Yamaguchi, a diffuse collection of lymphocytes occurs amongst the choroidal vessels without any deposition of

There is no proof, however, that the circulating **toxins** of the organisms can produce any **localized** inflammation in the eye.[1]

It is much more likely that a considerable proportion of the mild, benign, endogenous inflammations of the eye which occur in the course of sepsis and other infectious diseases, as well as the apparently spontaneous cases, are due to **bacterial metastases.** This is shown by many clinical observations, especially in those cases where, on the one side, there is a severe suppuration, and on the other a mild transient inflammation.

Axenfeld and Goh[2] showed that very mild benign metastatic inflammations of the eye due to the deposition of organisms can occur

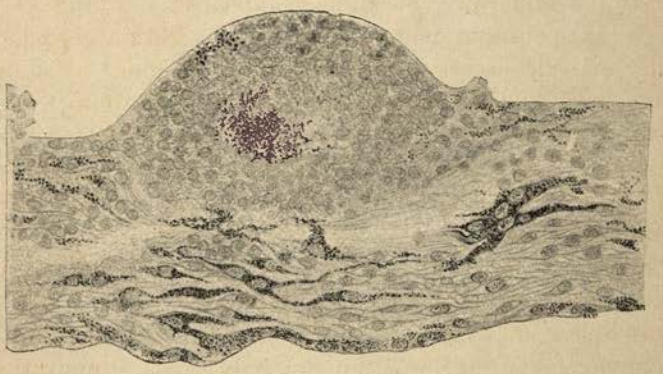

FIG. 79.—VERY SMALL METASTATIC DEPOSIT (DISSEMINATED CHOROIDITIS): PNEUMOCOCCI VIOLET.

in cases terminating fatally; they showed that *Pneumococci* were present in the small transient nodules in the choroid or retina. On

---

bacteria being found. This result is closely allied to those of Stock and Meller, who found choroidal infiltration in many cases of leukæmia; perhaps the pronounced destruction of the blood in these cases of septic pyæmia has a similar influence. In the future attention must be directed to the question whether such cases do not belong to the lately discovered group of the 'acute leukæmias,' combined secondarily with sepsis. For further information on this point, see Stock. *K. M. f. A.*, 1906, xlii., Bd. i., p. 328.

[1] Dolganow reports that, by subcutaneously injecting dead cultures of *Staphylococci*, he obtained inflammatory changes in the optic nerve of the rabbit; these results require confirmation. Rosenmeyer, in a previous communication (Heidel. Congr., 1905, p. 240), reported that dead cultures of *Staphylococcus aureus*, which had been cultivated on the vitreous of rabbits, on injection into the blood produced infective deposits in the choroid, with opacities in the retina; in one case he obtained an iritis. Rosenmeyer concluded that the nutritive medium used had produced such a specific affinity of the coccus for the uveal tract that the toxin alone was able to produce a hæmatogenous inflammation; we should note, however, that such dead cultures contain in the dead organisms still present, material which is capable of producing a metastasis. A pure toxic action, in the sense here meant, can only be demonstrated by the use of dissolved or filtered cultures. Such tests have not yet been published.

[2] Heidel. Congr., 1896, p. 282, and *A. f. O.*, 1897, xliii., i., p. 147.

account of the great importance of this case, I give some of the drawings.

The central mass of *Pneumococci* in the retinal deposit (Fig. 78) is already in a state of degeneration; it stains badly, and shows involution forms. In the vicinity there are many phagocytes. The neuro-epithelium,[1] which is so sensitive to septic poisoning, is quite intact in the neighbourhood of the focus, a proof that the infection is at a standstill. In other similar nodules in the retina the *Pneumococci* had entirely disappeared. In the choroidal nodule (shown in Fig. 79) the central mass of cocci is already degenerative, and there is no chemiotactic activity.

These findings seem quite correct, and Fränkel[2] and Peters[3] consider that the small healing choroidal nodules, which can be seen in the choroid in pneumonia patients, are most likely pneumococcal metastases. In the same way the clinical appearance known as retinitis septica (white spots and hæmorrhages in the retina) is possibly due to similar embolic processes; Grunert and Michel,[4] as a matter of fact, found very small inflammatory nodules containing *Streptococci*. The **toxic retinitis** referred to above can be differentiated from these bacterial metastases microscopically, for in the latter exquisite inflammatory foci occur, and in the former we almost invariably find only a degenerative process.

The appearance will also vary according to number, virulence, localization, and susceptibility.

Holmes Spicer[5] has further shown that a furuncle of the skin—that is, a staphylococcal infection—can not only cause suppurative metastases in the eye, but also a mild inflammatory reaction with spontaneous healing. A similar case is reported by Schanz.[6]

In the ciliary body of an eye with a sero-plastic metastatic iridochoroiditis, Sattler found large numbers of Gram-positive cocci (discussion on Axenfeld's communication, Heidel. Conf., 1906). As the inflammation only occurred a few days before death, it was uncertain whether a mild inflammation was passing into a purulent or not.

The so-called **Tenonitis**—the endogenous inflammation in the capsule of Tenon—also belongs, to some extent at least, to the bacterial metastases. With regard to the rare purulent forms, we have some records available: Fuchs,[7] Gasparrini,[8] and Schwartz (*Beitr. z. Aug.*, 1898, p. 34) found *Pneumococci;* Rollet (*Soc. Franç. d'ophth.*, 1902, p. 114) found *Staphylococci;* Zelinski, Neucki, and

[1] *Cf.* Schimamura, *K. M. f. A.*, 1902, i. 229-273.
[2] *A. f. O.*, 1899, xlviii., 2, S. 456.
[3] *K. M. f. A.*, 1901, xxxix., S. 392.
[4] Inaug. Dissert., Tübingen, 1902.
[5] T. O. S., 1906, 1907.
[6] *Z. f. A.*, 1906, Beilageheft (*Festschr. f. Kuhnt*).
[7] *Wien. Klin. Woch.*, 1890, No. 11.
[8] *Ann. di Ottal.*, 1895, xxiii. 6.

Karpinski found the organism of distemper in one case (*Ann. d'Ocul.*, 1896, T. 116, p. 363). In the non-purulent cases the same arguments may be used as were applicable to the cases of benign metastatic ophthalmia. On account of the similarity of this capsule to the structure of a joint, these forms are often attributed to toxic causes. It is undoubted that toxic inflammation of the optic nerve can occur (*cf.* Uhthoff, *K. M. f. A.*, 1900; also Birsch-Hirschfeld, Antonelli, and others).

Our knowledge of the non-purulent, but still bacterial, embolic inflammations of the eye was greatly increased by the experimental investigations of Stock,[1] Selenkowski, and Woyzechowski.[2]

Following Moll's method, Stock injected *Bacillus pyocyaneus* into the veins of rabbits, and produced metastatic uveal inflammations; where in Moll's experiments no clinical observations of the course could be obtained, on account of the speedy death of the animal, in Stock's cases the embolic iritis and disseminated choroiditis healed without leaving any marked changes. This occurred even though very virulent strains were used, the smallest trace of which, injected into the vitreous or anterior chamber, would cause immediate suppuration and panophthalmitis. Stock explained the increased action of the organisms when directly injected over that obtained when metastatically deposited, by the supposition that in the latter case the bacteria, being in the blood, were surrounded by the protective substances before they could develop.

Woyzechowski, with *Pyocyaneus*, *Staphylococci*, and *Streptococci*, of varying virulence, was able to produce metastatic inflammation of varying degree in cats and rabbits, and even very mild affections were thus obtained. When very feeble cultures are used, some localizing irritant is necessary for the determination of a metastatic inflammation (cauterization of the eye, or the introduction into it of a foreign body). (These authors consider that organisms of medium virulence can pass from the vessels into the aqueous, and even into the vitreous, and thence disappear without causing any clinical phenomena.)

When, however, we consider *purulent metastatic ophthalmitis* in man, regarding which naturally there is a far greater amount of material available, we see from the literature that the puerperal form, which formerly was so frequent, is gradually becoming rarer. In this affection, which is almost always caused by the *Streptococcus pyogenes*, the almost invariable result is a panophthalmitis, provided that life is continued long enough; it is rare that a phthisis bulbi occurs without a complete panophthalmitis, and mild benign cases are practically unknown.

A special tendency of the eye to metastatic affection in puerperal septic pyæmia must be inferred, for the equally common surgical pyæmia of the pre-antiseptic days was not nearly so often the cause of metastatic ophthalmia. Perhaps this was due to the freer breaking down of septic thrombi, or the greater prevalence of

[1] *K. M. f. A.*, 1903, xli., i., S. 81 (see here literature of earlier works).
[2] *A. f. A.*, 1903, xlvii., S. 299.

endocarditis, and perhaps also to the circumstance that the *Streptoccoci*, which are almost always the cause of the condition, developed special affinities for the eye in the body altered by the puerperium.

Surgical metastatic ophthalmia, in these days of antisepsis and asepsis, is of far less importance than **metastasis in cryptogenetic** and other **infectious diseases.** In this last group *Pneumococci*, which are seldom the cause of sepsis in puerperal or surgical cases, are the common cause of metastatic ophthalmia ; only rarely are other causes at work (*Bac. typhosus*,[1] *B. coli communis*,[2] *Pneumobacilli*).[3] The *Bac. typhosus* can also cause specific metastases in the eye. Bertozzi observed a case of Vincent's angina with the *Bacillus fusiformis*[4] after measles (*Ann. di Ottal.*, 1907, xxxvi., p. 138). A subacute **endogenous panophthalmitis** can exceptionally occur from **tuberculosis** (De Lietro Vollaro, Munch, Demaria, *K. M. f. A.*, 1905, Beilageheft; *cf.* here the literature). In Demaria's case there was a mixed infection, with a peculiar pseudo-diphtheria bacillus.

Doubts have been cast on Mitvalsky's alleged finding of the *Bacillus typhus exanthematosus* of Kral, as to whether it was not a post-mortem invasion, there being a considerable degree of putrefaction.[5]

The specific organism (influenza bacillus) has been found in cases of **intra-ocular inflammation in influenza** by Tanja, Dinoux, and Casali (*Ann. di Ottal.*, 1907, xxxvi., p. 120). The case of orbital abscess which I have recorded, and which was observed by Siegrist, might perhaps have resulted from one of the accessory sinuses of the nose. Eversbusch (*Staph. aureus*), Lavagna (*Staph. citr. tetrag.*), Despagnet (*Strep.* and *Staph.*), Haushalter, Vilber, and Alfieri (*Pneumoc.*), have demonstated the presence of other organisms in influenza metastases.

From what we know of such cases, a microbic metastasis is the most likely cause of intra-ocular affections of the relatively benign form in *gonorrhœa*[6] and *recurrent fever.* Should the opportunity to examine such cases occur, it should be noted

[1] Gasparrini, *Ann. di Ottal.*, 1895, xxiv. 343 ; Gillet de Grandmont, *Arch. d'Ophth.*, 1892. Panas saw an angioma of the orbit suppurate from infection with the *Bacillus typhosus* (*Festsch. f. Helmholtz*, 1891). Stock's case (*K. M. f. A.*, October, 1906, ii.), in which *Staphylococci* were found, showed that every metastatic ophthalmia occurring during or immediately after a typhoid need not be specifically typhoid.

[2] Desbrières, *Thèse de Paris*, 1893 ; Loëser, *Z. f. A.*, 1902, viii. 24. In this case the orbit was also affected.

[3] Wopfner, *K. M. f. A.*, 1906, xliv., i., p. 386. The ophthalmia occurred in pneumonia after cataract operation.

[4] The work of Lekowicz with reference to these polymorphic, Gram-negative bacilli, which are so common in the mouth, and can be cultivated anaerobically on serum agar, can be found in the *Cent. f. Bakt.*, Orig., 1906, p. 153.

[5] Reviewed by Axenfeld, *A. f. O.*, 1894, xl. 4.

[6] In a globe enucleated two months after the onset of a gonorrhœal metastasis, J. Roosa was unable to find any *Gonococci* (*Post-Graduate*, 1906).

whether the organismal cause has only settled down in the vessels, and has not yet passed out into the exudate. A recurrent fever will probably supply an opportunity for the experimental decision of this question, for Ewetzky[1] has succeeded in inoculating apes with this disease, and observed in them the usual iridochoroiditis as an after-effect.

It has not yet been possible to decide in which class **endogenous rheumatic inflammations** should be put. Bucheron,[2] from the excellent results which he obtained in fifty cases treated with Marmorek's serum, refers the cause to the *Streptococcus*. The variability in their course makes such a conclusion uncertain. It is possible that mild metastases do occur in which the organism mentioned is causal. This view is supported by the experiments, previously mentioned, of Stock, Selenkowski, and Woyzechowski. Poyton and Paine (Ophthalmoscope, October, 1903) obtained from the blood of a patient with rheumatic fever a *Streptococcus*, with which they were able to produce a benign hæmatogenous iridocyclitis in the rabbit.

L. Müller's case of **miliary actinomycosis of the choroid**[3] is an isolated one. In the tuberculoid nodules the Ray-fungus was not to be seen.

We are not justified in classifying the metastatic affections of the eye merely according to the causal organism, as these can cause variable appearances. Certain points of differentiation can, however, be recognized.

The **streptococcal cases**,[4] concerning which there is a large amount of material available, generally develop as an acute suppuration, with panophthalmitis and perforation of the globe. Naturally this is not invariable, for the virulence of the *Streptococcus* varies. Those *Streptococci* which are the cause of septic pyæmia, as a rule, are very pathogenic. A favourable termination is very rarely observed in the eye (Grunert). It is the puerperal cases, mostly due to this organism, which have had a noticeably violent suppurative course. The anatomical and bacteriological examination of such cases shows that, when an embolism has occurred, the *Streptococci* grow at an extraordinary rapid rate in the eye, particularly in the vitreous, but also in the other layers. Large portions of the capillary system of the retina will be completely replaced by bacterial aneurysms; the organisms can grow into the larger vessels, causing rapid atrophy of the tissues of the retina.

[1] *Westnik Oft.*, 1897, xiv., i., p. 51, and *Zent. f. A.*, 1897, p. 111.

[2] *Ann. d'Ocul.*, 1896. *Cf.* Chevallereau, Chaillous, Inter. Confer., Lucerne, 1904, B., p. 310; also Fuchs, *A. f. O.*, 1904, lviii. 391.

[3] *K. M. f. A.*, 1903, xli., i., p. 236.

[4] Vossius, Wagenmann, Pousson, van der Bergh, Despagnet, Mitvalsky, Rancurel, Herrnheiser (three cases)—all puerperal cases; Panas, Axenfeld (five cases). See the further literature: Axenfeld, *A. f. O.*, 1894, xl., 3, p. 24. Wagenmann, Heidel. Congr., 1896, p. 293. v. Michel, *Z. f. A.*, 1902, p. 1; capillary embolisms, just as in the previous case of Michel, were here present. Veillon and Morax, *Ann. d'Ocul.*, 1894, cxi. 341. Chaillous, *K. M. f. A.*, 1905, xliii., i., p. 434. Grunert, 'Retinitis Septica u. Metast.,' 30 Vers., Heidel., 1902, p. 338. Lenhartz, 'Die Septische Erkrankungen' ('Nothnagels Spec. Path. u. Therapie,' 1903, iii. 151). Berger, *A. f. O.*, 1896, p. 494. Liebrecht. *K. M. f. A.*, 1903, xli., ii., p. 124. Onfray, *Arch. d'Ophth.*, 1904, p. 43. Bull, Amer. O. S., 1901, p. 316. Terson, *La Clin. Ophth.*, 1905, p. 167. De Schweinitz, Ophth. Rec., 1904, p. 201, and Sect. of Ophth., Philad., February, 1906. Stock, *K. M. f. A.*, 1906, xliv., ii., p. 431. Pagenstecher, *jun.*, *ibid.*, 1906, ii. 530: a case of *Streptococcus mucosus*. Bivona, *Progr. Oftal.*, April, 1906. Kipp, Amer. Jour. of Ophth., 1906, p. 324. Vogelsang, Inaug. Dissert., Amsterdam, 1907, p. 59. De Schweinitz, Ann. of Ophth., 1907, p. 41 (bilateral puerperal case with recovery).

Appearances, such as those of Fig. 80, are not uncommon in this infection (Wagenmann, Vossius, Axenfeld); in other infective metastases of the retina they have not been observed. The distribution of the *Streptococci* along the vessels remains longer visible than in the case of the other organisms, as the chains keep

FIG. 80.—METASTATIC STREPTOCOCCAL NECROSIS OF THE RETINA. GRAM-WEIGERT STAIN.

Vessels extensively filled with *Streptococci* (violet): capillary bacterial aneurysms. (A bilateral metastatic ophthalmia in a case of carcinoma ventriculi.)

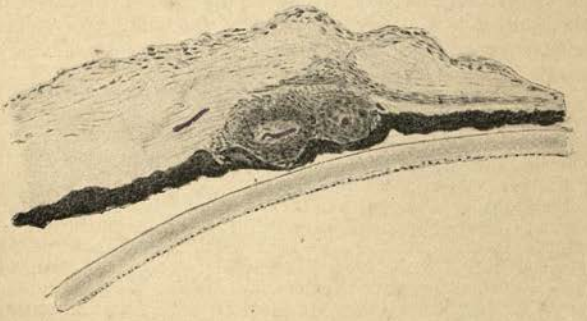

FIG. 81.—COMMENCING METASTATIC STREPTOCOCCAL IRITIS.

Necrosis around the capillaries, which are plugged with cocci.

together longer. In many streptococcal metastases it is possible to find masses of cocci inside the vessels for a longer time than is the case with *Pneumococci*, the latter organism more rapidly passing through the walls of the vessels, and disappearing in all directions.

Necrosis is a very obvious feature of these virulent streptococcal infections, especially in the case of the retina with its terminal vessels. In the uveal tract (iris,

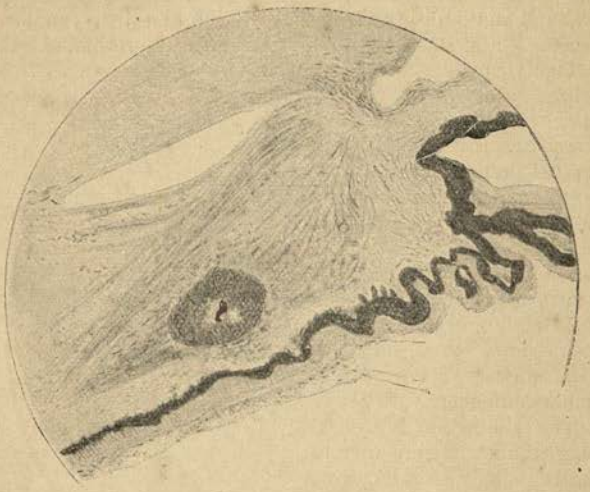

FIG. 82.—METASTATIC CAPILLARY STREPTOCOCCAL EMBOLISMS (VIOLET) IN CILIARY BODY.

In the surrounding tissues necrosis, and commencing infiltration.

FIG. 83.—METASTATIC CHOROIDO-RETINAL ABSCESS, WITH STAPHYLOCOCCUS PYOGENES AUREUS.

Thick zooglœa masses (violet), with surrounding necrosis. (Isolated metastases in the eye in pyelonephritis.)

ciliary body, choroid), with its anastomosing vessels, nodular infiltrations more frequently occur, as is shown in Figs. 81 and 82, sections from the same eye. A

necrotic area is seen close around the capillary bacterial embolism, and around that again is a collection of cells.

On account of the rarity of **staphylococcal** metastases, and the scarcity of bacteriological and anatomical examination of such cases, we cannot give any rules concerning them.[1] Fig. 83 shows a metastatic choroido-retinal abscess, from which I cultivated highly virulent *Staphylococcus pyogenes aureus*. It was a case of a rather localized abscess, with a slight diffuse affection of the retina. In the neighbourhood of the masses of cocci there was a widespread necrosis.

Pneumococcal suppurations less frequently show this concentrated necrotic action. The organisms appear to pass out of the infected vessel into the surrounding tissues at a relatively earlier stage. An intravascular growth, such as takes place with the *Streptococci*, has not been shown to occur with them. On the contrary, it is very rare to find a capillary embolism with *Pneumococci*, such as is shown in Fig. 83, in a commencing retinitis during meningitis. Lenhartz records a similar case.

In the pneumococcal cases there is a free phagocytosis, not only in the mild cases, but also in the severe ones leading to panophthalmitis. This is quite analogous to pneumonia and pneumococcal meningitis. As in the ulcus serpens, the leucocytes and the cocci are intimately mixed; there is no obvious zone where toxic action is intense, and where wandering cells do not occur, as is the case in the staphylococcal abscess shown above. The degree of the leucocytosis is not related to the mildness of the process.

FIG. 84.—CAPILLARY PNEUMOCOCCAL EMBOLISM IN THE RETINA IN A CASE OF SUPPURATIVE CEREBRO-SPINAL MENINGITIS. GRAM-WEIGERT STAIN.

From the material available we conclude that the pneumococcal metastases have a milder course than those due to the other important pyogenic organisms.[2] This is shown by the observation that metastases in the course of a pneumonia rarely lead to panophthalmitis, and also from the previously recorded findings of Axenfeld and Goh (*cf.* Figs. 77 and 78). In very mild cases it is, there

[1] Cases of metastatic staphylococcal ophthalmia in the literature: Herrnheiser, Axenfeld, Mitvalsky (*cf.* collected cases and tables, Axenfeld, *loc. cit.*). Lavagna, *Rif. Med. di Napoli*, x., 94, p. 34. Pooley, Amer. Jour. of Ophth., 1895, p. 130. Liebrecht, *K. M. f. A.*, 1903, xli., ii., p. 124. Holmes Spicer, T. O. S., 1906. Schanz, *Münch. Med. Woch.*, 1906, No. 25. Gerok, *Wurtem. Korr.-Bl.*, 1902. Trokopenko, *Arch. d'Ophth.*, 1901, p. 422. Spicer, T. O. S., 1907.

The case of purulent scleritis recorded by Sachsalber (*Wien. Med. Woch.*, 1898, No. 32) belongs to this class.

[2] Pneumococcal metastases: Fuchs, 'Tenonitis,' *Wien. Klin. Woch.*, 1890, No. 11. Herrnheiser, Axenfeld (four cases), *A. f. O.*, 1894, xl. Axenfeld and Goh, *A. f. O.*, 1897, xliii., S. 147, and Ophth. Kongr., Heidelberg, 1896. Ferri, *Ann. di Ottal.*, 1897,

fore, justifiable to consider this etiology probable, though, of course, it must not be taken as established. There are, however, pneumococcal metastatic suppurations which are so virulent that they rapidly lead to panophthalmitis.

Bietti was therefore right when he attributed a spontaneously healing uveitis, with replacement of an inflammatory detachment of the retina, in a child with broncho-pneumonia, to a pneumococcal metastasis rather than to a purely toxic condition.

Metastatic inflammations in **epidemic cerebro-spinal meningitis** are almost always comparatively mild in their course—that is to say, they rarely go on to complete suppuration. In this affection quite mild abortive metastases are not uncommon.

It can be taken as certain that such cases, in so far as they occur in large epidemics, are due to the *Meningococcus intracellularis* of Weichselbaum (whose occurrence on the conjunctiva has already been considered, p. 216). This has been definitely proved in cases by Wintersteiner,[1] Axenfeld,[2] and Morax.[3] Uhthoff[4] was able to demonstrate cocci in sections, though Heine's[5] investigation of their nature was negative. Anatomical examinations of the earlier cases was also negative. This might well be due to the fact that the *Meningococci* in the infected eye rapidly die out, and when the eye is available for examination they cannot any longer be demonstrated. The case recorded by Zimmermann and Brown-Pusey[6] was only examined after an interval of years.

The early stages of these meningococcal metastases have never yet been examined anatomically and bacteriologically; still, we can conclude that the ophthalmitis develops from metastases, and not by a spread from the meninges through the optic nerve sheath. In the cases examined by Rudnew, Oeller, and Uhthoff, the sheath of the optic nerve was normal, and the retina or the choroid was destroyed by suppuration.

Axenfeld's[7] examinations of cases of *metastatic ophthalmia* in *pneumococcal meningitis*, which sometimes occurs in small epidemics, also assist in deciding this question. In one of his cases a bacterial embolism was demonstrated in the retina, and in another large numbers of *Pneumococci* were found in the purulent retina, while the optic nerve sheath was quite normal. He was also able to show—and this

---

xxvi. 306. Alfieri, *Arch. di Ottal.*, 1897, iv. 328. Malfi, *Arch. di Ottal.*, 1899, vii. 125. Morax, *Soc. Franç. d'Ophth.*, 1898. Haushalter, *Gaz. Hebdom.*, July 8, 1895. Ahlstroem, *Ann. d'Ocul.*, 1897. Schwarz, *Deutschmann's Beiträge z. Aug.*, 1898, S. 34. Silcock, T. O. S., 1900, p. 112. Dhuyelle, *Thèse de Paris*, 1900, S. 25. Bull, Amer. Ophth. Soc., 1901. S. 316. Gisselbrecht, *Thèse de Nancy*, 1902. Bovier-Lapierre, *Thèse de Lyon*, 1902. Bietti, *K. M. f. A.*, 1903 (*Festschr. f. Manz*, S. 51). Petit, *Ann. d'Ocul.*, 1901, cxxvi. 186. Purtscher, *Zent. f. Prakt. Aug.*, September, 1902. Römer, *K. M. f. A.*, 1902, xl., 1, 320. Casali, XVI. Kongr. Ital. Ottal., *ibid.*, 1903, xli., i., S. 338, and *Ann. di Ottal.* Weeks, Ophth. Record, 1903, S. 61. Wendt, 'Doppels. Metast. Ophth. bei einem Kind,' Inaug. Dissert., Jena, 1901. Zobel, *Zeit. f. A.*, 1904, xi., S. 32. Morax, *Ann. d'Ocul.*, 1904, cxxxii., S. 409. Lenhartz, 'Die Septischen Erkrankungen' ('Nothnagels Spec. Path. und Therapie,' 1903, Bd. iii., p. 15). Vogelsang, Inaug. Dissert., Amsterdam, 1907, p. 71.

[1] *Wien. Klin. Woch.*, 1904, p. 996.

[2] Remarks on Haglund's paper, *K. M. f. A.*, 1900. Gram-negative *Diplococci* were recently found in a very mild case of iris metastasis; these may have been *Meningococci* (there was no reason to consider that they were *Gonococci*). Cultures were unsuccessful.

[3] *Soc. d'Ophth. de Paris*, October, 1905; also Hanke, *Wien. Ophth. Ges.*, April 17, 1907, and Abt, *Soc. d'Ophth. de Paris*, 1902, p. 81.

[4] *Ver. d'Ophth. Ges. Heidel.*, 1905, p. 102.

[5] *Berl. Klin. Woch.*, 1905, No. 25.

[6] Annals of Ophth., 1903, xii. 446.

[7] *Monatsschr. f. Augenh. u. Psychiatrie*, 1897, i.

was later confirmed by Lietro-Vollaro[1]—that meningitis organisms generally were unable to pass forward in the optic sheath, as their passage was early blocked by the exudation into the optic canal.

And even in those rare cases where the presence of *Pneumococci* could be demonstrated in the sheath, their transference from thence into the interior of the eye could not be established. De Lietro-Vollaro has shown the same to be the case in a traumatic suppurative meningitis, where the *Streptococci* could be found in the sheath of the nerve, but had not passed from there into the globe.

We can conclude that the same is true in meningococcal meningitis and its complications in the eye. Till now, at least, there is no certain case known of infection of the interior of the eye from the optic sheath.[2]

The important question, *In which part of the eye do the bacterial metastases occur?* can only be answered by microscopical examination of serial sections of the early stages, in which either the organisms can be seen inside the vessels, or a particular part of the eye can be found intensely or exclusively affected. At any later stage the point of origin is lost in the suppurating mass, and the exudate invades other parts of the eye. In the stage of panophthalmitis no such determination is possible; indeed, in many cases it is impossible even at an early stage.

Many infections spread rapidly into the vitreous. The resulting exudate may so carry the bacteria into the interior that, when we examine the eye, we find the vitreous almost or exclusively filled with bacteria, which then and there develop into dense masses. Pure cultures are often found in the anterior part behind the lens. Transference into the vitreous takes place with extreme rapidity when the adjoining retina is infected, and those cases which Straub and Vogelsang[3] called 'metastatic hyalitis' are chiefly the results of bacterial metastatic retinitis.

The favourable cases for early examination have shown that the *retina* was usually the primary site of infection; in many cases it alone was infected, and in others it was so along with other parts of the eye. This is the case to a special extent, though not quite invariably, for those common cases (one-third of all observed) in which a metastasis occurred in both eyes. In the one-sided cases, however, the *uvea* was generally the site of an embolic infection.

In the material which I have collected and examined this preference for the retina was very marked in the double-sided cases. I have illustrated this by sections from two similarly (Gram-Weigert) stained globes in a case of double metastatic ophthalmia, where bacterial necrosis (streptococcal) is very clearly seen.

[1] *K. M. f. A.*, 1903, Beilageheft (*Festschrift f. Manz*).

[2] The cases which are so considered by Saltini (*loc. cit.*), Silcock, Treacher Collins (T. O. S., 1900, xx. 121), and others, are capable of another interpretation.

[3] Vogelsang, Dissertation, Amsterdam, 1907, p. 58.

We must not make any rigid division of the cases, as the distribution of the septic material is not according to any absolute rule.

In forming any opinion, from microscopical appearances, as to endogenous infections, it must be remembered that a further post-mortem increase is possible in the bacteria lying in the vessels, and also in those in the metastatic nodules. According to Canon, Lenhartz, and others, the number of the bacteria in the blood increases in septic pyæmia just before death. After death the numbers in the case of some bacteria may be enormous. Among the pyogenic ones the *Streptococci* may so increase that the vessels are quite filled, and we have the appearance of an injection preparation. The post-mortem nature of these changes is shown by the fact that the intravascular masses do not correspond to any inflammatory or degenerative changes in the tissues around. This growth of bacteria is freest in the

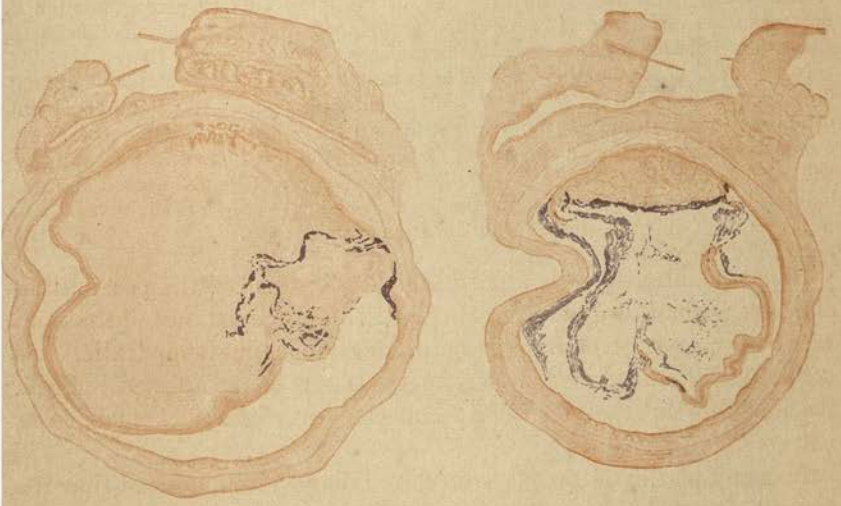

FIGS. 85 AND 86.—METASTATIC STREPTOCOCCAL NECROSIS OF BOTH RETINÆ IN A FATAL CASE OF SEPTIC PYÆMIA.

Large numbers of *Streptococci* lie in the subretinal space on the coroid, which itself is free from metastases (cocci are violet).

veins, which are well known to contain the greatest amount of the blood after death. In the case of the larger, more compact masses of cocci in otherwise healthy veins, we can at once exclude a metastasis having occurred here just before death, and not having led to any inflammatory reaction, for such a mass would have stuck in the capillaries.

Herrnheiser and Axenfeld have recorded cases showing very free post-mortem growth of bacteria in the eye, and have emphasized the difference between such conditions and the true metastases.

The human retina is not very rich in vessels, and its special affinity for the deposition of organisms raises the question, What causes are at work in producing this state of affairs?

It is certain that we do not have to do with embolisms of the larger branches, for the large embolic masses would also settle down in the other branches of the carotid. The eye metastases, however, are often the only ones in the whole internal carotid region. The deposition takes place more in the finest capillaries, and is due to infectious material in the blood in the finest state of division.

As the question appears to be one of the embolic plugging of the capillaries, we must consider their calibre; this factor alone cannot be the cause of their predilection, as Sattler's capillaries in the uvea are just as fine. We must conclude that septic conditions in the blood first cause toxic changes in the retinal vessels, which react freely to many changes in the state of the body (*e.g.*, retinitis albuminurica). Fatty changes occur in the endothelium (Ponfick); hyaline and laminated clotting results, leading to stasis, and thus the deposition of the bacteria from the circulation. As there is a tendency in the retina to hæmorrhages, it is obvious how, with a toxic-septic bleeding taking place, the organisms can pass into the tissues.

In a child dead from sepsis I was able to microscopically demonstrate a retinal hæmorrhage filled with *Streptococci;* this would have formed the commencement of a metastatic inflammation from the extravasation of blood containing cocci.

All previously existing disturbances of the circulation, including traumatisms, will act as localizing agents in the eye (see the researches of Panas[1] quoted above).

Individual variations in the susceptibility are possible, as also are slight variations in the action of different strains of the same bacterium.

In individual cases it is difficult to decide which of the possibilities discussed is the cause of any particular isolated metastatic ophthalmia, where in one eye, or perhaps in both, an endogenous suppuration has occurred, without any other part of the body being affected. From the literature up to 1894 I have collected over thirty of such cases (*loc. cit.*).

In many of this latter class of case I have often noticed that the general condition is very little disturbed; perhaps it is quite normal at the time of the ophthalmitis, so that the case appears to be one of 'spontaneous panophthalmia.'

The predilection of the non-purulent endogenous inflammations for the eye is shown to a far higher degree. In these we are often unable to demonstrate any other lesion in the body. The extent to which these may be bacterial metastases has already been discussed on p. 364.

[1] According to Leber and Krahnstoewer, necroses, followed by intense inflammatory symptoms and phthisis bulbi can lead to the localization of circulating bacteria; such destruction of tissue occurs in an intra-ocular tumour, not uncommonly in conjunction with vascular thrombosis. These endogenous infections will explain why sympathetic ophthalmia is occasionally associated with such affections. We have no cultural proof of this; the purely macroscopical findings which Deutschmann records in these eyes are not absolutely positive, and, moreover, they have no relation to sympathetic ophthalmia, whose cause is not yet demonstrable by the microscope (*cf.* literature in Schottelius's Dissertation, Freiburg, 1904; also Nesse, *K. M. f. A.*, December, 1906, xliv.).

It is quite possible that the localizing influence varies for different organisms, and that the circulating poison, as well as the organisms themselves, may have a special affinity for special organs, and be able to find receptors there. A striking example of the fact that the kind of bacteria and the special affinities, unknown to us in detail, play a part is shown by the fact that the preference of the retina previously discussed, does not exist for endogenous infection of the eye with tuberculosis.

Isolated tubercle of the retina is extremely rare; tubercle of the uvea, on the other hand, is quite common. The tubercles can only be due to 'affinities,' for the free anastomoses of the capillaries of the uvea can offer no specially strong mechanical obstruction to the passage of these bacilli. Often, perhaps, these metastases are not due to an embolic plugging with infected material, but to a retarding of single bacteria, which, from a purely mechanical point of view, could well pass through the lumen, yet are prevented by some special condition or receptor.

In rabbits no predilection of the vascular part of the retina for circulating organisms could be shown to exist. With *Pyocyaneus* Stock always obtained metastases in the uvea, never in the retina, using pathogenic hefæ (*Hefa klein*, *Hefa busse*). Stock also obtained in my laboratory spontaneously healing metastatic inflammations in the uvea and in the retina; this never occurred with tubercle bacilli (*K. M. f. A.*, 1907, ii.). As the hefæ have a relatively large diameter, the narrowness of the retinal capillaries may influence their fixation there. Selenkowski and Woyzechowski (*vide infra*) also speak of retinal metastases; it is not clear, however, if they were demonstrated microscopically.

Korotkow similarly reports that in his experiments on endogenous wound infections (*cf.* p. 104) the metastases always occurred in the uvea (*Wratsch*, 1903, No. 50; *Ann. d'Ocul.*, 1904, cxxxii., p. 152). Perhaps in other animals it would again be different—*e.g.*, in cats.[1]

As a rule, metastatic inflammation cannot be produced in rabbits by the subcutaneous injection of the common pyogenic or septic organisms.[2] This must not be taken to mean that by this mode of infection the bacteria cannot pass into the blood and thus reach the eye, for they can pass by way of the subcutaneous tissues just as

[1] The cases of Story and Stevenson belong to this exceptional class.

[2] After subcutaneous injection of *Bacillus coli*, Panas obtained metastatic ophthalmia in cases where the eye had previously been contused. Weber (*Deutsche Klinik*, 1864, No. 48 and Marchand (*Berl. Klin. Woch.*, 1903; Marburg Rep., June 3, 1893) obtained metastatic suppuration of the eye by infecting the subcutaneous tissues of cats, especially when capsulated bacilli of the pneumobacillary group were used.

in those cases in which Picot and Römer inoculated one eye. Römer was able to show that in the second eye the bacteria in question could be found in large numbers, and in a comparatively short time, but that is far from being a clinical demonstration of an inflammation or metastasis. After an inoculation of one eye with tetragenus, a metastatic inflammation of the other, resulting in healing, only occurred in one of Picot's cases. Such, however, can be obtained with certainty if we inject the organisms into the blood-stream, especially if we inject into the jugular vein.

Péchin and Phasalix (*Soc. de Biol.*, October, 1898; *Ann. d'Ocul.*, cxx., p. 387) obtained a double-sided metastatic ophthalmia in a dog after the injection of the bacilli of rabbit's septicæmia into the jugular vein. Lagrange (*Soc. Franç. d'Oph.*, 1898, p. 92) obtained a tuberculous iritis by injecting tubercle bacilli into the carotid artery. A large number of such experiments have been performed by Stock.

The predilection of the uvea of the rabbit, which seems to be exclusive for many kinds of organisms, especially the tubercle bacillus, is a point of great interest. It is also remarkable how often Stock observed that these lesions healed up in spite of the use of very virulent organisms. Still more remarkable was the fact that nodules in the choroid were milder, and healed more rapidly and completely than inflammations in the ciliary body and iris. This shows that the healing of such endogenous inflammations does not infer an infection with attenuated organisms, but that even highly virulent organisms can be made innocuous, not so much by their being killed out as by their encapsulation in scar tissue. In any case they can remain in the tissues in a state of great virulence long after clinical healing has occurred. An interesting experiment in this connexion, and also an important one regarding the healing in and latency of virulent bacilli in the eye, is given by Stock, who showed that the transference of a piece of iris infected with hæmatogenous tuberculosis, appearing clinically to be completely healed, would produce a severe tuberculosis in the eye of another animal. This also explains how these endogenous uveal affections (as also those of the sclera and cornea), often due to tuberculosis in man, so freely recur, for the bacilli become encapsuled in the tissues, and on a suitable occasion again become active.[1]

Stock's experiments certainly have shown that tuberculosis in the rabbit, when it affects the blood-stream, can produce an extraordinary

[1] The encapsulation and prolonged latency of the pyogenic organisms has not yet been proved for the eye; it cannot be excluded, as it is accepted as occurring in other organs by the surgeons.

variety of chronic inflammations. This is a distinct confirmation of the teaching of von Michel, based on clinical observation as to the cause of chronic uveitis in man.

The great majority of the cases of chronic uveitis are therefore not likely to be purely toxic. On the other hand, these experiments tend to the idea of the metastatic causation of **sympathetic ophthalmia.** This view was first brought forward by Berlin, later by Panas, Moll, Picot, and in a modified way by Schmidt-Rimpler, and, though freely controverted, has much in its favour.

The Leber-Deutschmann hypothesis of transference in continuity, particularly through the sheath of the optic nerve, can no longer be considered as proven; its alleged demonstration by cultures, microscopy, and experiment will not stand criticism.

On the other hand, the experiments of Picot[1] and Römer[2] show that the transference from an eye experimentally infected either does not occur, or does so with very great difficulty by way of the optic nerve or its sheath, but that it can occur with ease and regularity by way of the circulating blood. This was the case with various bacteria. Römer demonstrated it for many saprophytes, and also for bacteria which could be recognized by their spores for a relatively long time. *Trypanosomata* (Protozoa) also produce a rapid general infection from the eye (Römer, A. Leber, Stargardt). Experiment is in favour of the metastatic hypothesis.

Picot insists that this passage of organisms from an experimentally infected eye into the blood is an important factor in the pathogenesis of sympathetic ophthalmia, the more so as he obtained a metastatic inflammation in the other eye in a tetragenus experiment.

The experiments which Römer has recently published show with what ease and rapidity the organisms can pass from an infected rabbit's eye into the blood, even in cases where the refracting media alone are infected without injury to a single vessel. Römer did not limit himself to the clinical demonstration of severe fatal general infection, but examined the blood and also the other eye at varying times after the infection of the first one. The inoculated organisms could be demonstrated after a few hours in the second eye. Römer states that they are freely found in the blood of the uvea.

The question then arises, To what extent can these facts be applied to man? The clinical fact, that a fatal general infection extremely rarely results from a suppurating eye, even in the severest panophthalmitis[3] (due to the most virulent organisms), seems to show that

[1] *Arch. d'Oph.*, 1898, xviii. 341.

[2] *Ophth. Ges.*, Heidel., 1903, p. 40; *A. f. A.*, 1906, lv. 4, and 1906, lvi. 1.

[3] Wurdemann and Becker (*Ophthalmology*, 1906) describe such a case, giving cultures. Fatal general infection occurred in a case of Basedow's disease from a streptococcal panophthalmitis caused by the lagophthalmos.

the conditions are different in man. Severe general sepsis is very rare. The difference may be due to the fact that, as in the experiments of Picot and Römer, large numbers of highly virulent organisms introduced into the aqueous or the vitreous could pass into the blood or lymph channels before any obstruction was interposed. On the other hand, when a wound infection develops in an eye, the number of organisms introduced is less, and an obliteration of the passages out of the eye can be produced by cellular and fibrinous deposits, the powers of resistance being greatly increased.

Cases are very rare in which, after a bulbar infection, we find a meningitis resulting by spread in continuity (*cf.* p. 348, and the literature by Lapersonne, Enslin, and Kuwahara).

We do not, however, claim, even in man, that organisms do not pass into the blood during the course of an eye infection. Slight general feverish symptoms are not uncommon. Special investigation is necessary to show whether, and to what extent, a slight general infection does occur in such cases in man. Micro-organisms have never yet been demonstrated in the blood in panophthalmitis; and even if this were so with the pyogenic bacteria to a limited extent merely, it need not necessarily be so with other organisms.

While Schmidt-Rimpler, Panas, Moll, and Bach consider the infection of the second eye to be brought about by organisms already present in the body, being localized by the irritation or the trauma reflexly affecting the other eye, the older opinion (Leber, Schirmer, etc.) has lately been championed by Römer that the presumptive causal agent enters the injured eye from without and spreads from there.

If the rare cases of sympathetic ophthalmia without any perforating wound are to be brought into line, an endogenous infection of the first affected eye must be presumed.

Schmidt-Rimpler attempted to explain the metastatic occurrence of sympathetic ophthalmia, without noticeable general disturbance or metastatic inflammation in other organs, by attributing to the other eye a preparatory disposition, due to a sympathetic irritation from nervous influence. Mooren, Rumpf, and Bach reported that they obtained an increase in the albuminous contents of the aqueous in one eye of the rabbit by experimentally irritating the other. Wessely, Tornabene, and Stock[1] could not confirm this. By more refined methods, the hæmolysin reaction, Römer[2] showed that there was really no change in the secretion to be produced thus, and he insisted that the exclusive affection of the other eye was due to the fact that the organisms were exclusively pathogenic for the eye. In the section on 'Wound Infection,' we have already discussed the question as to the occurrence of organisms which under other circumstances act as saprophytes (see p. 191; *cf.* the work of Ulbrich).

The alleged experimental proof of the localizing action of a sympathetic irritation must therefore be put aside. It should be noted that

[1] *K. M. f. A.*, 1903, xli., i., pp. 81, 228 (literature here).
[2] *A. f. O.*, 1903, lvi. 3.

in the experimental animals no condition can be produced analogous to the sympathetic irritation of man (photophobia, contraction of the pupil, and vasomotor irritation). The localizing action for circulating bacteria of such a vasomotor irritation as occurs in man is by no means disproved; on the contrary, from analogies in general pathology, it must be considered as quite possible. It could conceivably occur even if anomalies of secretion did not take place in sympathetic irritation. This is important with reference to the discussion on deep-seated bilateral endogenous inflammations of the globe (especially keratitis parenchymatosa) following a unilateral trauma. It is claimed by many that Römer's experiments have finally excluded any connexion between them. Such is certainly not the case; the question is one of great difficulty.

I do not, however, consider that the modified theory of ciliary nerve influence is proved. The objection to it is more that there are so many cases of sympathetic ophthalmia which are not preceded by the symptom-complex of sympathetic irritation than that the experiments quoted have proved it invalid. They have only taken away from it one of its presumed experimental supports.

Golowin[1] and Santucci[2] state that the destruction of certain cell groups in the wounded eye, more especially in the ciliary body, cause the formation of cytotoxins in the blood, which can act upon analogous parts of the other eye. This is, of course, no explanation of sympathetic ophthalmia as a whole, as a definite progressive inflammation, often going on after enucleation of the first eye to considerable destruction, and obviously a true infection of the second eye (Pusey, *A. f. O.*, xxxii. 334). The view advanced by Bellarminow and Selenkowski,[3] and supported by experiments, that sympathetic inflammation is exclusively a transference of toxins, seeing that the poison of the *Staphylococcus aureus*, when injected into the vitreous or the optic nerve, can produce inflammation on the other side, is not conclusive, as this poison certainly has nothing to do with sympathetic ophthalmia. Their experiments also require confirmation.

Stock[4] was absolutely unable to confirm the similar statement by Gasparrini[5] that an inflammation on the other side could be produced by the injection of diphtheria toxin.

The whole clinical course of sympathetic inflammation is against such a purely toxic origin; at most the invariably benign papillo-retinitis sympathetica, which heals promptly on the enucleation of the first eye, may suggest such an origin. It would be better to reserve judgment even on this point till the etiology of the whole condition is better understood. Stock's experiments have shown that hæmatogenous tubercles in the choroid heal more rapidly and completely than similar ones in the anterior part of the uvea, and it is not unlikely that a corresponding state of affairs may obtain in sympathetic ophthalmia.

[1] *Ann. d'Ocul.*, 1905, cxxxiii. 233. *Wratsch*, 1905, No. 22.
[2] *La Clin. Oculista*, 1906, vii. 2685.
[3] *Cf.* ref. *K. M. f. A.*, 1900, Beilag., and *A. f. A.*, 1901, p. 1, and 1902, p. 55.
[4] *K. M. f. A.*, 1903, i., p. 81.
[5] *Ann. di Ottal.*, 1901, p. 285.

Similarly, we cannot accept the old hypothesis of nerve irritation, even in its new form, as given by Theobald (Ophth. Rec., 1904, p. 329), making sympathetic ophthalmia non-infectious, like herpes zoster. Quite frequently no such irritation of any sensory nerve is present at the commencement of a sympathetic ophthalmia.

Findings in Sympathetic Ophthalmia.

On all sides it is admitted that sympathetic ophthalmia is an infectious disease which arises by the inoculation of bacteria (Leber). It is also agreed that the pyogenic organisms on which Deutschmann laid special stress have no relation to sympathetic ophthalmia. In the great majority of cases they have not been found when material has been taken with aseptic precautions from either the exciting or the sympathizing eye; and in those cases where cultures of these organisms were obtained either a contamination or a secondary infection occurred. Deutschmann's finding of bacilli and cocci in certain exciting[1] eyes, which he examined microscopically, and also once in a sympathizing eye, as well as in the nerve sheaths, is not convincing. Such a purely microscopical proof can be confused by the presence of mast-cell granules, nuclear fragments, etc. It must be considered that with our present methods no certain demonstration of micro-organisms which could have an etiological significance has succeeded in anatomical preparations, in experiment on animals, or in cultures. I have often attempted this, but always in vain. The relation which is sometimes claimed to exist between tuberculosis and sympathetic ophthalmia is unlikely, and can be laid aside.[2]

Raehlmann[3] records finding bacilli and very small moving particles with the ultramicroscope; this cannot be taken to have any general importance, as bacilli of that size would have been seen with the ordinary immersion lenses, and in every attempt made by others this has not been the case. It is much more likely that these granular bodies were something quite secondary.

Following up the idea that sympathetic ophthalmia was a metastatis, Zur Nedden[4] injected the blood of sympathetic patients into the vitreous of the rabbit to see whether an inflammation would be caused, and reports that such did occur to a greater degree than with the blood of normal persons. The re-inoculation of the vitreous of other animals with the vitreous of the infected animal produced inflammation, and from the vitreous of the fourth inoculated generation a peculiar variety of the pseudo-diphtheria bacillus was grown. It was very refractory to staining; with an alcoholic fuchsin solution 1 in 10, after twenty minutes small rods could be seen. These were more easily seen by the Gram stain when the alcohol was carefully used; their cultivation was difficult, and only succeeded when a considerable amount of vitreous was added to rabbit's blood-serum-bouillon. The organisms could be gradually accustomed to ascites media and Löffler's serum, and their form became more and more like that of pseudo-diphtheria bacilli; they grew more slowly as grey, slightly granular colonies. They had a very great resisting power against heat, standing 60° C. for three-quarters of an hour without being killed. When injected subcutaneously or into the peritoneum, they caused localized inflammatory nodules, which resolved spontaneously. Even when in small quantity in the vitreous they caused an insidious inflammation, leading to shrinking, very similar to the inflammation produced when the organisms were injected into the blood. When large quantities were injected into the carotid, metastatic

[1] The word 'exciting' is used as translation of *Sympathizierend*, the original eye, and 'sympathetic' is used as translation of *Sympatisch*, the secondarily affected eye (A. M.).

[2] *Cf. K. M. f. A.*, 1900, Beilag., p. 107; 1900, Bd. xxxviii., p. 578; and Brons *Münch. Med. Woch.*, 1906, p. 1938.

[3] *Deutsche Med. Woch.*, 1904.

[4] *A. f. O.*, 1905, lxii. 2.

inflammation, healing after some weeks, was produced in the eye. The animals in general remained healthy.

Zur Nedden himself does not claim that there is any certain proof of the significance of this bacillus. If we concede the possibility—and the question is still open—that various organisms can produce a sympathetic ophthalmia, then this organism can quite well be one of them.

It can be taken as certain that this bacillus is not constant in sympathetic ophthalmia. Brons was unable to find it in three fresh cases in my clinic, in spite of the most careful repetition of Zur Nedden's tests. Neither did we obtain any benefit from the serum treatment in sympathetic ophthalmia (injection of the serum of a patient suffering from sympathetic ophthalmia), although we obtained large quantities of blood at varying times. We could not convince ourselves that the blood of sympathetic patients had any more severe effect on the eye of a rabbit than the blood of a normal person.

Zur Nedden's results show that here and there organisms of the group of the pseudo-diphtheria bacillus occur, and can multiply and cause insidious inflammation in the vitreous, not only when directly injected, but also by infection of the blood-stream. These bacilli, when in the blood-stream, are unable to produce any demonstrable changes in other parts of the body, a characteristic also possessed by the still undiscovered cause of sympathetic ophthalmia (Römer and Ulbrich; *cf.* the literature of 'Saprophytic Inoculation' in section 'Wound Infection,' p. 191).

It should be noted in this connexion that Schirmer produced an insidious irido-cyclitis, without any organisms being demonstrable, by the introduction of pieces of tissue from sympathetic exciting eyes into the vitreous of rabbits (Heidel. Congr., 1900, p. 189). Römer produced an irido-cyclitis (*ibid.*, 1903, p. 38) with the virus of foot-and-mouth disease and chicken-pox. Römer produced in apes and in young pigs an iridocyclitis, followed by a general infection. He considered that he had here an experimental analogy with the still unknown virus of sympathetic ophthalmia, though the manner of the transference and spread of these infections could not be followed.

CHAPTER XI

THE ORBIT

SEEING that the infectious diseases of the orbit are, with rare exceptions, due to a spread from neighbouring organs—only very rarely are they metastatic—their bacteriology will agree with that of the surrounding parts.

The bacteriology of the orbit corresponds in a very marked degree with that of the accessory sinuses of the nose.[1]

In this connexion we only need to indicate the careful investigations and the collected literature in the work of Stanculéanu and Baupp on the bacteriology of the empyemata of the sinuses (Intern. Med. Congr., Paris, 1903, sec. of Ophth., p. 103), and the 'Handbuch der Erkrankungen der Nase,' by Zarniko (second edition, 1905, Karger, Berlin). The first authors state that in the fœtid, stinking empyemata, which are especially due to carious teeth, along with pyogenic organisms, anaerobic putrefactive organisms were found (according to Veillon and Zuber *B. perfringens*, *B. ramosus*, *B. serpens*, *B. fragilis*, *St. parvulus*, to which Zarniko adds *B. fluor. putr.*, and *B. pyog. fœt.*). These putrid inflammations mostly spread from the maxillary antrum, and originate from the teeth, whose importance in orbital inflammations was first pointed out by Pagenstecher. In the simple purulent or muco-purulent empyemata, which are most commonly found in the other sinuses, the pyogenic organisms alone are found, and according to Stanculéanu and Baupp, in the following order of frequency:

1. *Pneumococci.*
2. „ with *Streptococci.*
3. „ with *Pneumobacilli* (Friedländer).
4. *Streptococci* alone.
5. *Staphylococci* alone.

The actual frequency might vary in other lists; the overwhelming importance of the *Pneumococci* is established from large collections of material. To this list must be added the rare cases of influenza bacilli, diphtheria bacilli, and *Meningococci* being found in the empyema, of which they were the cause (*cf.* Zarniko's literature; also Eversbusch, second edition Graefe-Saemisch, 1903, and the collected literature by Brons in the 'Ergebnisse' Lubarsch-Ostertag, 1900-1905). Pseudo-diphtheria bacilli have been often found, but are of uncertain significance.

[1] As Fuchs first showed, the lacrymal sac, being in close relation to the sinuses, is occasionally the source of orbital complications (see the literature by Mouzels, *Thèse de Bordeaux*, 1903; by True, *Ann. d'Ocul.*, 1900, p. 94; and Antonelli, *Ophth. Klinik*, 1900, No. 7). It is doubtful whether or not in many of these cases the sphenoidal sinus was not also affected.

Seeing that the empyemata of the sinuses often occur in the course, or as sequelæ, of infectious diseases, the orbital complications which they cause were formerly considered as metastatic, the connexion between them and the nasal condition not being known. We now know that the case is different.

It should be noted that the original sinusitis can heal by evacuation into the nose, while the orbital condition to which it gives rise is progressive, as it cannot find any drainage. At the time that the orbital condition is under treatment the original sinusitis may be healed. I have been able to demonstrate such a condition by exploratory trephining in the case of an orbital suppuration connected with an influenzal sinusitis.[1] We can only consider an orbital inflammation as metastatic when the evidence is conclusive on that point.

It is therefore not to be wondered at that the orbital inflammations, so far as their bacteriology is given in the literature, agree in all bacteriological essentials with the sinus affections. It is hardly necessary to go through these singly.

Pneumococci have been found by Hirsch,[2] Kuhnt,[3] Guignot-Cabannes,[4] Faure (*Thèse de Bordeaux*, 1903), De Lapersonne,[5] Weiss,[6] Lefrançois,[7] Axenfeld,[8] Vossius,[9] Thomson.[10]

Streptococci, in part mixed with *Staphylococci*, by Berger, Reis, Panas,[11] Trousseau, Axenfeld, Brand, Hirsch, Thomson (*loc. cit.*), Villard (*Arch. d'Ophth.*, 1895, p. 477).

Staphylococci alone by Pergens, Axenfeld, De Lapersonne, Brand, Thomson, Orlandini,[12] Terson (*Rec. d'Ophth.*, 1894).

Influenza bacilli by Siegrist,[13] Axenfeld and Brand.[14]

B. fusiformis, Morax (*Soc. Franç. d'Ophth.*, 1905, p. 385).

The empyemata and the orbital inflammations which occur in pneumonia are not always due to the *Pneumococcus*, nor those in influenza to the influenza bacillus. On the contrary, the bacteriological findings vary in one and the same originating disease. Organisms are previously present in the nose (perhaps, too, in the sinuses), and these can act pathogenically when the lowered general condition gives them opportunity.

De Lapersonne considered that cases caused by the *Staphylococcus* are relatively milder than those suppurations which are due to *Pneumococci*, *Streptococci*, or Friedländer's *Pneumobacillus*.

Fage's opinion (*Ann. d'Ocul.*, 1895, p. 341) that ozæna bacilli from the nose or infected nasal sinuses can reach the eye and there set up an iritis is quite unproved. It is certainly not impossible that a general infection has so occurred, and that the

[1] *Deutsche Med. Woch.*, 1902, S. 713.
[2] *Prager Med. Woch.*, 1894.
[3] 'Die Erkrankungen der Stirnhöhle,' 1895 (F. Bergmann).
[4] 'Pneumococcies Oculaires,' *Thèse de Bordeaux*, 1905.
[5] 'Les Complic. Orbit. des Sinusites,' Congrès Franç. d'Ophth., 1903.
[6] *Z. f. A.*, 1904, x., S. 16 and 91.
[7] *Annales d'Ocul.*, 1899 S. 21.
[8] *Deutsche Med. Woch.*, 1902, S. 713.
[9] *Z. f. A.*, 1900, iv., S. 16.
[10] B. M. J., September, 1906.
[11] *Arch. d'Ophth.*, 1895, xv., S. 129
[12] 'Jahresber.,' Michel-Nagel, 1904, S. 698.
[13] *A. f. O.*, 1894, xl., 3 and 4, 'Anmerkung.'
[14] Inaug. Dissert., Freiburg, 1902.

eye was infected metastatically. But such is unlikely. Though a transference of toxins from the nose or nasal sinuses into the eye has so often been put forward, such has never been proved beyond all doubt to have occurred in any single case. The occurrence of bulbar inflammations in these (nasal) affections can quite as well be explained by a localizing and predisposing reflex circulatory disturbance, due to the neighbouring affection, while the true exciting cause of the iritis, scleritis, etc., is perhaps something quite apart from the nose.

The rare cases of orbital cellulitis in infants cannot be associated to the same extent with affections of the sinuses, as the sinuses are either absent or undeveloped up to the eighth year. In the case of infants during the first few weeks[1] infected birth wounds should be considered. In older children[2] lid infections are possible causes by metastasis. It is only after the sixth year that a nasal etiology becomes important. The youngest person whom I have seen with an orbital abscess which certainly originated from a sinus (sphenoidal containing *Streptococci*) was nine years old.

In encapsulated empyemata the organisms die out with varying rapidity. The contents of a mucocele, according to my experience, are mostly sterile. Such an encapsulation is rare in the orbit. Still, a case is reported by Hirsch[3] in which the pus was sterile.

It is interesting that orbital infections can occasionally lead merely to an infiltration. These cases, which are often confused with tumours, can resolve without suppuration. This is the condition present in some at least of those peculiar cases of exophthalmos, which disappear after resection of the external wall of the orbit, though no pus or tumour has been found. I have had a case in which, on opening the orbit by a Krönlein, the orbital tissues were found to be densely infiltrated, and only after eight days the pus was discharged (*Staph. aureus*).[4] Many of the transient orbital swellings associated with sinus empyemata must be considered to be collateral toxic inflammatory œdemas.

The occurrence of metastatic orbital inflammations cannot, however, be disputed.[5] Two cases of orbital suppuration recorded by Pergens[6] can be considered, with some probability, to have been metastatic

[1] Dujardin, *Jour. des Sciences Méd. de Lille*, 1888, p. 169. Leplat, *Soc. Belge d'Ophth.*, November, 1897 (*Staphylococci*). Orlandini, *La Clin. Ocul.*, 1904, p. 1173.

[2] Cabannes and Lamarque, *Thèse de Faure*, Bordeaux, 1903 (two years old, *Pneumococci*). Trousseau, *Ann. d'Ocul.*, 1898, p. 343 (nine months old, *Streptococci* and *Staphylococci*). Müller, Inaug. Dissert., Wurzburg, 1905, p. 29.

[3] *Prager Med. Woch.*, 1894, No. 14. In seven cases of orbital cellulitis there was only one which was probably metastatic.

[4] *Cf.* Gruber's Dissert., Freiburg, 1902.

[5] *Cf.* the dissertation of Schwend, Basel, 1899; also a probable case by Axenfeld, *A. f. O.*, 1894, xl. 127; also Müller, Dissert., Wurzburg, 1905, p. 35 (*Streptococci*).

[6] *Ann. d'Ocul.*, cxiv. 278.

(one with Friedländer's bacillus, the other with *Staphylococcus aureus* and *B. pyocyaneus*); also the case in which Loeser[1] found *B. coli* in orbital pus, and a case by Coburn (*Arch. of Ophth.*, 1906, p. 467) with *Streptococcus*. Reis' case,[2] which resulted from a pustule of the upper lip (*Staphylococci* and *Streptococci*), and in which a circumscribed abscess was formed in the lamina cribrosa of the optic nerve, was considered by the author as infection by way of the veins. The case of Panas[3] was certainly endogenous; this was very interesting regarding the question of localizing causes. An angioma, which had been partly thrombosed by electrolytic treatment, was infected during the course of a typhus abdominalis. Typhoid bacilli were found in the pus, having probably been conveyed there by the circulating blood.

Primary osteomyelitic nodules also occur in the walls of the orbit (von Ammon[4]); these are not only tubercular, as is commonly the case in the zygomatic, but also can be due to pyogenic cocci. Morax[5] has published interesting results in cases of staphylococcal osteomyelitis.

The formation of suppurating periosteal abscesses is also possible, especially after contusions. Careful differential diagnosis in the future will show how far these are due to purely periosteal abscesses, through which the pyogenic organisms in the blood are endogenously located at the site of the contusion, and to what extent primary sinus changes are at work. Trauma, especially contusion, is an important factor in the etiology of empyema.

In its rare purulent form, tenonitis, occurring in infectious diseases, is certainly a bacterial metastasis.[6] Even in the non-purulent serous forms we must consider the possibility of a toxic cause; the same considerations are here of importance as in the case of the benign forms of metastatic ophthalmia (*cf.* p. 364).

Leaving aside the cases in which the orbit is affected by collateral œdema and infiltration, it is extremely rare for orbital suppuration to result from operations on the eye or its adnexæ.

The orbital tissues sometimes, however, convey an infection upwards to the meninges, especially when an eye is enucleated in a condition of violent panophthalmitis, a procedure which Graefe considered as contra-indicated, but which still finds supporters. Enslin

[1] *Z. f. A.*, 1902, viii., S. 24.
[2] *A. f. O.*, 1905, lix., S. 155.
[3] *A. f. O.*, 1904, lix., S. 155.
[4] *A. f. A.*, 1904, xlix., S. 1.
[5] *Soc. d'Ophth. de Paris*, 1905, ref. *K. M. f. A.*, 1905, i., S. 435.
[6] Fuchs, Mazza, Rollet, *Ann. d'Ocul.*, 1902, cxxviii., S. 52. Bronner, T. O. S., 1903, xxiv. 209. Purtscher, *Zent. f. A.*, March, 1904.

and Kuwahara,[1] in Oeller's clinic, examined such a case, and found the *Streptococci* extending in the lymph spaces and the optic sheath right up to the meninges (the globe also contained bacilli and *Diplococci*), although the orbital tissues showed no macroscopical change.

The danger is greatest in those globes which have open septic wounds or ulcers, where the orbital tissues can be directly infected at the operation, while those cases with more encapsulated abscesses appear less precarious.

Meningitis is much rarer after exenteration of eyes with panophthalmitis. In Pes's case (*K. M. f. A.*, 1905, ii., p. 550) death from meningitis occurred three days after the exenteration. In the globe with the panophthalmitis *Staphylococci* were found, and in the meninges *Streptococci.* In the single case of Bocci[2] recorded by Enslin and Kuwahara *Pneumococci* were found. A further case of Alfieri,[3] though caused by *Pneumococcus*, is put aside by them, there being a general pneumococcal sepsis present.

The panophthalmitis, for which the eye was exenterated, was itself metastatic, and the meningitis could equally well be metastatic, and not the result of the exenteration.

In a case of meningitis following on a septic wound of the globe De Lapersonne found *Pneumococci* in the orbital tissues. He also succeeded in infecting the meninges from the optic sheath. Meningitis caused in this way by a panophthalmitis is comparatively rare, as the passages from the eye are rapidly closed by inflammatory coagulation and thrombosis.

In those well-known cases where erysipelas[4] of the face or the lids passes into the orbit, and finally affects the meninges, the lymph spaces around the nerves or vessels in the orbital fissures, the sheath of the optic nerve, or the veins (thrombo-phlebitis), are to be considered as the means of passage for the *Streptococci.*

The orbit must be considered as an emissary passage through the skull, conveying erysipelas along its veins in the form of a septic thrombo-phlebitis to the meninges.[5] The inflammatory and degenerative changes which occur in the orbit are partly due to *Streptococci* and their poisons, partly to vascular changes, and partly to compression.

Addario[6] argues that blindness can be caused by a necrosis of the optic nerve, due either to toxins or to thromboses blocking the nutrient vessels; for comparison he experimentally determined the influence of streptococcal poison, and also that of

[1] *A. f. A.*, 1904, l., S. 285 (*cf.* here the full literature; also found in Brückner's work).
[2] *Arch. di Ottal.*, 1896, iv. 104.
[3] *Arch. di Ottal.*, 1897, iv. 328.
[4] Leber considered that certain of the etiologically indeterminate orbital inflammations were due to transient erysipelas. The possibility that such can occur cannot be denied, but a sinusitis is more commonly the cause.
[5] *Cf.* Leber, *A. f. O.*, 1880, p. 212 *et seq.*
[6] *Arch. di Ottal.*, 1904, xii., fasc. 1, 2.

Streptococci. He made his injections into the retrobulbar tissues, but was unable to produce severe changes in the optic nerve by this means, and concluded that the degeneration was rather due to a thrombo-phlebitis of the orbit, which advanced along the nerve. The results obtained by Bartels agree with this view (*A. f. A.*, 1906, lvi., p. 267). Bartels, and before him Schmidt-Rimpler, could not confirm Mitvalsky's opinion that the early blindness in thrombo-phlebitis was due to the introduction of bacteria into the vena centralis retinæ.

Otschapowski's work (St. Petersburg Ophth. Soc., 1904, rev. Jahresber. von Michel and Nagel, 1904, p. 229) contains experi-

FIG. 87.—PNEUMOCOCCI IN THE ORBITAL TISSUES. GRAM-WEIGERT STAIN.

mental investigations on infection of the orbital tissues with *Staphylococci.*

In the reverse way a meningitis can lead to a spread of the pathogenic organisms into the orbit; this takes place along the optic sheath to the sclera. This is a rare exception (Axenfeld[1] and De Lieto-Vollaro[2]), and an infection of the interior of the eye by this means has never yet been determined. The orbital tissues can be also infected by the nerves and the vessels which pass through the fissure. Orbital cellulitis so developed is rarely seen clinically, as such cases are very

[1] *A. f. O.*, 1894, xl.; *Monatsch. f. Psych. u. Nervenh.*, 1897, i. 415.
[2] *K. M. f. A.*, 1903, Beilageheft (*Festschr. f. Manz*).

severe, and rapidly end in death.[1] I have been able, as the accompanying figure shows, to follow the *Pneumococci* in the case of a patient with meningitis far into the orbital tissues.

Weeks has observed an orbital cellulitis following on an abscess of the forehead.[2]

Naturally, orbital cellulitis can develop as the direct result of injuries or of infectious processes (trauma, furuncle, etc.) in the parts around, as in the case by Laas[3] which followed a furuncle of the nose, and gave *Staphylococcus aureus* on cultivation. These cases are an intermediate stage to the infectious phlebitis forms.

A sharp differentiation between orbital cellulitis and thrombo-phlebitis is impossible in many cases. Those cases which arise from the cavernous sinus are the purest cases of thrombo-phlebitis.

[A case of orbital cellulitis, resulting fatally, was reported to the Ophth. Soc. by Snell; see T. O. S., 1906. The source of infection was a vesicle on the lip.—A. M.]

Infectious **thrombo-phlebitis ophthalmica**[4] arises partly in an ascending manner from before (infected wounds and septic infections of the skin and its glands, etc.), partly descending from a septic sinus thrombosis, which itself can arise from many sources (ear, naso-pharynx, sinuses, tonsils, or as a metastasis in the course of infectious diseases and septic conditions). The bacterial findings in the disintegrated and infected thrombi are not always those which the original affection would lead us to expect.

Thus, resulting from a furuncle in the surrounding parts, Nonne, Cabannes, and Axenfeld found *Staphylococcus* in the veins; Villard found *Streptococci* after furuncles of the nose; Mitvalsky, whose researches are especially important, found *Pneumococci* and *Pneumobacilli* in a thrombo-phlebitis developing from an affection of the tonsils, and *Staphylococcus* in another case which occurred after erysipelas.

It is a strange fact that occasionally after a process on the one side—*e.g.*, a tonsillitis—by the intermediary of the cavernous sinus a septic thrombo-phlebitis of the opposite side can occur (Leber, Panas, and Terson).

[1] *Cf.* the literature given by Axenfeld, *Monatssch. f. Nervenh.*, 1897, i. 415; also by Uhthoff, Heidel. Conf., 1905. The case of Hoffmann is quite exceptional; there, after a meningitis, an encapsulated abscess was demonstrated in the optic sheath.

[2] *Ann. d'Ocul.*, 1901, cxxvi. 66.

[3] *Z. f. A.*, 1902, vii., p. 179; here the literature.

[4] Bacterial findings: *Cf.* Günsburg, *Wjestnik Oft.*, July, 1895, and *Arch. d'Ophth.*, 1896, xvi. 380. Mitvalsky, *ibid.*, 1896, xvi. 22. R. Hoffmann, *Z. f. A.*, 1906, xvi., Ergzgsh. Terson, *Recueil d'Ophth.*, 1893. Eversbusch, Leber, *loc. cit.* Gillet, *Thèse de Paris*, 1905. Stocker, *Arch. f. Augenh.*, 1901, xxxiv., S. 195. Villard, *Arch. d'Ophth.*, 1895, xv. 477. Müller, Dissert., Würzburg, 1905. Nonne, *Münch. Med. Woch.*, 1904, S. 943. Cabannes, *Jour. Med. de Bordeaux*, 1904, ref. Michel-Nagel. Rochon-Duvigneaud and Onfray, *Arch. de Méd. des Enfants*, 1905, S. 537 (*Staphylococcus aureus*). Morax, *Soc. Franç. d'Ophth.*, 1905 (*Streptococci* and *Staphylococci*). Bartels, *A. f. A.*, 1906, lvi., S. 267.

Cases of **actinomycosis of the orbit** are recorded by Partsch,[1] Ransom,[2] Darier and Gauthier,[3] Coppez and Depage,[4] Vossius,[5] Koch,[6] Axenfeld,[7] and Weeks.[8]

[1] *Zent. f. A.*, October, 1893.
[2] B. M. J., June 28, 1896.
[3] *Jour. Méd. de Bruxelles*, 1902.
[4] Coppez et Depage, *Jour. Méd. de Bruxelles*, 1903, No. 48; *Arch. d'Ophth.*, 1904, p. 163.
[5] Ophth. Congr., Heidelberg, 1902, S. 210.
[6] Koch, 'Two Cases of Orbital Cellulitis, One due to Actinomycosis,' Ärztl. Verein, Nürnberg, ref. *Ophth. Klinik*, 1904, S. 299.
[7] *Deutsche Med. Woch.*, 1902, S. 813.
[8] 'New York Eye and Ear Infirmary Rep.,' January, 1897.

INDEX

A

Abscess, periosteal of the orbit, 328
Abscessus siccus, 329
Acarus folliculorum, 56
Acne, 56
Actinomyces albus, 288, 295
  in dacryocystitis, 281
  hominis s. bovis, 288, 289, 295
Actinomycetes, 295
Actinomycosis, 73
  miliary, of the choroid, 370
  of the orbit, 391
Aerobacillus citreus, 42
Aggressin immunity, 335
  serum, 337
Alcohol for disinfection of the lid margins, 98
Aleppo boil, 72
Amboceptors, 334
Anaerobic cultures. See Culture
Angular conjunctivitis, 160
Aniline dye, simple, 5
  water, gentian violet, 7
  xylol, 10
Antagonism, 43
  between trachoma and pneumococci, 181, 271, 304
Anterior chamber inoculation, 22
Anthrax gangrene of the lids, 64
Anti-aggressin, 335
Antibodies, 334
Antipneumococcal serum, 100
Antistreptococcal serum, 209
Aspergillus fumigatus, 96, 315

B

Babes-Ernst bodies, 193
Bacille en massue. See Xerosis bacillus
  filamenteux, 294
  sporulée, 90
Bacilles courts, 192
  longs, 192
Bacilli, Gram-negative, in dacryocystitis, 279
  Herbert's intra-epithelial, 325
  pyogenic, in dacryocystitis, 282
  'tuberculoid,' 348
Bacillo hæmofilo, 153
Bacillus acidi lactici, 92
Bacillus aëris minutissimus, 148
  agilis, 91
  albicans, 42
  aurantiacus, 42
  aureus, 42
    minutissimus, 148
  butyricus, 42
  candicans, 91
  conjunctivitidis subtiliformis, 247
  cuticularis, 41
  cyanogenes, 91
  dendriticus, 91
  diffusus, 42
  fluorescens, 92
    in dacryocystitis, 279
    liquefaciens, 42, 92
    putridis, 41, 91, 292, 385
  fragilis, 385
  funduliformis, 282
  granulosus. See Xerosis
  inflatus, 41
  lactis aërogenes, 242
  latericius, 42
  liodermos, 42
  liquefaciens fluorescens putridus, 92, 385
  luteus, 41
  megatherium, 92, 95
  mesentericus, 41, 91
    in conjunctivitis folliculosa, 272
  mucosus capsulatus, 242, 326
  mycoides, 91, 92
  nodosus parvus, 41
  ochraceus, 42
  pateriformis, 42
  perfringens, 85, 385
  prodigiosus, 91, 200
  proteus fluorescens, 311
  proteus vulgaris, 41
  pseudo-conjunctivitidis, 148
  pseudo-diphthericus vulgaris conjunctivæ. See B. xerosis
  pyocyaneus, 95, 310, 368, 378
    in atypical hypopyon-keratitis, 306, 309
    in dacryocystitis, 281
    keratitis, 306, 309
    in metastatic inflammation of the orbit, 388
    in ophthalmia neonatorum, 229

THE ASIATIC SOCIETY OF BOMBAY LIBRARY

Bacillus pyocyaneus pyogenes, 95
fœtidus, 306, 385
radiciformis, 92
ramosus, 385
of rhinoscleroma, 242
ruber indicus, 91
sebi Meibomiani. See B. xerosis
serpens, 385
sporiferus, 42
subtilis, 41, 88, 91, 92, 96, 102, 103, 327
as cause of conjunctivitis, 125
on the conjunctiva, 246
morphology and culture, 247
pathogenicity of, 249
in conjunctivitis folliculosa, 272
as a facultative cause of conjunctivitis, 112
morphology, culture, pathogenicity, 88
in ulcus serpens, 306
violaceus, 91
vulgaris pseudo-diphthericus conjunctivæ, 195
Bacteria, hæmophile, 19
pleomorphous, 296
Bacterial aneurism in retinal streptococcal embolism, 376
Bactericides, 334
Bacterium coli commune, 95, 239
in atypical hypopyon-keratitis, 306
in blennorrhœa neonatorum, 229
the cause of conjunctivitis, 124, 239
in conjunctivitis pseudo-membranosa, 204
in dacryocystitis, 279, 280
facultative cause of conjunctivitis, 112
liquefaciens, 93
in metastatic ophthalmia. 368
in metastatic orbital inflammations, 388
in ophthalmia neonatorum, 229
punctatum, 93
Behring's serum, 203, 331
Benzene for disinfection of the lid margins, 98
Blastomycetes in spring catarrh, 252
in chalazion, 68
Blastomycosis cutis. 74
Blennorrhœa neonatorum, 229
bacteriology, 229
due to B. coli, 239
gonorrhœal, 225
non-gonorrhœal, 228
due to pneumococci, 179, 263
with trachoma, 263
Blepharitis, 54
squamosa, 54
trichophytica, 71
ulcerosa, 56
Blepharo-conjunctivitis, 159, 160
Blood agar, Pfeiffer's, 212
media, Pfeiffer's, for Koch-Weeks bacilli, 142
serum, Löffler's, 19
Botryomycosis, 76, 320
Buchner's anaerobic cultures, 21

C

Capsules, 348
Capsule-staining, 12
Carbol fuchsin, 5
toluidin, 11
Carbonate of lime in canalicular concrements, 286
Caruncula lacrymalis, furuncle, 60
Cataract, infection of, 93
Catarrh, acute muco-purulent, bacteriological findings, 114
subacute, bacteriological findings, 114
Catarrhal ophthalmia, acute, from Diplobacilli, 161
epidemic, etiology, 110
Chalazion, 65, 199
bacilli, 65
conjunctivitis, 65
Chamber, anterior, material from, 3
Charbon. See Anthrax
Chicken-pox, cause of, 384
Cicatrix, adherent, causing infection, 103
Cilia, healing of, 98
staining of, 15
Ciliary nerve theory, modified, 381
Coccus albus non-liquefaciens, 36
Complements, 334
'Conjonctivite subaiguë,' 157, 160
Conjunctiva, 24, 108
actinomycosis of, 250
collection of material from, 1
concrements of, 250
diphtheria, chronic, of, 203
of, in scarlet fever and measles, 205
'diphtheroid,' 198, 199
endogenous toxic inflammation of, 106
follicular affections of, 129
glanders of, 249
gonorrhœa of, 225
immunity after pneumococcal infection, 182
leprosy, maculo anæsthetic, 346
tuberosa, 343
mixed infections, 116
participation in abrin immunity, 125
diphtheria immunity, 125
pneumococcal immunity, 126
soor of, 250
tuberculosis, endogenous of, 279
in keratitis, 321
in lid affections, 74
ulcus molle, 250
Conjunctival secretion, method of collection, 1
Conjunctivitis, actinomycotic, 250
from the action of toxins, 127

Conjunctivitis catarrhal, bacteriology, 114, 115, 116, 117
endogenous, 130
croupous, 190
diphtheritic, 190
facultative producers of, 128
folliculosa, 264, 271
general, 108
statistics, 114, 115, 117
granulosa. See Trachoma
impetiginous, 254
membranous, 115
metastatic gonorrhœal, 130
muco-purulent, 114
with negative findings, 114, 117, 128
neonatorum, findings, 114, 115
phlyctenular, 125, 253
findings in, 113, 115
post-blennorrhœal, 264
post-operative, 80
due to Gram-negative cocci, 215, 224
pseudo-membranous, 190, 203
findings in, 113
hospital epidemics of, 210
purulent, 115, 116
findings, 114, 115
Conservation of cultures, 21
Cornea, 300
botryomycosis of, 320
catarrhal ulceration, 301
collection of material from, 2
in conjunctival diphtheria, 203
diplobacillary infection of, 130
endogenous infection of, 360
fibroma of, 320
in general antitoxic immunity, 102
bacterial immunity, 102, 337
infection with B. influenzæ, 313
B. Koch-Weeks, 312
pathogenic moulds, 315
pneumococci in children 305
infiltrate, simple, 301, 302
from Hefæ, 91, 320
trachomatous, 312
inoculation of, 21
leprosy, maculo-anæsthetic, 346
tuberosa, 344
necrosis from diphtheria toxin, 330
from measles, 251
from soor, 250
ring abscess of, 311, 360
Spirochætæ in, 357, 361
streptococcal infection, 207
tubercle of, 361
ulcus internum, 361
Corneal abscess, complications in diplobacillary conjunctivitis, 161
metastatic, 360
infections, serum treatment of, 99, 203, 209, 259, 329, 339, 384
scars, adherent, as path of infection, 309
Corpus ciliare, leprosy of, 346
Corynebacterium diphtheriæ. See B. diphtheriæ
Cover-glass diagnosis, 110
Crisis in pneumococcal conjunctivitis, 178
Cultures, anaerobic, 20
Curative serum, Behring's, 203
Cytorrhyctes Guarneri, 329
luis, 358
Cytotoxin reaction (Römer), 99
Czapelewski's modification of Gram's stain, 7

D

Dacryoadenitis, metastatic gonorrhœal, 224, 230, 299
purulent, 298
Dacryocystitis, 97, 275
due to B. coli, 239
due to B. pyocyaneus, 310
neonatorum, 284
phlegmonous, due to Streptococci, 208
Diagnosis of conjunctivitis, 119
Diffusion iritis, 205
Diphtheria bacilli, 190, 312, 329
agglutination of, 196
atoxic, 197
bactericidal serum, 200
in blennorrhœa neonatorum, 229
as the cause of conjunctivitis, 124
in conjunctivitis pseudo-membranosa, 113
culture of, 192
in empyæma of the sinuses, 385
granule-staining (Neisser), 193, 202, 217
in mixed affections with pyogeni organisms, 203
morphology, 190
necessity for culture of, 110
pseudo-membranes due to, 190
staining of, 193
clinical bacteriological diagnosis, 121, 201
serum, antitoxic, 330
bactericidal, 330
treatment, 201
Diphtheroid, 198, 199
Diplobacillus, Morax-Axenfeld, 98, 162
in blepharitis ulcerosa, 58
as the cause of phlyctenular keratoconjunctivitis, 125
in chalazion, 66
in corneal infiltrations, 301
in dacryocystitis, 279
formation of capsules, 163
in hypopyon-keratitis, 301, 338
inoculation of pure cultures in man, 111
in keratitis fasciculosa, 302, 305
in the lacrymal sac, 275
in measles conjunctivitis, 251
in ophthalmia neonatorum, 229
Petit type, 167, 305
in scrofulous inflammations, 257
in trachoma, 262, 263, 267
in trachomatous ulceration of the cornea, 312
in ulcus serpens, 305

Diplobacillary conjunctivitis, 113, 157
clinical appearances, 160
cultures, 163
differential diagnosis of, 172
diplobacille liquéfiant of Petit, 167
findings in the secretion, 162
with follicle formation, 272
geographical spread and epidemiology, 158
historical, 157
morphology of the bacillus in culture, 165
pathogenicity, 171
resistance, 165
transmission, 123
treatment, 173
Diplococci, Gram-negative, 214
in dacryocystitis, 282
differential diagnosis, 220
necessity of cultures, 110
Diplococcus albicans, 36
tardissimus, 36, 214
amplus, 36
tardus, 36
Diplococcus citreus conglomeratus, 39
crassus, 217
flavus in ophthalmia neonatorum, 229
fluorescens liquefaciens fœtidus, 41
Fränkel-Weichselbaum's, 183
lanceolatus, 183
pharyngis flavus, i, ii, iii, 219
pneumoniæ, 183
roseus, 41
siccus, 219
of sputum septicæmia, 183
Disposition to conjunctivitis, 123
Ducrey-Krefting bacillus (ulcus molle), 74

E

Ectoplasm (capsules), 13
Eczema, acute, 55
impetiginous, 56
Endotoxins of Pneumococci, 334
Epidemics, acute, etiology of, 110
Erysipelas, 62, 389

F

Favus, 70, 287
Febris recurrens, intra-ocular metastatic inflammation, 370
Follicles in pneumococcal conjunctivitis, 189
Follicular conjunctivitis, 261
Folliculosis conjunctivæ, 271
Foot-and-mouth disease, 384
Foreign body, wound by, 88, 91
Framboesia Brasiliana, 75
Friedländer's bacillus. See Pneumobacillus
Fungi imperfecti, 265

G

Gangrene of lids, 63
Gentian violet, 7
Giemsa stain, 18
Glanders, 73, 249
bacilli, morphology, 249
Globi, 343
Glycerine-ether mixture, 11
Gonococcal infection, clinical appearances, 225
mild course of, 226
susceptibility, 226
along with trachoma, 226
Gonococci in congenital blennorrhœa, 229
in conjunctivitis pseudo-membranosa, 204
in dacryo-adenitis, 299
in dacryocystitis, 282
neonatorum, 284
differential diagnosis, 220
histological findings, 212
immunization, 213
morphology and culture, 212
presence in animals, 213
in trachoma, 262, 263
Gram-negative organisms, 9
Gram-positive organisms, 9
Gram's stain, 6
Weigert's modification of, for sections, 9
Granule-staining (Neisser), 17

H

Hæmoglobin, media containing, 19
Hæmolysin reaction, 341
Hæmolysis by non-pathogenic Staphylococci, 238
Hæmophile bacteria, 19
Hæmorrhage in pneumococcal conjunctivitis, 178
Hay bacillus. See B. subtilis
Hefa colonies on normal skin, 42
Hefæ in blastomycosis cutis, 74
in chalazion, 68
keratitis, 321
in spring catarrh, 252
Herpes tonsurans, 71
Hoffmann's modified stain for Spirochætæ, 18
Hordeolum, 59
Hyperæmia marginalis, 54
Hypopyon-keratitis. See Ulcus serpens, atypical, 302

I

Immunity of the aqueous, 99
of the cornea, 101
participation of vitreous in general, 100
Immunization, active, 355
passive, 355
against Pneumococci, 332
Impetigo contagiosa, 56
Index, opsonic, 355, 356
phagocytic, 355
Infection, post-operative, from saprophytes, 291
Inflammation, intra-ocular endogenous rheumatic, 369
scrofulous, 129, 253
opsonic index in, 259
tubercular reaction in, 257

Influenza bacilli, 113, 149
in atypical hypopyon-keratitis, 306
bactericidal immunity, 150
as cause of conjunctivitis, 124
in conjunctivitis of measles, 251
in dacryo-adenitis, 131, 299
in dacryocystitis, 280, 281
as facultative cause of conjunctivitis, 111
group of bacilli in dacryocystitis, 275
intra-ocular inflammations, 369
in the lacrymal sac, 154, 277
in metastatic ophthalmia, 369
morphology, culture, 149
in ophthalmia neonatorum, 228, 229
in orbital abscess, 369
in orbital inflammations, 386
presence in the eye, 150
in sinus empyemata, 385
in trachoma, 266
Inoculation keratitis from Staphylococci, 302
after section of trigeminus, 328
Inulin-water (His), 188
Iodine-potassium iodide solution, 7
Iodine reaction with Streptothrix buccalis, 287, 288, 289, 293
Iridocyclitis, from B. coli liquefaciens, 93
from bacilli of the influenzal group, 94
from bacilli of the Subtilis group, 94
insidious, 93, 368
from Pneumococci, 93
from saprophytes, 92
from Staphylococcus pyogenes albus, 93
Iris, leprosy, maculo-anæsthetic of, 346
Iritis, experimental, 379
metastatic, 372
in pneumococcal conjunctivitis, 180

J

Jadassohn's modification of Gram's stain, 6

K

Keulen bacillus. See B. xerosis.
Keratitis annularis parenchymatosa, 361
dendritica, 327, 329
disciformis, 329
fascicular, 257, 302, 305, 316
from Pneumococci, 304
from Hefæ, 91
neuro-paralytic, 329
pannosa (leprous), 344
parenchymatosa, 361
punctata leprosa, 341, 345
superficialis, 325
purulent, 302
in diphtheria, 312
scrofulosa, 302
Kerato-conjunctivitis phlyctenulosa, 253
Keratomalacia, 305
Keratomycosis aspergillina, 315
Koch-Weeks bacillus, 139
in conjunctivitis of measles, 251
in dacryocystitis, 282
inoculation of pure cultures in man, 134
mixed infections, 141
morphology, 139, 144
in ophthalmia neonatorum, 114, 115, 228, 229
in pseudo-membranous conjunctivitis, 113, 204
resistance of cultures, 144
in scrofulous inflammations, 257
toxic properties, 146
in trachoma, 135, 139, 261
Koch-Weeks conjunctivitis, 133
clinical appearances, 137
contagion, prevention, 144
cultures from, 141
differential diagnosis, 148
geographical distribution, epidemiology, 135
historical, 133
immunity, 146
pathogenicity, disposition, 137
secretion, findings in, 139
treatment of, 146

L

Lacrymal gland, infection, 298
sac, diphtheria, 281
glanders of, 282
rhinoscleroma, 282
trachoma of, 269, 276
tuberculosis of, 276
Lens in leprosy, 346
Lepra bacilli, 341, 362
staining in sections, Baumgarten's method, 17
cells, 342, 346
Leprosy, 341
maculo-anæsthetic, 345
tubercular, 341
Leproma, 342, 344
Leptothrix, 286, 293
buccalis, 286, 294
Leucæmia, acute, 365
Leucocidin, 37
Leukonostoc, 186
Levaditi's staining, 18
Lids, the, 49
abscess of, 60
anthrax of, 64
furuncle of, 59
gangrene, senile, of, 64
leprosy, tuberosa of, 343
ulcus durum of, 357
Löffler's blood-serum, 19
diphtheria bacilli. See diphtheria bacilli
methylene blue, 5
modification of Gram's stain, 7
universal method, 5
Luftkokken in measles conjunctivitis, 251
Luftstäbchen. See B. xerosis, 33

M

Mallei, B., 73
Marginal keratitis, infectious, 300, 321
ulcer, infectious, 312, 321
Margin, progressive, of ulcus serpens, 308
Mast cells, 12
Measles, conjunctivitis of, 251
pneumococcal conjunctivitis after, 178, 179
Media, acid, for Streptothriceæ, 292
containing hæmoglobin, 19
serum, 19
Thalmann's, 213
Meningococcus intracellularis, 214, 217
action on various sugars, 218
agglutination of, 218
on the conjunctiva, 222
culture, 218
differential diagnosis, 218, 220
in metastatic ophthalmia, 374
morphology, 217
pathogenicity for animals, 219
in pseudo-membranous conjunctivitis, 189
resistance to desiccation, 223
in secretion of normal naso-pharynx, 222
in sinus empyemata, 385
Metastatic ophthalmia, 364
Methylene blue, 5
polychrome, 11
Methyl green, Pappenheimer's stain, 10
Micrococcus albicans amplus, 214
albus non-liquefaciens, 36
aquatilis, 41
aurantiacus, 38, 54
candicans, 33, 36, 53
carneus, 41
catarrhalis, 214, 216
action towards various sugars, 216
agglutination experiments, 217
culture, 216
in dacryocystitis, 282
differential diagnosis, 220
pathogenicity for animals, 217
pathogenic significance for the conjunctiva, 224
resistance, 216
cereus albus, 36
cinereus, 219
cinnabareus, 41
citreus, 39
concentricus, 37
conjunctivitidis minutissimus, 236
coronatus, 41
coryzæ, 41
epidermidis albus, 36
flavus, 39
desidens, 39
luteus, 39, 54
in ophthalmia neonatorum, 229
'sarcina-form,' 40
prodigiosus, 41
pyogenes albus, 37
Micrococcus roseus, 39, 41, 91
subflavus, 39, 214
sulphureus, 39, 54
tardigradus, 39
tetragenus, 40, 379
Microsporon trachomatosum, 265
Molluscum contagiosum, 69
bodies, 69
Monocalcium phosphate in canalicular concrements, 286
Morphæa alba, 342, 387
Mould concretions, 285
fungi on the normal conjunctiva, 42
in trachoma, 265
keratitis, 315
Moulds in the lacrymal sac, 294
Mucocele, 278, 387
Mucous membrane of nose in trachoma, 271
Müller's (L.) bacillus. See B. influenzæ

N

Zur Nedden's bacillus, clinical appearances of ulcers, 322
cultures, 323
differential diagnosis, 323
in keratitis neuro-paralytica, 328
of infectious marginal ulcer, 172, 300, 312, 321
inoculation of, 324
morphology, 323
findings in sympathetic ophthalmia, 383
Neisser's granule-staining, 17
Neonatorum ophthalmia, clinical appearances, 226
non-gonorrhœal, 228
from Pneumococci, 180
Nervi-ciliares in maculo-anæsthetic leprosy, 346
in tuberosa leprosy, 345
Nervus lacrymalis in leprosy, 346
opticus in leprosy, 345, 346
Neuritis, leprous, 345
New-born infants, conjunctiva of, 25
New tuberculin, T.R., 353
Nicolle's thionin-staining, 6, 11
Noma of the lids, 64

O

Oïdium albicans, 92
Oöspora, 296
Ophthalmia angularis, 160
bacterial findings, 364-380
benign, 365, 373
cryptogenetic, 369
Egyptian, 262
in epidemic cerebro-spinal meningitis, 374
experimental, 378
isolated, 377
metastatic, 364
neonatorum, bacteriological findings, 115
puerperal form of, 368, 370
special forms. See Conjunctivitis

Ophthalmia, surgical form of, 369
sympathetic, 379, 383
Opsonic theory, 334, 355
Opsonin, 354, 355, 356
Orbital inflammation, 385
actinomycotic, 391
erysipelatous, 389
metastatic, 387
from thrombo-phlebitis, 391
traumatic, 388
Osteomyelitis, 388
Ozæna bacillus. See also Pneumobacillus
in atypical hypopyon-keratitis, 306

P

Pannus scrofulosa, 257
trachomatosa, 214, 264, 267, 303
Panophthalmitis bacilli, 87, 88
from B. coli, 239
from B. pyocyaneus, 310
gaseous ('panophthalmie gazeuse'), 96
metastatic, 364
post-operative, 94
spontaneous, 377
traumatic, 94, 95
tubercular, 369
Papillo-retinitis sympathetica, 382
Pappenheim's stain, 11
Parinaud's conjunctivitis, 129, 250
Scholtz bacillus in, 251
Parotitis, epidemic, affection of lacrymal gland, 298
Pediococcus cerevisiæ, 41
Penicillium glaucum, 318
Pericystitis, 280, 281
Petit's type of the Diplobacillus, 167
Pfeiffer's bacilli. See Influenza bacilli
Phlogosin (Leber), 38
Phlyctenular appearance in pneumococcal conjunctivitis, 178
Phlyctenules, 253
Pick-Jacobsohn's stain, 6
Pigment, 12
Pigs' serum nutrose agar (Wassermann), 141, 212
Pneumobacillary conjunctivitis, 241, 243
Pneumobacilli, 94, 172, 241, 324, 326
as cause of conjunctivitis, 124
capsules, 244
in chalazion, 66
in conjunctivitis pseudo-membranosa, 204, 243
cultures, 243
in dacryocystitis, 244, 279, 280
differential diagnosis, 244
as facultative cause of conjunctivitis, 112
in hypopyon-keratitis, 245
in infectious thrombo-phlebitis ophthalmica, 381
in keratomalacia, 245, 305
in metastatic ophthalmia, 369
orbital inflammations, 388
in sinus empyemata, 385
in ophthalmia neonatorum, 229, 243
Pneumobacilli in orbital inflammations, 385
pathogenicity of, 244
in serpiginous keratitis, 305
in ulcers of the cornea, 245
Pneumococcal conjunctivitis with formation of follicles, 271
clinical appearances, 178
contagion and susceptibility, 181
critical termination, 178
findings in the secretion, 182
historical, 176
infection in trachoma, 180
occurrence and geographical distribution, 177
immunity, 100, 332
prophylactic, 101
Pneumococci, 94, 95, 96, 98, 101, 103, 183, 243, 300, 322, 365, 389
agglutination of, 188
in blennorrhœa neonatorum, 229
capsules of, 189
as cause of conjunctivitis, 124, 176
chain formation in, 189
in conjunctivitis pseudo-membranosa, 204
of measles, 251
cultures, 183, 184
in dacryo-adenitis, 398
in dacryocystitis, 275-280
in neonatorum, 284
differential diagnosis of, 184, 208
as facultative cause of conjunctivitis, 112
growth on blood-agar, 188
in infectious thrombo-phlebitis, 391
in keratitis fasciculosa, 301
keratomalacia, 305, 308
metastatic nodules of the retina or choroid, 366
ophthalmia, 368, 372
mixed infections, 189
morphology, 184
on normal conjunctiva, 40, 182
in ophthalmia neonatorum, 228, 230
in orbital inflammations, 386
in purulent keratitis, 302-308
in purulent tenonitis, 367
in ring abscess of cornea, 311
in scrofulous inflammations, 257
in sinus empyemata, 385
in trachoma, 261, 262, 263
in trachomatous corneal ulcers, 312
virulence of, 188
Pneumotoxin, 333
Polychrome methylene blue, 11
Pranter's orcein solution, 11
Preauricular gland, swelling in pneumococcal conjunctivitis, 180
in lacrymal streptococcal conjunctivitis, 206
Proteus in conjunctivitis of measles, 251
in dacryocystitis, 281
in gangrene of the lids, 91
in ulcus serpens, 306

Pseudo-actinomycosis, 289
Pseudo-conjunctivitis, 284
Pseudo-diphtheria bacilli, 193, 361
agglutination, 196
Hoffmann-Löffler's form, 193, 194, 195
in sinus empyemata, 385
in sympathetic ophthalmia, 383, 384
in the throat, 196
in the vagina, 196
Pseudo-gonococci, 36, 68, 200, 214, 227, 230, 237
Pseudo-influenza bacilli, 150, 151
in ophthalmia neonatorum, 229
Pseudo-membrane in pneumococcal conjunctivitis, 176, 178, 179
from a virulent bacilli, 198
Pustula maligna, 64
Pyocyaneus conjunctivitis, 310
Pyocyanin, 310
Pyronin, 11

R

Recurrent fever, 369
Resorcin, 11
Retina in maculo-anæsthetic leprosy, 345
in tubercular leprosy, 344
Retinitis septica, 365
metastatica, 364
Rhinoscleroma, 72
bacilli, 326
Rosa hefa, 67, 200
in atypical hypopyon-keratitis, 321

S

Saccharomyces, 321
Safranin, 7
Sarcina alba, 39
aurantiaca, 39, 68, 91, 200, 214
flava, 39
lutea, 39, 91
rosea, 39
tetragena, 39
Sarcinæ in conjunctival secretion, 237
in dacryocystitis, 281
Gram-negative, 214, 219
School follicles, 271
Sclera, leprosy of, 345
metastatic abscess of, 373
mould infection of, 319
Scrofula, 253
as predisposing to trachoma, 268
Self-infection, 122
with Pneumococci, 182
Septic pyæmia, puerperal, 368
Sera, antitoxic, 101, 330
bactericidal, 334
polyvalent, 335, 336
Serum agar (Wertheim), 19, 212
as medium for Koch-Weeks bacillus, 141
Serum treatment, 101, 201, 331-340
Silver method for Spirochæte, 358
Sinus empyæma, 387
Skin cocci, 36
Soor, 250
Spirochæta pallida, 357, 358, 359
staining in smears (Giemsa), 18
in sections (Levaditi), 18
perfringens, 359
Spores, staining of, 16
Spring catarrh, 129, 252
Staphylase, 280
Staphylococcal conjunctivitis, 233
scrofula, 254
serum, 101
Staphylococci in atypical hypopyon-keratitis, 305
as cause of conjunctivitis, 124
in the conjunctivitis of measles, 251
in dacryocystitis, 275, 278
neonatorum, 284
in follicular conjunctivitis, 233, 272
in keratitis fasciculosa, 302, 304
in metastatic ophthalmia, 372
in orbital inflammations, 386
osteomyelitis, 388
in Parinaud's conjunctivitis, 250
in post-operative conjunctivitis, 234
in purulent keratitis, 302
in ring abscess, 311
in scrofulous inflammations, 253
in sinus empyemata, 385
virulent, necessity for cultures, 111
white, in blepharitis, 55
ulcerosa, 57
in chalazion, 66
on the conjunctiva, 33
on the lids, 53
in normal external ear, 54
in pyogenic properties of, 33
Staphylococcus albus non-liquefaciens, 36
brevis, 36
cereus albus, 36
flavus, 39
citreus, 39
epidermidis albus, 35, 36
habanensis, 36
parvulus, 385
pyogenes albus, 36, 37
aureus, 37, 54, 57, 58, 94, 99
in conjunctivitis of measles, 251
in dacryocystitis neonatorum, 284
in infectious thrombo-phlebitis, 391
in kerotomalacia, 305
in metastatic ophthalmia, 372
orbital inflammations, 388
in pseudo-membranous conjunctivitis, 204, 234, 235
in purulent dacryo-adenitis, 298
citreus, 39, 94
in ophthalmia neonatorum, 229, 233
in orbital inflammations, 287, 391
in toxins, 235
Staphylolysin, 38

Statistics of conjunctivitis, 113
Streptobacilli, 74
Ducrey's, 249
Streptococcal conjunctivitis, lacrymal, 180, 205
slide diagnosis, 207
diphtheria, 330
immunity, 101
sepsis in measles, 252
serum, 101, 330
Streptococci in atypical hypopyon-keratitis, 306
as cause of conjunctivitis, 124
in chalazion, 66
in the conjunctivitis of measles, 131
in dacryocystitis, 275, 278
as facultative cause of conjunctivitis, 112
in infectious thrombo-phlebitis, 391
in keratomalacia, 305
on normal conjunctiva, 41
in ophthalmia neonatorum, 228, 229
in orbital inflammations, 386
in purulent keratitis, 302, 305
in retinitis septica, 367
in ring abscess, 311
in sinus affections, 385
Streptococcus, 204
brevis, 209
in the vitreous, 207
erysipelatis, 209
longus, 209
malignus, 207
mitior *sive* viridans, 209
mucosus, 185, 208, 209
differential diagnosis, 186
puerperalis, 207
pyogenes, 204, 207
characteristics of, 206
in conjunctival diphtheria of measles, 205
in conjunctival diphtheria of scarlet fever, 205
in conjunctivitis of measles, 251
cultures, 208
in dacryo-adenitis, 299
differential diagnosis, 207, 208
fermentation of sugar, 209
formation of antibodies, 209
of false membrane, 190
growth on blood-agar, 188
hæmolysis, 209
impetigo contagiosa, 205
in metastatic ophthalmia, 370
in mucocele fluid, 207
in phlegmonous dacryo-cystitis, 280
in pseudo-membranous conjunctivitis, 235
in puerperal purulent metastatic ophthalmia, 368, 370
in secretion preparations, 206
serum treatment, 101, 209, 329
in traumatic panophthalmitis, 95
virulence of, 209
in the vitreous, 207
Streptococcus scarlatinosus, 183, 184, 208
septicus. See S. pyogenes
Streptothrix in the canaliculi, 286
on the conjunctiva, 42
on the cornea, 313
Foersteri, 288, 293, 295
Sycosis simplex, 57
staphylogenes, 57
Symbiosis, 44
Sympathetic ophthalmia, 382
irritation, 381
Syphilis, 356

T

Tannin orange, 11
Tears, agglutinating power of, 80
antitoxic properties of, 79
bactericidal properties of, 77
sulphocyanide in, 77
Tenonitis, 367, 388
Tetanus, 102
antitoxic serum, 102
Tetragenus, 237
in dacryocystitis neonatorum, 284
Thionin-staining. See Nicolle
Thrombo-phlebitis, 389, 390, 391
Trachoma, 129, 261
bacterial treatment, 181
of canaliculi, 276
cocci, 35, 264
of lacrymal sac, 276
Trichomycetes, 295
Trichophyton of the lids, 71
ectothrix, 72
tonsurans, 71
Trypanosoma, 132, 362
Tubercle bacillus, 346-349, 378, 379
staining in smears, 16
in sections, 17
Tuberculosis, 346
examination for bacilli, 347
inoculation of, 347
opsonic index, 355
tuberculin, diagnosis of, 351
treatment of, 353
Tuberculin, 352
Typhoid bacilli in metastatic ophthalmia, 369
in orbital cellulitis, 386

U

Ulcus durum, 74, 357
molle, 74
rodens, 327
serpens, 302
from B. coli, 239
from B. duplex, 161
serum treatment, 300, 330
in trachoma, 312
Ultra-microscope in sympathetic ophthalmia, 383
in trachoma, 265
Urethral gonorrhœa, 226
Uvea, leprosy of, 345
Uveal inflammation, experimental metastatic, 367

V

Vaccine, 329, 354, 355
Varicella, 329
Variola, 329
  protozoa, 329
Vascular ulcer, 304
Vitreous, inoculation, 22
  leprosy of, 344
  mould infection of, 319
  suppuration, 86

W

Weigert's modification of Gram's stain, 9
Wound infection, 77
  due to B. xerosis, 93
  endogenous, 103
  occurring from the lid margins, 98
    from the lacrymal sac, 96
  serum treatment of, 99
  suppuration, experimental endogenous, 104
  toxic endogenous, 104
Wounds with wood splinters, 88, 90

X

Xerosis, Bacillus, 29, 195
  agglutination 33
Xerosis, Bacillus, in chalazion, 66, 199
  on the conjunctiva, 29
    of animals, 33
  in conjunctivitis of measles, 251
  in corneal ulcers, 301
  in dacryocystitis, 279, 281
  historical, 29
  immunizing with, 198
  on the lids, 54
  method of spread, 33
  Neisser's polar staining, 32, 194
  in normal ext. audit. meatus, 54
  in Parinaud's conjunctivitis, 250
  pathogenicity of, 196
  relation to Löffler's bacillus, 31
  in scrofulous inflammations, 253
  symbiosis, 43, 44
  toxin formation, 197
  in trachoma, 265
  in trachomatous ulceration, 312
  vitreous inoculation, 200

Z

Ziehl's solution, 15, 16
  stain, 11
Zinc treatment, 161, 167, 173, 300

Baillière, Tindall and Cox, 8, Henrietta Street, Covent Garden, London

APPENDIX I.

DIFFERENTIAL DIAGNOSIS OF THE COMMON ORGANISMS OCCURRING IN THE EYE.

						PAGE
The organism is a bacillus	Gram-negative	Do not liquefy blood serum	Hæmophile growing only on hæmoglobin media	Grows on serum agar ...	*B. Koch-Weeks*	133
				Grows on blood agar ...	*B. influenzæ*	
			Will grow on simple agar	Has capsules	*B. pneumoniæ* (Friedländer)	241
				No capsules — Non-motile ...	*B. Zur Nedden*	321
				No capsules — Motile ...	*B. coli communis*	240
		Liquefy blood serum	Liquefied serum brownish, and contains large *Diplobacilli*	Does not grow on agar ...	*Diplobacillus* (Morax-Axenfeld)	157
				Grows on agar	*Diplobacillus* (Petit)	167
			Serum fluorescent, and contains small bacilli		*B. pyocyaneus*	310
	Gram-positive septate	Do not liquefy blood serum	Pathogenic		*B. diphtheriæ* (Löffler)	190
			Non-pathogenic		*B. pseudo-diphtheriæ*	193
					B. xerosis	29
	non-septate	Liquefy blood serum	The subtilis group: *B. subtilis*, *B. mycoides*, *B. megatherium*, *B. vulgatus*, *B. mesentericus*			88

The organism is a coccus

Gram-positive	Do not liquefy blood serum	Does not grow at room-temperature, nor liquefy gelatine		*B. tuberculosis*	346
		Grows at room-temperature, and liquefies gelatine ...		*Actinomycosis bovis s. hominis*	285
Gram-negative	Scanty growth on serum media			*Gonococcus* (Neisser)	212
	Free growth			*Meningococcus* *Micrococcus catarrhalis* *Sarcinæ*	214
Gram-positive	Growth in chains	With capsules; lancet-shaped pairs		*Pneumococcus*	183
		No capsules; in chains		*Streptococcus pyogenes*	206
	Growth in clusters	Does not liquefy gelatine	White	*Staphylococcus albus non-liquefaciens (candicans)*	34
		Does liquefy gelatine	Orange yellow	*Staphylococcus aureus*	37
			White	*Staphylococcus albus*	33
			Lemon yellow	*Staphylococcus citreus*	39

APPENDIX II.

PLATE I.—CONJUNCTIVAL SECRETIONS.

Gram's Stain.

Fig. I.—Koch-Weeks Bacilli (from an acute catarrh). Very slender rods, which are of varying length and are Gram-negative (stained red). A few Gram-positive (blue) xerose bacilli are also present.

Fig. II.—Bacillus Influenzæ (L. Müller's bacillus) (from a catarrhal conjunctivitis). Very short Gram-negative rods, which often resemble elongated *Diplococci*, and are shorter than the Koch-Weeks bacillus.

In I.*a* they are mixed with Koch-Weeks bacilli; in II.*b* they are pure. II.*c* and II.*d* are pure cultures on blood-agar (in II.*c* pigeon's nucleated blood-corpuscles are seen). In II.*c* there are only the short forms; in II.*d* there are the longer ones.

Fig. III.—Morax-Axenfeld Bacillus (from a case of angular blepharo-conjunctivitis). Large Gram-negative *Diplobacilli*, some arranged in short chains. No definite capsules.

Fig. IV.—Friedländer's Pneumobacillus (from a dacryocystitis case). Gram-negative bacilli, either single or in pairs; sometimes in chains, the double form being not nearly so regular as in the case of the *Diplobacilli*. The capsules are also much more apparent, and in places—as, for instance, in IV.*b*, where the preparation is overstained—they stain light red, and are surrounded by a clear space. In the middle of IV.*b* the capsules are overstained, and resemble very large bacilli. (Preparation by Dr. Zur Nedden.)

Fig. V.—Bacterium Coli (from a case of blennorrhœa neonatorum). Gram-negative bacilli of varying shape and size. Quite short, and also long, bacilli are to be seen alongside of occasional double forms.

Fig. VI.—Löffler's Bacillus Diphtheriæ (from a case of pseudo-membranous conjunctivitis). Gram-positive bacilli, which are often curved and have thickened ends.

(*a*) Short forms predominate. There are also some short chains, indicating a mixed infection with *Streptococcus pyogenes*.

(*b*) Long slender forms, some with polar staining; also a few *Diplobacilli*.

Plate I.

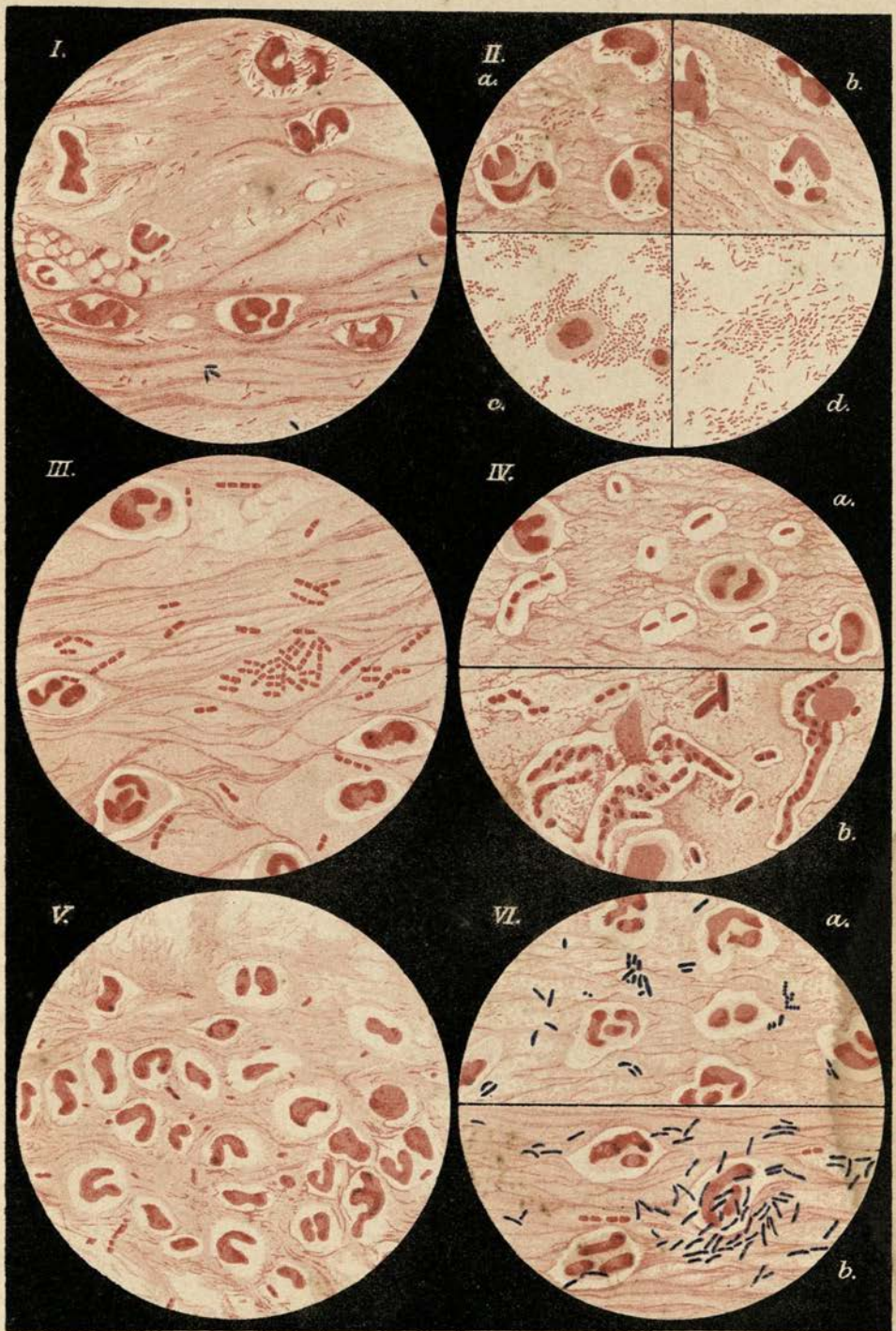

Th. Johnsen gez.

Lith. Anst. v. K. Wesser, Jena.

Conjunctival Secretions (Gram stained).

I. Koch-Weeks Bacilli and Xerose Bacilli. *II.* Influenza Bacilli.
III. Morax-Axenfeld Bacilli. *IV.* Friedländers Pneumobacilli. *V.* Bacterium Coli.
VI. Bacillus Diphtheriae; *(a)* short forms, with Streptococci; *(b)* longer, with Diplobacilli.

PLATE II.—CONJUNCTIVAL SECRETIONS.

GRAM'S STAIN.

FIG. I.—GONOCOCCI (from a blennorrhœa neonatorum). Gram-negative (red) kidney-shaped *Diplococci*, tending to lie in the cells.

FIG. II.—PNEUMOCOCCAL CONJUNCTIVITIS (from an acute catarrh). Gram-positive (blue) *Diplococci*, the most of which are elongated, some being lancet-shaped, and a few rounded. The capsules are not readily seen in this stain.

FIG. III.—OTHER GRAM-NEGATIVE (red) DIPLOCOCCI (*Pseudo-gonococci*) (from slight cases of chronic conjunctivitis). III.*a*, III.*c*, III.*d*, MICROCOCCUS CATARRHALIS (III.*c*, pure culture); III.*b*, GRAM NEGATIVE SARCINÆ.

The *Diplococci* are mostly larger, but some are similar to *Gonococci*.

FIG. IV.—STREPTOCOCCAL CONJUNCTIVITIS (from a case of pseudo-membranous conjunctivitis). Gram-positive (blue) round cocci, in some cases showing chains, but also in the double form.

FIGS. V. AND VI.—STAPHYLOCOCCI. Gram-positive (blue) cocci.

V.*a*. In pus from a hordeolum. Clusters.

V.*b*. Large *Diplococci* and tetrads, resembling *Sarcinæ*; also xerose bacilli from a slight chronic conjunctivitis.

VI.*a*. Pus from the vitreous in a case of suppuration after cataract operation. Irregular clusters of *Staphylococci*. The cocci vary in size.

VI.*b*. Masses of *Staphylococci* in the secretion of a post-operative conjunctivitis. Double forms predominant; many showing coffee-bean shape and being intracellular (Gram-positive *Pseudo-gonococci*).

Plate II.

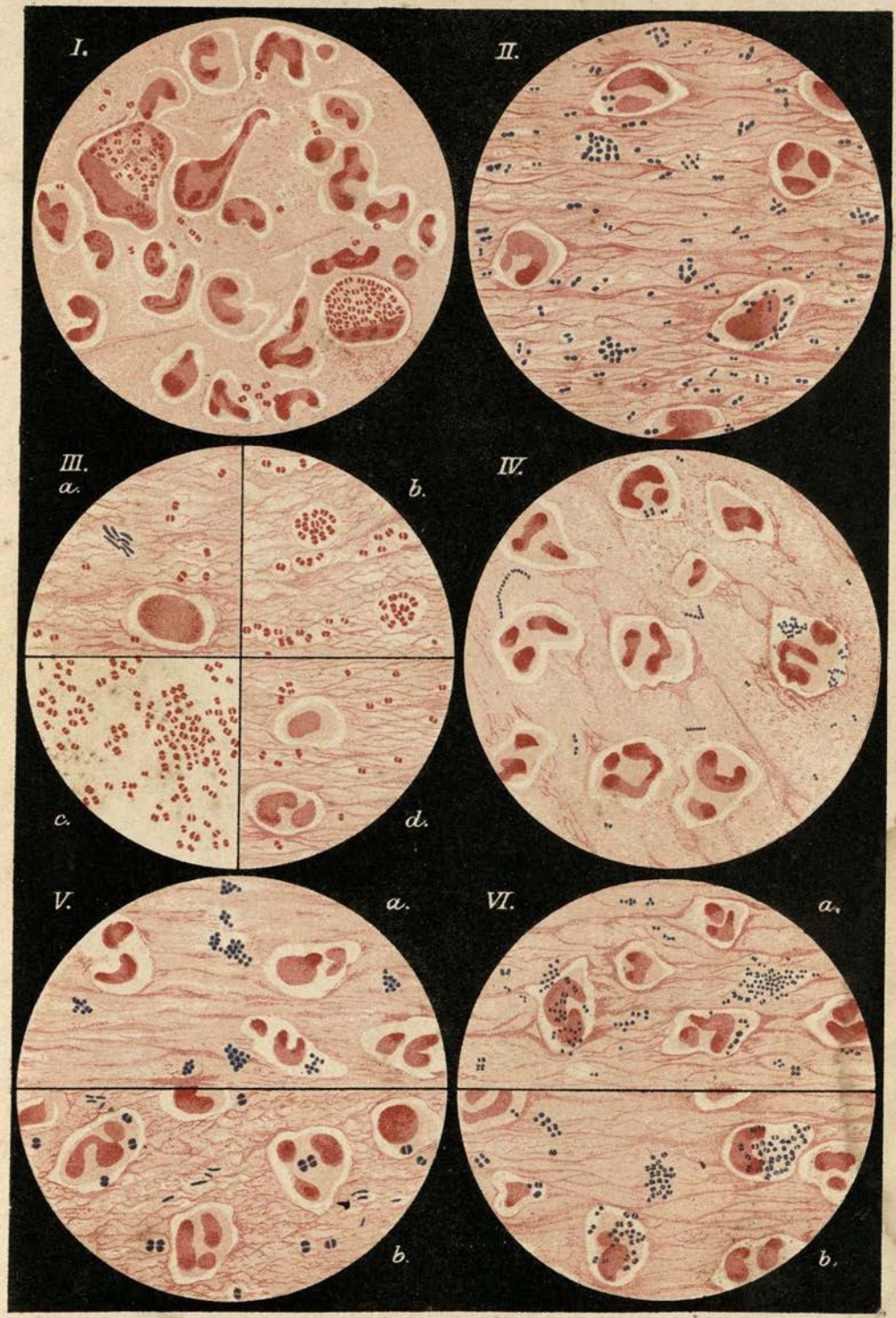

Th. Johnsen gez.

Lith. Anst. v. K. Wesser, Jena.

Conjunctival Secretions (Gram stained).

I. Gonococci. *II.* Pneumococci. *III.* "Pseudogonococci (Sarcinae Micr. catarrhalis)". *IV.* Streptococci. *V.* and *VI.* Staphylococci; *Vb.* Sarcinae with Xerose Bacilli.

PLATE III.—EXUDATIONS FROM THE CORNEA.

GRAM'S STAIN.

Figs. I. to IV.—Corneal Exudations.

FIG. I.—Smear from an ulcus serpens with PNEUMOCOCCI. Gram-positive (blue) *Diplococci*, generally elongated, some having capsules.

FIG. II.—Smear from a hypopyon-keratitis with DIPLOBACILLI (Petit). Morphologically resembling the Morax-Axenfeld variety. II.*b* is from an agar culture. Gram-negative (red) bacilli in pairs.

FIG. III.—ZUR NEDDEN'S BACILLUS of infectious marginal ulcer (preparation by Dr. Zur Nedden). Gram-negative (red) bacilli varying in size, many being curved.

FIG. IV.—BACILLUS PYOCYANEUS from a severe case of hypopyon-keratitis. Small Gram-negative (red) bacilli; small, and often arranged in pairs. IV.*b*, pure culture.

Figs. V. and VI.—Vitreous Pus.

FIG. V.—Anaerobic BACILLUS PERFRINGENS from traumatic panophthalmitis (by Dr. Chaillous). Gram-positive (blue) bacilli, with the staining interrupted at places.

FIG. VI.—BACILLUS SUBTILIS from a panophthalmitis, due to a splinter wound. Large Gram-positive (blue) bacilli, sometimes forming elongated bands which are not equally stained, and cannot be distinguished from the *B. perfringens* by their shape alone.

Plate III.

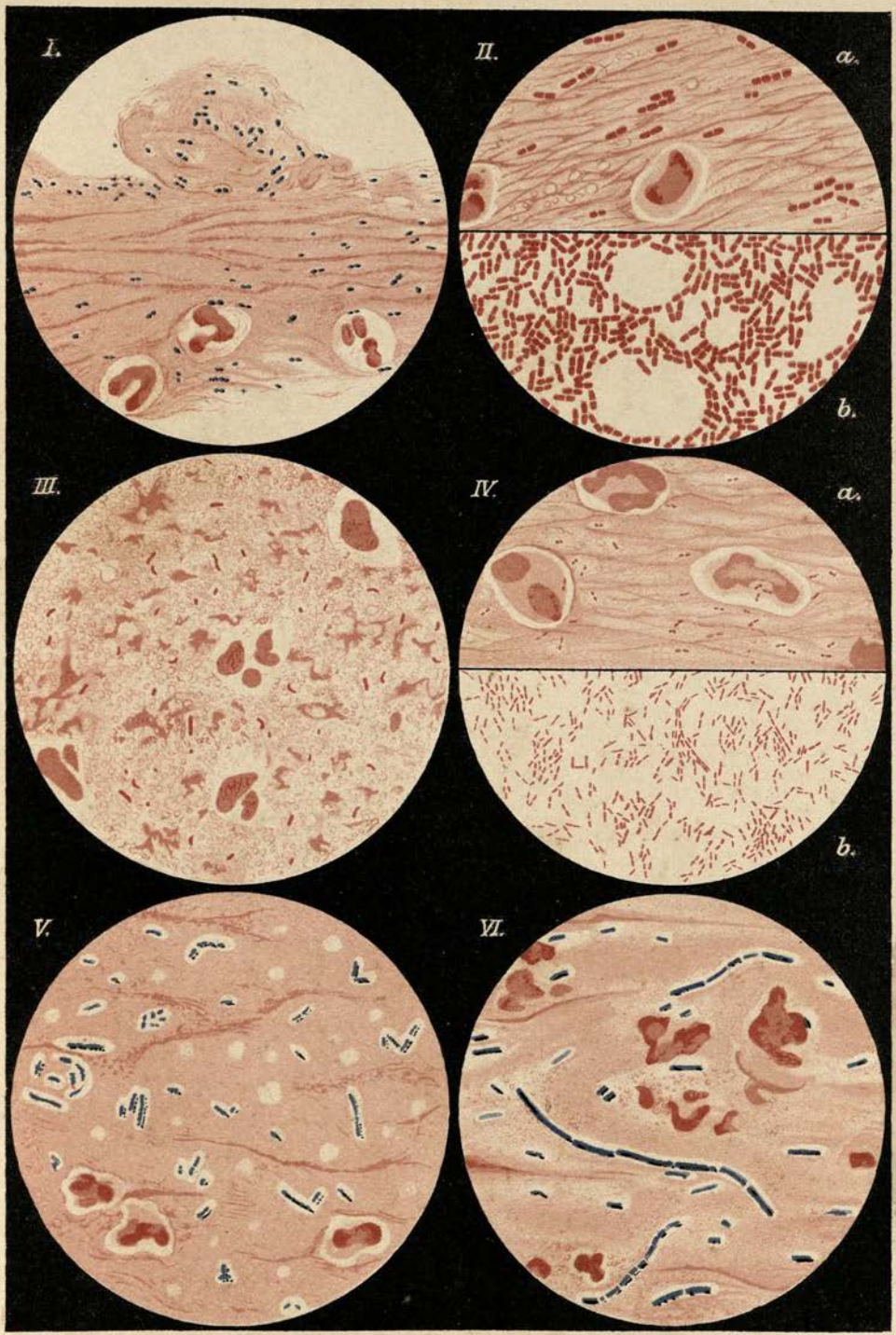

Th. Johnsen gez. Lith. Anst. v. K. Wessar, Jena.

Exudations from the Cornea (Gram stained).

I. Pneumococci from an Ulcus serpens. *II.* Diplobacillary-Keratitis; *b.* Culture. *III.* zur Neddens Bacillus. *IV.* B. pyocyaneus; *b.* Culture.

Vitreous Suppurations in traumatic Panophthalmitis.

V. B. perfringens (Chaillous). *VI.* B. subtilis.

00013734

Digitized with financial assistance from

on 10 July, 2018